



## A Comparative Study between Two Orthopedic Implants in Dogs

Bouknine Asma<sup>1</sup>, Boudra abdellatif<sup>1</sup>, Hamdi Mohamed<sup>1</sup>, Hamri mokhtar<sup>1</sup>, Rezki hamza<sup>1</sup>, Bouhentala Salaheddine<sup>2</sup>

<sup>1</sup>*Institute of Veterinary Science, University of Tيارet, Algeria*

<sup>2</sup>*Department of Veterinary, Institute of Veterinary and Agricultural Sciences, University of Batna, Algeria*

Corresponding author's email: [asmabouknine@gmail.com](mailto:asmabouknine@gmail.com)

### ABSTRACT

Femoral fracture occupy is important place in canine veterinary orthopedic, this work which interesting for technical aspects of implants, bone healing and the functional quality obtained. The eight male dogs, subjected to a transverse osteotomy at the left femoral diaphysis and divided into two groups, the first is fixed by intramedullary pinning and the second by ordinary bone plate. We observed that the intramedullary pinning is the a most secure method, with fewer complications, and consolidation type second intention, while the fixation by bone plating is less secured, with a lot complications, and consolidation with periosteal callus formation. Of the end of our study we conclude that the intramedullary pinning is a method of choice for treat diaphyseal transversal fracture by providing an economic method, easy to apply and good stability compared with ordinary plate fixation.

**Keywords:** Femur, Intramedullary Pinning, Bone Plating, Dogs.

### INTRODUCTION

Femur fractures commonly occur in dogs following different kind of trauma. The goal of fracture repair is to establish rigid fixation and perfect alignment of the bone to allow both timely and maximized return to function of the affected area. In the small animal internal fracture fixation, many improvements have been developed, including improved fixation techniques and a more diverse selection of implants. Femur fractures are generally not amenable to conservative repair, and some kind of internal fixation is generally required (Beale, 2004). Intramedullary pinning (IMP) is the most readily used system of internal fixation in small animals (Muir et al., 1993). Open reduction and internal fixation using appropriate implants with minimal disruption to vascularity and soft tissue components is the goal of biological osteosynthesis (Gaeber et al., 2011).

It is important to choose an implant system that is capable of adequately neutralizing all the disruptive forces (bending, compressive, or torsional stresses) at the fracture site and allowing bone healing to rapidly progress (Perren, 2002). Important factors in repair of femur fracture include, appropriate surgical approach, preservation of regional soft tissues and their attachments to bone fragments, either anatomic or indirect reduction, adequate stabilization, appropriate choice and application of implant system and proper postoperative care (Stiffler, 2004).

### MATERIALS AND METHODS

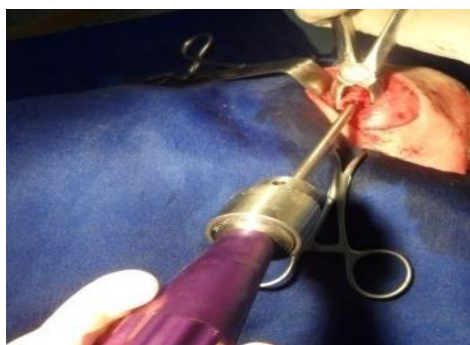
This study was carried out on 8 healthy adult male dogs, respecting the criteria of animal bioethics (no suffering and pain ...). All dogs were kept under the same management and nutritional regimens during the experiment. Food was withheld 7hrs before the operation. Fractured bones induced were fixed by two different fixation techniques. The operated animals were classified into two groups according to the method of fixation.

- Group I (4 dogs): The femur bones were fixed with single intramedullary pins + hemicerclage wire.
- Group II (4 dogs): The femur bones were fixed with ordinary bone plates and screws.

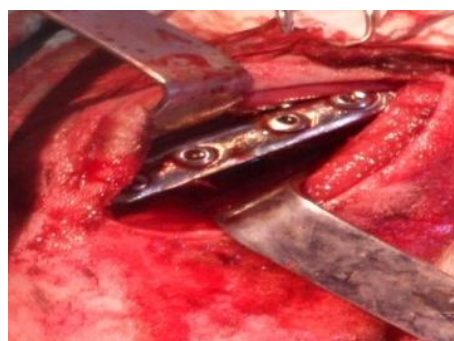#### The surgical operation:

The left hind limb of each dog was prepared for aseptic surgery. All dogs were operated under the effect of general anesthesia. Each dog was premedicated with I/M injection of chlorpromazine hydrochloride in a dose of 1mg/kg. Intravenous injection of atropine sulphate (0.04 mg/kg body weight); buprenorphine IM injection (0.02 mg/kg body weight), and then general anesthesia was conducted by I/V injection of tilitamine -zolazepam (5mg/kg body weight); until the main reflexes were disappeared and the depth anesthetic was maintained with intravenous injection of half of dose of induction bolus.

To examine optimum healing, all dogs were subjected to routine clinical and radiographic evaluation. In shape skin incision was made over the cranial border of the femur bone from the subtrochantric area to the femoral condyles. Separation between the biceps femoris muscle caudally and the vastuslateralis was done to expose the femoral diaphysis. A transverse mid-shaft osteotomy was made using an oscillating saw; then the experimentally induced fracture was reduced anatomically using each previously mentioned fixation. For the first group by setting the pin by retrograde method (Fig. 1). After having realized a hemicerclage wire, for a second group attachment of plate in the lateral surface of the femur (Fig. 2).



**Fig. 1:** Pin retrograde insertion



**Fig. 2:** Plate insertion in the lateral face of femur

### Post operator care

Just after the operation, injecting an antibiotic pénistreptomycine during 10 days, the wound is cleaned daily by antiseptic solution; zinc oxide is applied to the wound to accelerate the period of healing. Clinical examination Dogs were clinically observed daily during the study period for recording any postoperative complications. For assessing functional disorders of the affected limb during walking, the animals are examined during the seven days following the operation, and a clinical examination is oriented mainly on taking body temperature, auscultation of heart and respiratory movements.

### Radiographic examination

A radiograph is made room immediately after surgery to enjoy a good quality of osteotomy, the correct position of the implants and the absence of intraoperative fractures. To assess the degree of bone healing, radiographs were taken at 1, 2, 3, 4, 5, 6 weeks postoperatively until bone healing.

## RESULTS

Osteosynthesis performed under general anesthesia effect, allowed a sufficient operating time for the installation of two types of fixation; muscle relaxation and analgesia showed no failure throughout the procedure. However, the application of a bone plate took longer operative time than an intramedullary pinning. The average time for setting up a bone plating and intramedullary pinning fixation respectively is 1h 30 min and 45 min.

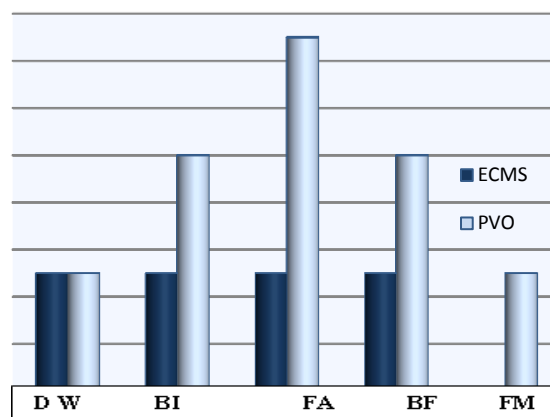
One dog treated with the bone plating has presented two major intraoperative complications, which are muscle damage and embrittlement bone during screwing. For the remaining animals, the sequence of interventions revealed no complications, and the awakening took place peacefully. During the post-operative follow, we found the presence of oedema at the operative site in all animals, and more significantly in patients treated with bone plate group, its disappearance was observed after one week. Neurological examination after surgery confirmed the absence of injury to the sciatic and femoral nerve in all animals. From a functional point of view, recovery and return to function of dogs treated with intramedullary pinning took place gradually; in contrast, the group treated with bone plating was very early but did not last long because the failure of the osteosynthesis material used (Fig. 3).

For the group treated by intamedullary pinning, all animals showed progressively dense periosteal reaction at the 2<sup>th</sup> week. At the 6<sup>th</sup> week, the periosteal reactions were getting denser in animals of group I, with the beginning of periosteal callus bridging formation from the third week, of full training callus generally after one month follow up. It was the beginning of callus formation but infection has hampered bone consolidation in one dog. For the group treated by bone plate was noticed the presence of periosteal reaction from second week, an early callus formation from the third week and clarity sign osteolysis (Table1).

**Table 1.** Type and duration of callus formation

	S 1	S 2	S 3	S 4	S 5	+S 6
<b>Dog1</b>	+P+	+P+	++P++	+++P++	+++P+++	+++P+++
<b>Dog2</b>	N	+P+	++P++	++P++	++P++	/
<b>Dog3</b>	+ P+	+P+	++P++	++P++	+++P+++	+++P+++
<b>Dog4</b>	+ P+	+P++	++P++	++P++	+++P++	+++P+++
<b>Dog5</b>	P+	/	/	/	/	/
<b>Dog6</b>	N		P+	P++	P+++	P++ +
<b>Dog7</b>	P+	P++	P++	P+++	/	I
<b>Dog8</b>	/	P+	P+++	/	/	/

+P+: Periosteal reaction in two faces; ++P++ :Begining of callus bridg. ++P++: Begining of callus bridg with osteolysis. +++P+++: Callus bridg in two faces. N: absence on any reaction.



**Fig. 3.** Complications of two groups.

(DW: Dehiscence of wound. BI: Bone Infection. FA: Femur angulation. BF: Bone Fragilisation. FM: failure of the osteosynthesis material.)

## DISCUSSION

Our study shows the effectiveness of the fixation intramedullary pinning compared to the bone plate. With functional improvement, increased consolidation ratio and mechanical solidarity in the use of intramedullary pinning. In a studies by Elhusseini et al. (2012) argue that the intramedullary pinning provides excellent stability for long bones, so it offers a good biomechanical environment for fracture healing. The results of present study showed early support and functional recovery of the member in the group treated with bone plating. This indicated that early support found in dogs treated with bone plate is due to the excellent stability provided by a plate at baseline, bone resist this time to disruptive forces until a callus formation, allowing early use of joints and muscles. Ordinary plate does not provide a good asset, so the relative instability of the assembly causes the formation of a significant periosteal callus. Thus, if a periosteal callus does not come quickly alleviate some implants, the risk of rupture, tear or debricolage be major (Milton, 1993)

The failures of the plate either debricolage or loosening screws represent the bulk of complications encountered in patients treated with bone plate group. Similar results were cited by Jackson and Pacchiana (2004), Talib (2013) and Könning et al. (2013). Radiographic follow-up of treated bone plate group revealed the presence of a large callus extending from both epiphyseal line of fracture.

The development of a new plate called Dynamic Compression Plate (DCP), the slotted holes allow, through an eccentric screw, progressive and lasting compression of the fracture. However, this perfect rigidity slows healing by removing restrictions supported by tissue formation (Baron, 2010).

Intramedullary pinning favors charging member, and allows by law of Wolff accelerate callus strength and prevents muscle atrophy and joint ankylosis (Mills and Jackson, 2003).

The migration of the pin before full consolidation showed an angulation of the bone in the dog. This complication is the essential defect of intramedullary pinning recorded during our study. According to Fossum (2007), micromotion of the pin, caused by inequality between the diameter of the pin and the medullary canal, are responsible for the migration of a pin. This has necessitated the use of a complementary fastener as hemicerclage wire to increase the rotational and axial strength. The realization of the osteosynthesis plate screwed damaged muscle insertions, the achievement of one of the sources of osteogenesis was delayed, thus depriving the bone of a large mechanical support, and adding to this fragility and occurrence of cracks in the bone caused by the bone lesions generated by the screwing. The realization of a mounting plate screwed causes more trauma to the surrounding soft tissues as bone intramedullary pinning. The need to ensure the rigidity of the plate requires at least 4 bicortical screws are engaged in two bony segments (Könning et al., 2013). Indeed, the plate installation often requires the release of a space on the cortical. This maneuver is performed after dissection and greater exposure of soft tissues. The damage to the periosteal blood supply is considerable and often hinder the formation of periosteal callus (Baron, 2010). Unlike the installation of the plate, the insertion of intramedullary pinning does not damage the periosteal blood supply and the operating time is reduced by half (Daglar and al., 2007). Most complications recorded in both assemblies have in common the presence of infection, this results in a diffused clarity on the radiography, causing migration of the pin.

## CONCLUSION

It concluded that fixation femoral fractures with intramedullary pinning is an economical and efficient method and provides good stability with minimal complications while the application of ordinary bone plate is more traumatic, provides poor stability with significant complications.

## REFERENCES

- Baron M (2010). Ostéosynthèse chez les petits animaux, évolution des concepts, communication, pp. 351-353.  
 Beale B (2004). Orthopedic clinical techniques femur fracture repair. *ClinTech Small AnimPract.*, 19(3):134-150.

- Daglar B, Delialioglu OM, Tasbas BA, Bayrakci K, Agar M and Gunel U (2007). Comparison of plate-screw fixation and intramedullary fixation with inflatable nails in the treatment of acute humeral shaft fractures. *Acta Orthop Traumatol Turc.*, 41(1): 7-14.
- Elhusseiny NI, Mostafa MB, Elhabak AM and Harb HF (2012). Biomechanical Studies on Femoral Fracture Repair Fixed By Different Fixation Methods in Dogs. *Journal of American Science*, 8(1): 216-222.
- Fossum T W (2007). Small animal surgery. (3<sup>rd</sup> ed Mosby, Elsevier). pp. 935-1005.
- Gaeber C, McQueen MM and Vecsei V (2011). Reamed versus minimally reamed nailing: A prospectively randomized study of 100 patients with closed fractures of the tibia. *Injury*, 42: 17-21.
- Jackson LC and Pacchiana PD (2004). Common complications of fracture Repair, *Clin Tech Small Anim Pract.*, 19:168-179.
- Könning T, Maarschalkerweerd R J and Endenburg N (2013). A comparison between fixation methods of femoral diaphyseal fractures in cats - a retrospective study, *Small Animal Practice J.*, 54(5): 248-252.
- Mills DL. and Jackson AM (2003). Delayed unions, nonunions, and malunions. In Textbook of small animal surgery. (3<sup>rd</sup> ed, Philadelphia: Saunders). pp.1849-1861.
- Milton JL (1993). Fracture of the femur. In Textbook of small animal surgery, (2<sup>nd</sup> ed. Philadelphia: W.B. Saunders company). Vol. 2. pp. 1805-1817.
- Muir P, Parker RB., Goldsmid S E, and Jonhson KA (1993). Interlocking intramedullary nail stabilization of a diaphyseal tibial fracture. *J. Small Anim. Prac.*, 34 : 26-30.
- Perren SM (2002). Evolution of the internal fixation of long bone fractures- the scientific basis of internal fixation: choosing a new balance between stability and biology. *J Bone Joint Sur.*, 84:1093-2110.
- Stiffler KS (2004). Internal fracture fixation, *Clin Tech Small Anim Pra.*, 19 (3): 105-13.
- Talib AA (2013). Implants failure in orthopedic surgery. *Kut Bas J Surg.*, March : 68-73.