



Treatment Effects of Chitosan Nanoencapsulated Bromelain against Gastrointestinal Nematodes and Coccidia in Goats of Kenya

Ahmota Romain Daiba^{1,6} , John Maina Kagira^{2*} , Maina Ngotho³ , James Kimotho⁴ , and Naomi Maina^{1,5} 

¹Department of Molecular Biology and Biotechnology, Pan-African University of Institute of Basic Science, Technology and Innovation, Nairobi, Kenya

²Department of Animal Sciences, Jomo Kenyatta University of Agriculture and Technology, Nairobi, Kenya

³Department of Clinical Studies, Faculty of Veterinary Medicine, University of Nairobi, Nairobi, Kenya

⁴Innovation and Technology Transfer Division, Kenya Medical Research Institute, Nairobi, Kenya

⁵Department of Biochemistry, Jomo Kenyatta University of Agriculture and Technology, Nairobi, Kenya

⁶Department of Livestock Science and Technology, National Higher Institute of Science and Techniques of Abeche, Chad

*Corresponding author's Email: jkagira@jkuat.ac.ke

ABSTRACT

The management of gastrointestinal nematodes (GIN) and coccidiosis of livestock relies on the use of commercial anthelmintic; however, the excessive and frequent usage of these drugs has led to the substantial and dramatic development of anthelmintic and anticoccidial resistance. The present study aimed to evaluate the anthelmintic and anticoccidial efficacy of chitosan nanoencapsulated bromelain (CNB) against a wide spectrum of GIN and coccidia in goats. Additionally, the study assessed the safety of CNB in the goats. Bromelain was extracted from the pineapple peels and then encapsulated using chitosan. A total of 20 healthy male goats naturally infected with GIN and coccidia were used. The goats were separated into four treatment groups, with five goats per each. The CNB was orally administered at dosages of 270 and 90 mg/Kg, once daily for 60 days. Fecal egg counts (FEC), fecal oocyst counts (FOC), packed cell volume (PCV), aspartate aminotransferases (AST), alanine aminotransferases (ALT), urea, and creatinine were determined weekly. The goats were monitored for clinical signs daily, and their body weight was recorded weekly. The findings revealed that FEC reduction rates in the group that received 270 mg/Kg CNB and the group that received Albendazole were 73.41% and 79.54% at day 7 post-treatment. Also, the reduction of FOC in the group receiving 270 mg/Kg CNB at day 7 (84.12%) did not show a significant difference with Diclazuril (82.12%). The FEC and FOC were zero (reduction of FEC and FOC was 100%) at 28 days of treatment in goats treated with 270 mg/Kg CNB. During the monitoring period, no mortalities and no clinical signs were observed in the treated goats. The PCV, AST, ALT, creatinine, and urea levels for the goats in all groups were within normal limits. No pathological lesions were observed in the goat's organs. In conclusion, the results demonstrated that repeated (60 days) dosages of 270 mg/Kg had anthelmintic and anticoccidial effects and were safe for goats. The study recommends further investigation in a field setting involving more animals. This would allow the development of a novel product for managing helminthiasis and coccidiosis in ruminants.

Keywords: Anthelmintic, Anticoccidial efficacy, Bromelain, Chitosan, Encapsulation, Goat

INTRODUCTION

Endoparasites such as gastrointestinal nematodes (GIN) and coccidia are a serious health concern in small ruminants across the world (Jansen et al., 2020; Wasso et al., 2020; Wondimu and Bayu, 2022). In many tropical countries, the main GIN affecting small ruminants is *Hemonchus contortus*, *Oesophagostomum* spp., *Trichostrongylus* spp., *Ostertagia* spp., *Nematodirus* spp., and *Cooperia* spp. (Maichomo et al., 2004; Waruru et al., 2005). These parasites cause a decline in milk and meat production resulting in severe economic losses in the livestock industry (Waruru et al., 2005; Ibrahim et al., 2014; Mat Yusof and Md Isa, 2016). On the other hand, coccidiosis is caused by protozoan parasites of the genus *Eimeria* with the main one being *Eimeria ninakohlyakimovae*, *E. hirci*, *E. caprina*, *E. christenseni*, *E. jolchijevi*, *E. apsheronica*, and *E. arloingi* (Etsay et al., 2020). These parasites contribute to enteric disease, particularly in young or stressed livestock leading to low production and high mortality (Faizal and Rajapakse, 2001; Mohamaden et al., 2018; Etsay et al., 2020). In most of the ruminants' production systems, GIN and *Coccidia* manifest as mixed or singles infections which compound the morbidity and mortality cases (Faizal and Rajapakse, 2001; Jansen et al., 2020; Bawm and Htun, 2021). In Kenya, the prevalence of gastrointestinal tract parasites in small ruminants is high, with the prevalence of up to 82% and 85% for GIN and coccidiosis, respectively (Maingi and Munyua, 1994; Waruru et al., 2005; Kanyari et al., 2009).

The management of GIN and coccidiosis of livestock relies heavily on the use of commercial anthelmintic and anticoccidial drugs (Kaplan, 2004; Noack et al., 2019). However, the excessive and frequent usage of these drugs has led to the substantial and dramatic development of anthelmintic and anticoccidial resistance to GIN and coccidia, principally in cattle, sheep, and goats (Hema et al., 2015; Mickiewicz et al., 2021; Potârniche et al., 2021). Regarding the growing threat to animal health and production posed by drug resistance, innovative medications, including those based on plant extracts need to be considered and developed as potentially sustainable alternatives (Sadr et al., 2022).

One of the potential anthelmintic and anticoccidial plants is pineapple (*Ananas comosus*), containing cysteine proteinases enzyme (Misran et al., 2019). The pineapple enzyme, bromelain, has been demonstrated to have anthelmintic and anticoccidial activities *in vitro* and *in vivo* levels (Githiori, 2004; Hunduza et al., 2020; Wasso et al., 2020; Daiba et al., 2022). The recent *in vitro* and *in vivo* studies by Wasso et al. (2020) and Daiba et al. (2022) called for the investigation of the efficacy of nanoencapsulated bromelain at enhanced and repeated doses. The study by Wasso et al. (2020) reported that nano-encapsulated bromelain caused an efficacy of up to 68.8% at 30 mg/Kg for 14 days of treatment. The aim of the current study was to use higher doses of nano-encapsulated bromelain to investigate the *in vivo* efficacy and toxicity of encapsulated bromelain in chitosan against GIN and coccidia in goats.

MATERIALS AND METHODS

Ethical approval

The approval for the goats' experiments was obtained from the Animal Ethics Committee of the University of Nairobi, Kenya (REF: FVM BAUEC/2020/339). The study followed the design, animal husbandry practices, and protocols approved by the Committee.

Experimental site

This controlled laboratory study was carried out between July 2021 and January 2022, at the animal facility located at Jomo Kenyatta University of Agriculture and Technology (JKUAT), Juja Campus, located just outside Kenya's capital city of Nairobi. The University is located at latitude 1°05 S and longitude 37°00 E, and it lies at an altitude of 1525 m above sea level with rainfall bimodal and ranges from 500 mm - 1300 mm while the average temperature is 19.5°C (Menge et al., 2014).

Extraction and encapsulation of bromelain in chitosan

The University Campus falls within the agricultural zone, where commercial pineapple cultivation forms a substantial part of agricultural activities. Pineapples were readily available at the local market. Bromelain was extracted from the peels of pineapples (*Ananas comosus*) sold at a local market in Juja sub-county, Kiambu County, Kenya. The bromelain was extracted using the procedure described previously by Hunduza et al. (2020). Fresh ripe pineapples were ground in a blender in sodium acetate buffer (pH = 7.4). The resultant crude extract was precipitated by adding 40% ammonium sulfate. After 24h of incubation at 4°C, extracted bromelain was purified using a dialysis membrane (size of 12 kDa). Bromelain in chitosan (Sigma Aldrich, USA) was encapsulated by the ionic gelation method (Hunduza et al., 2020). The pellet obtained after encapsulation was dried by placing it in the freeze-dryer (MRC, Model FDL-10N-50-BA, Israel) after frozen at -60°C. The Fourier transform infrared spectrophotometer analysis (FTIR) was used to confirm the success of the encapsulation of bromelain in chitosan nanoparticles (Hunduza et al., (2020).

Experimental animals

Twenty small East African male goats, which were naturally infected with GIN and coccidia, were purchased from farmers (before purchase, fecal samples were collected to diagnose positive animals for both GIN and coccidia infection) in Makima Ward in Embu County in Northeastern Kenya. Molecular identification by PCR showed that animals were infected by a wide number of nematodes (*Haemonchus contortus*, *Trichostrongylus vitrinus*, *Trichostrongylus axei*, *Trichostrongylus colubriformis*, *Nematodirus filicollis*, *Oesophagostomum* spp., and *Ostertagia ostertagi*). The average age of the goats was 15 months old, and they weighed between 22-31 Kg. Acclimatization to the diet was done for 2 weeks, and animals were tagged with ear tags for easy identification before the start of the experiment. The goats were group-housed at the JKUAT animal facility. The animals were kept in pens of 3 m x 3 m size and were fed with 1.5 Kg of wheat hay thrice per day, 1 Kg/animal of feed concentrate made up of beet liquid molasses, maize germ, and soybean meal (Aroma Feed Suppliers®, Kenya). The animals had access to essential minerals lick blocks (Aroma Feed Suppliers®, Kenya) and fresh drinking water *ad libitum*.

Treatment groups and sampling

Fresh fecal samples (10 grams) were collected using sterile gloves from the rectum of goats. These were analyzed to determine the number of eggs per gram (EPG) and coccidia oocysts per gram (OPG) of feces using the McMaster method (Cringoli et al., 2004). The animals formed self-control samples taken at the start of the study. All the animals

used in the experiments had an EPG and OPG of more than 2,000 and 10,000, respectively. The goats were divided into four treatment groups of five goats. Groups 1 and 2 received 90 mg/Kg and 270 mg/Kg of CNB, respectively, while group 3 was considered as the positive control where goats were administered orally with 7.5 mg/Kg of Albendazole (Sigma Aldrich, USA) and 5 mg/kg of Diclazuril (Sigma Aldrich, USA), and group 4 was served as negative control (untreated goats). The above dosages were chosen based on the results of the bromelain toxicity and efficacy tests obtained in the previous studies (Wasso et al., 2020; Daiba et al., 2022). The treatment was done orally every morning for 60 days. The animals were monitored for 90 days after the last day of drug administration.

***In vivo* assessment of anticoccidial efficacy**

Fecal samples were collected from the rectum of goats every 7 days after the start of drug administration up to the end of the monitoring period (150 days). The fecal samples were analyzed using a modified McMaster technique to determine the EPG and OPG (Coles et al., 1992; Odden et al., 2018). Fecal egg count reduction (FECR) and fecal oocyst count reduction (FOCR) percentages were evaluated as previously described by Coles et al. (1992) and Odden et al. (2018).

Assessment of toxicity effect

Following dosing, the animals were observed for acute toxicity during the first 30 minutes and then every 6 hours during the first 24 hours. Thereafter, the animals were monitored for any changes in general behavior, clinical and other physiological activities (OECD, 2002; Parasuraman, 2011). Rectal temperature of goats was measured daily, each morning (8 a.m. to 9:30 a.m.) coinciding with the time of drug administration) using a digital thermometer (Kruuse Digital Thermometer; Jorgen Kruuse). The body weight of animals was recorded weekly using a 100 Kg spring balance scale (Salter Model, Capital Scales - Pretoria, South Africa). Two mL of blood was sampled weekly from each animal from the jugular vein into a blood collection tube with 4 mL EDTA. The PCV was determined using the micro-hematocrit method (Shamaki et al., 2017). The plasma samples obtained were used to determine the levels of Aspartate aminotransferases (AST), Alanine aminotransferases (ALT), urea, and creatinine using standard diagnostic test kits on an Automated Clinical Biochemistry analyzer (Reflotron Plus System®, model: Cobas 4800 Detection Analyzer; India, Emma et al., 2020; Wasso et al., 2020).

Following the last day of drug administration, the goats (2 goats per group on day 60 and the rest on day 150) were sacrificed using 0.25 mL/Kg of Pentobarbital sodium (Leary et al., 2020) and gross pathology conducted according to the procedure described previously by King et al. (2013). Sections of liver, kidney, spleen, and heart were collected and preserved in 10% buffered formalin for 24 hours before being processed for histopathology (Rousselle et al., 2019).

Statistical analysis

Data were entered into Microsoft office excel (Microsoft® Office 365™, Microsoft, USA) and analyzed using Graph Pad Prism 8.4.3 (San Diego, CA, USA) for data analysis. Descriptive statistics (means and standard deviations) were determined. The FECR, FOCR, weight, temperature, PCV, and biochemical parameters of different groups were compared with those of non-treated goats using Students t-test ($p < 0.05$).

RESULTS

Efficacy assessment of chitosan nanoencapsulated bromelain

The results showed a relatively high reduction in EPG count mean in all treated goats (Figure 1). On day 7 of treatment, 73.41% (580 EPG), 62.61% (780 EPG), and 79.45% (530 EPG) of reduction of FEC were recorded for goats treated with 270 mg/Kg, 90 mg/Kg of CNB and Albendazole, respectively. Contrariwise, the FEC increased by 107.42% in the untreated group (negative control). The reduction in FEC count reached 100% between day 28 to 77 post-first day of treatment for goats treated with 270 mg/Kg of CNB. During the first month of treatment, there was no significant difference ($p > 0.05$) in fecal egg counts in goats treated with 270 mg/Kg of CNB and the group treated with 7.5 mg/Kg of Albendazole. In the negative control group, the FEC increased by 127.18% on day 28.

Efficacy assessment of chitosan nanoencapsulated bromelain on fecal oocyst count reduction

At the start of the study, the mean OPG in goats in all the groups was similar. Following treatment, the oocyst count reduced gradually between days 7 and 35 of treatment (Figure 2). The reduction percentage in oocyst counts on day 7 post-treatment was higher ($p > 0.05$) for the goats treated with 270 mg/Kg CNB (84.12%, 2,660 OPG) and Diclazuril (82.12%, 3,180 OPG) than those treated with 90 mg/Kg CNB (44.83%, 7,220 OPG). On the other hand, there was an increase in FOC in the animals in the negative control group. This represents a statistically significant reduction in FOCR, which was highest ($p < 0.05$) for goats treated with 270 mg/Kg CNB in comparison to those treated with 90 mg/Kg CNB. In addition, after 28 days of treatment, the FOCR was 100% for the goats treated with 270 mg/Kg.

Toxicity assessment of chitosan nanoencapsulated bromelain

Clinical observations

During the entire period of observation, the administration of 270 mg/Kg of CNB for 60 days did not show any mortalities or clinical signs in the group. The rectal temperature of the animal body varied between 37 to 38.5°C and was within a normal range (Radostitis et al., 2000; Al-Bulushi et al., 2017) for the Small East African goat breed. Following the treatment, there were no significant differences in body temperatures ($p > 0.05$) in goats from different groups. The body weights of the goats before treatment were 25.00 ± 2.58 Kg (positive control Group), 16.50 ± 1.00 Kg (negative control), 16.25 ± 1.26 Kg (270 mg/Kg CNB), and 16.50 ± 1.00 Kg (90 mg/Kg CNB). After three weeks of treatment, the weight had increased to 18.88 ± 1.93 Kg and 18.75 ± 1.70 Kg of goats treated with 270 mg/Kg and 90 mg/Kg CNB, respectively, while the body weight decreased to 24.88 ± 1.84 Kg for positive control (goats treated with Albendazole and Diclazuril) and to 16.13 ± 1.08 Kg for negative control. The mean of body weights for the following treatment groups showed a significant ($p < 0.05$) increase (2.25 Kg) at the end of the study. This increase (compared to day 0) was statistically significant ($p < 0.05$). However, there was a decrease in weight by 0.62 to 1.62 Kg in goats of the positive control group ($p < 0.05$).

Effect of treatments on packed cell volume and biochemical parameters

Before treatment, the PCV levels were 32% (positive control group), 27.25% (negative control), 28.50% (270 mg/Kg CNB), and 28.25% (90 mg/Kg CNB). During the treatment, the PCV levels ranged between 25.25 to 30.00% for the goats treated with 270 mg/Kg and 90 mg/Kg CNB, 26.35 to 30.50% for positive control, and 18.25 to 26% for negative control. There were no significant differences ($p > 0.05$) in the PCV levels during the entire observation period.

During the treatment, AST ranged between 101 and 111 U/L for goats treated with CNB and between 115 and 121 U/L for the positive control group of animals. The ALT level was between 14.89 and 16.74 U/L and 16.51 and 17.93 U/L for goats treated with CNB and positive control, respectively. The creatinine level ranges were between 0.710 and 0.792 mg/L, while that for urea was between 33 and 35.06 mg/L for 270 mg/Kg and 90 mg/Kg CNB during the entire observation period.

Gross pathology and histopathological findings

No gross changes at necropsy were done on days 60 and 150 post first day of treatment. All the organs were normal and similar in both treatment and control Groups. The histopathological assessment showed no changes in the tissues in both groups treated with CNB (90 mg/Kg and 270 mg/Kg).

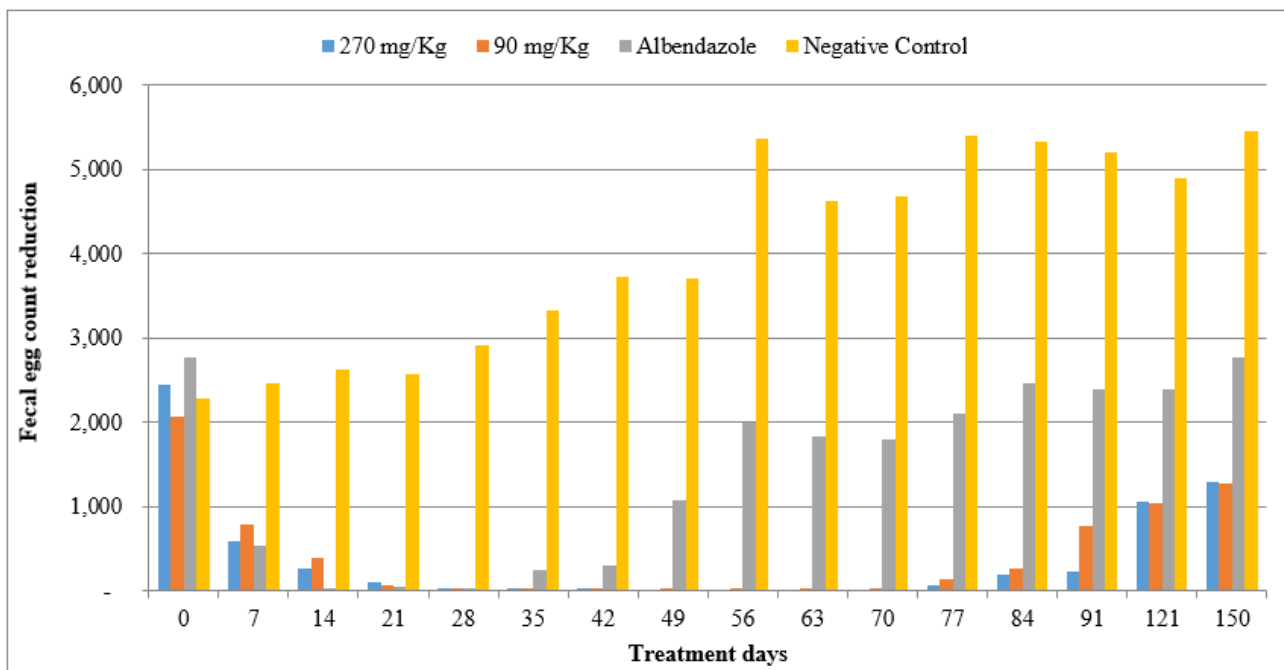


Figure 1. Fecal egg counts reduction in goats treated with chitosan nanoencapsulated bromelain (270 mg/Kg and 90 mg/Kg), Albendazole (7.5 mg/Kg), and untreated goats (negative control) in Kenya

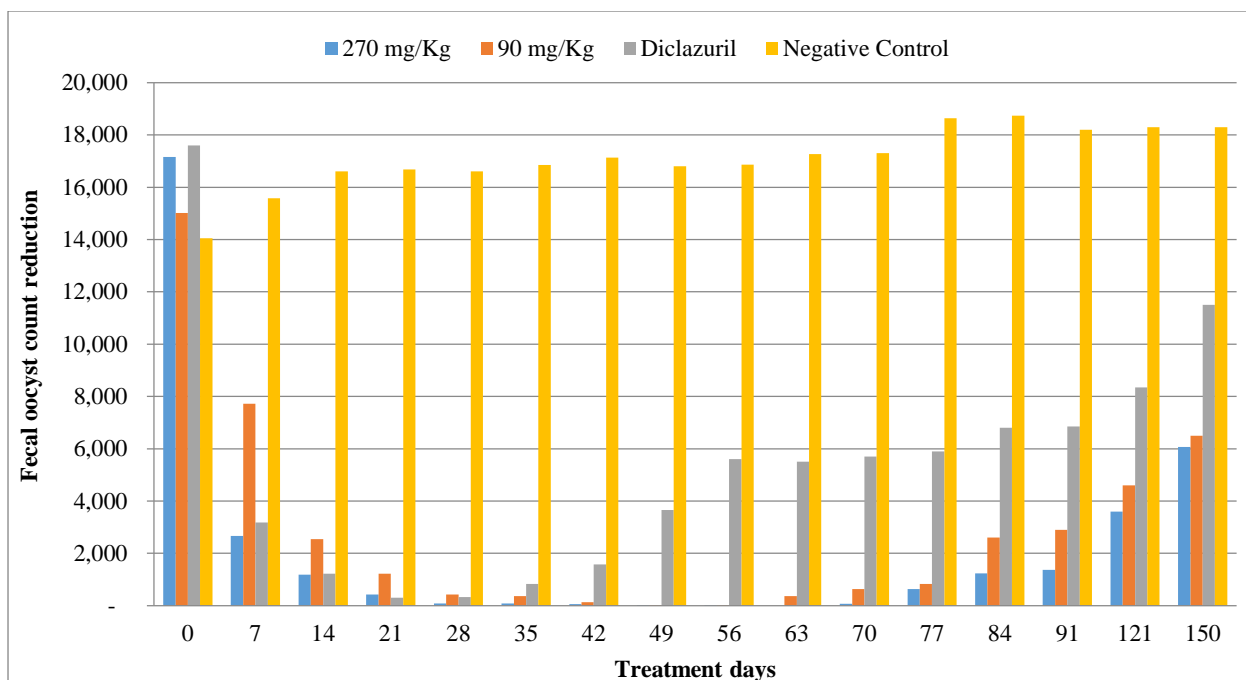


Figure 2. Fecal coccidial oocyst counts reduction in goats treated with chitosan nanoencapsulated bromelain (270 mg/Kg and 90 mg/Kg), diclazuril (5 mg/Kg), and untreated goats (negative control) in Kenya

DISCUSSION

The present study is a continuation of a previous investigation that evaluated the *in vivo* activity of chitosan nanoencapsulated bromelain (CNB) against GIN in Small East African goats in Kenya (Wasso et al., 2020). In the laboratory study, Wasso et al. (2020) observed an anthelmintic efficacy of 68.8% after administering CNB at 30 mg/Kg for 14 days. Administration of a single oral dosage of 90 mg/Kg and 270 mg/Kg CNB caused an efficacy of 9.5 % and 32.4%, respectively, in goats at 28 days post treatment (Wasso et al., 2020). The current study addressed the efficacy of CNB against natural infection of GIN and coccidia in goats. Present study results showed that administering CNB at higher doses considerably decreased the number of GIN eggs excreted by goats and reached 100% by 30 days post-treatment. Previous research on the anthelmintic action of pineapple (*Ananas comosus*) in sheep and goats has found that bromelain to have high efficacy against helminths (Hordegen et al., 2003; Domingues et al., 2013). However, when powdered leaves and plain bromelain were administered to sheep, Hordegen et al. (2003) and Domingues et al. (2013) reported a decrease in nematode eggs. The increased activity of CNB described by Wasso et al. (2020) and in the present study might be attributed to the encapsulation of bromelain with chitosan (Bhatnagar et al., 2014; Cheung et al., 2015). Nanoparticles, such as chitosan, boost the efficacy of drugs by avoiding enzymatic breakdown and increasing the drug's ability to access sites that would otherwise not be accessible to other drugs (Cheung et al., 2015). Bromelain, as previously described, induces cuticle deterioration and death of mature nematodes (Stepek et al., 2006; Behnke et al., 2008). Thus, the drop in egg excretion reported *in vivo* might be related to either adult worm death or a fall in female worm prolificacy. Stepek et al. (2005; 2006) found that papaya latex, which contains cysteine protease, significantly reduced worm load and egg yield in rodent GIN (*Trichuris muris* and *Heligmosomoides polygyrus*). Pascal et al. (2017) gave *Newbouldia laevis* (Bignoniaceae) to sheep and found it to be 55% effective against *H. contortus* and 19% effective against *T. colubriformis*. Hounzangbe-Adote et al. (2001) reported an 80% effectiveness rate of papaya (*Carica papaya*) seed powder on sheep *strongyles* after ten to fifteen days of therapy.

The present study showed that CNB significantly decreased the number of oocysts excreted by the goats to a level of efficacy comparable to the commercial drug (Diclazuril). This suggests that the enzyme is effective against coccidian infections as has also been reported elsewhere (Molan et al., 2009; Juasook et al., 2017; Dakpogan et al., 2019; Abdel-Tawab et al., 2020). Juasook et al. (2017) reported that after treating broilers chicken with crude pineapple extracts (*Ananas comosus*), *Eimeria tenella* oocyst production fell considerably ($p < 0.05$). On the other hand, Dakpogan et al. (2019) showed a 59% decrease in OPG in chicks fed with *Carica papaya* crude extracts. Bromelain has been shown to induce coccidia shell wall disintegration, softening, and loss of the core cytoplasmic mass (Juasook et al., 2017; Daiba et al., 2022).

The current study also evaluated the toxicity of CNB in goats. Similar to a previous study by Wasso et al. (2020), there were no mortalities or adverse clinical signs in the experimental animals. Further, the blood parameters such as PCV were within the species' normal range (Radostitis et al., 2000; Al-Bulushi et al., 2017), which implies that the

longer administration duration was safe. The levels of AST, ALT, creatinine, and urea levels were also within the species' normal range (Radostitis et al., 2000; Jackson and Cockcroft, 2002). Similarly, there were no pathological lesions observed in the goats at postmortem, which agrees with the study by Wasso et al. (2020).

CONCLUSION

The current study found that CNB in chitosan exhibited high activity against GIN and coccidia infections in goats by lowering eggs and oocysts excretion. Further, CNB demonstrated no harmful effects on goats at repeated dosages of 270 mg/Kg. This sets the background and justification for further studies on strategies to improve efficacy through adjusting the dosage and duration of treatment with CNB. This should eventually lead to on-farm trials on the effectiveness of CNB against nematodes and coccidian. This could serve as validation ahead of a commercial venture to utilize this natural product as an alternative treatment of helminths and coccidian in small ruminant stock, but further study needs to prove this theory.

DECLARATIONS

Availability of data and materials

The data presented in this study are available by reasonable requests from the authors.

Funding

This study was fully funded by the Pan-African University of Institute of Basic Science, Technology, and Innovation (PAUSTI),

Ethical consideration

All the authors have carefully examined all ethical issues concerning plagiarism, approval to publish, data fabrication and/or falsification, double publication, and submission.

Acknowledgments

The authors acknowledge Pan-African University of Institute of Basic Science, Technology and Innovation (PAUSTI), and Jomo Kenyatta University of Agriculture and Technology (JKUAT) for financially sponsoring this research and providing technical and infrastructural support used during the project.

Competing interests

No competing interests.

Authors' contributions

All authors contributed to the conception of the experiments. Ahmota Romain Daiba, John Maina Kagira, and Maina Ngotho planned the study design. Ahmota Romain Daiba, James Kimotho, and Maina Ngotho performed sample collection and laboratory work. Naomi Maina conducted the data analyses. Ahmota Romain Daiba and John Maina Kagira wrote the draft of the manuscript. All authors corrected, read, and approved the final manuscript.

REFERENCES

- Abdel-Tawab H, Abdel-Baki AS, El-Mallah AM, Al-Quraishy S, and Abdel-Haleem HM (2020). *In vivo* and *in vitro* anticoccidial efficacy of *Astragalus membranaceus* against *Eimeria papillata* infection. *Journal of King Saud University-Science*, 32(3): 2269-2275. DOI: <https://www.doi.org/10.1016/j.jksus.2020.03.016>
- Al-Bulushi S, Shawaf T, and Al-Hasani A (2017). Some hematological and biochemical parameters of different goat breeds in Sultanate of Oman: A preliminary study. *Veterinary World*, 10(4): 461-466. DOI: <https://www.doi.org/10.14202/vetworld.2017.461-466>
- Bawm S and Htun LL (2021). Management and control of eimeria infection in goats. In: S. Kukovics (Editor), *Goat science*. Intech Open. DOI: <https://www.doi.org/10.5772/intechopen.98979>
- Behnke JM, Buttle DJ, Stepek G, Lowe A, and Duce IR (2008). Developing novel anthelmintics from plant cysteine proteinases. *Parasites and Vectors*, 1(1): 29. Available at: <https://link.springer.com/article/10.1186/1756-3305-1-29>
- Bhatnagar P, Patnaik S, Srivastava AK, Mudiam MKR, Shukla Y, Panda AK, and Gupta KC (2014). Anti-cancer activity of bromelain nanoparticles by oral administration. *Journal of Biomedical Nanotechnology*, 10(12): 3558-3575. DOI: <https://www.doi.org/10.1166/jbn.2014.1997>
- Cheung RCF, Ng TB, Wong JH, and Chan WY (2015). Chitosan: An update on potential biomedical and pharmaceutical applications. *Marine Drugs*, 13(8): 5156-5186. DOI: <https://www.doi.org/10.3390/md13085156>
- Coles GC, Bauer C, Borgsteede FHM, Geerts S, Klei TR, Taylor MA, and Waller PJ (1992). World association for the advancement of veterinary parasitology (WAAVP) methods for the detection of anthelmintic resistance in nematodes of veterinary importance. *Veterinary Parasitology*, 44: 35-44. DOI: [https://www.doi.org/10.1016/0304-4017\(92\)90141-U](https://www.doi.org/10.1016/0304-4017(92)90141-U)

- Cringoli G, Rinaldi L, Veneziano V, Capelli G, and Scala A (2004). The influence of flotation solution, sample dilution and the choice of McMaster slide area (volume) on the reliability of the McMaster technique in estimating the faecal egg counts of gastrointestinal strongyles and *Dicrocoelium dendriticum* in sheep. *Veterinary Parasitology*, 123(1-2): 121-131. DOI: <https://www.doi.org/10.1016/j.vetpar.2004.05.021>
- Daiba AR, Kagira JM, Ngotho M, Kimotho J, and Maina N (2022). *In vitro* anticoccidial activity of nanoencapsulated bromelain against *Eimeria* spp. oocysts isolated from goats in Kenya. *Veterinary World*, 15: 397-402. DOI: <https://www.doi.org/10.14202/vetworld.2022.397-402>
- Dakpogan HB, Mensah S, Attindehou S, Chysostome C, Aboh A, Naciri M, Salifou S, and Mensah GA (2019). Anticoccidial activity of *Carica papaya* and *Vernonia amygdalina* extract. *International Journal of Biological and Chemical Sciences*, 12(5): 2101-2108. DOI: <https://www.doi.org/10.4314/ijbcs.v12i5.12>
- Domingues LF, Gigliotti R, Feitosa KA, Fantatto RR, Rabelo MD, de Sena Oliveira MC, Bechara GH, de Oliveira GP, Barioni Junior W, and de Souza Chagas AC (2013). *In vitro* and *in vivo* evaluation of the activity of pineapple (*Ananas comosus*) on *Haemonchus contortus* in Santa Inês sheep. *Veterinary Parasitology*, 197(1-2): 263-270. DOI: <https://www.doi.org/10.1016/j.vetpar.2013.04.031>
- Emma N, Judith S, Peter M, and Naomi M (2020). Sub-acute and chronic toxicity of silver nanoparticles synthesized by *Azadirachta indica* extract. *African Journal of Biotechnology*, 19(6): 320-331. DOI: <https://www.doi.org/10.5897/ajb2020.17057>
- Etsay K, Megbey S, and Yohannes H (2020). Prevalence of sheep and goat coccidiosis in different districts of Tigray region, Ethiopia. *Nigerian Journal of Animal Science*, 22(3): 61-69. Available at: <https://www.ajol.info/index.php/tjas/article/view/202088>
- Faizal ACM and Rajapakse RPVJ (2001). Prevalence of coccidia and gastrointestinal nematode infections in cross bred goats in the dry areas of Sri Lanka. *Small Ruminant Research*, 40(3): 233-238. DOI: [https://www.doi.org/10.1016/S0921-4488\(01\)00179-1](https://www.doi.org/10.1016/S0921-4488(01)00179-1)
- Githiori JB (2004). Evaluation of anthelmintic properties of ethnoveterinary plant preparations used as livestock dewormers by pastoralists and small holder farmers in Kenya. Doctoral Thesis, Swedish University of Agricultural Sciences, Uppsala, Sweden and International Livestock Research Institute (ILRI), Nairobi, Kenya. Available at: https://pub.epsilon.slu.se/514/1/John_Githiori_Thesis.pdf
- Hema S, Arun T, Senthilkumar B, Senbagam D, and Sureshkumar M (2015). *In vivo* anticoccidial effects of *Azadirachta indica* and *Carica papaya* L. with salinomycin drug as a dietary feed supplement in broiler chicks. *Pakistan Journal of Pharmaceutical Sciences*, 28(4): 1409-1415. Available at: <https://www.cabdirect.org/cabdirect/abstract/20153311842>
- Hordegen P, Hertzberg H, Heilmann J, Langhans W, and Maurer V (2003). The anthelmintic efficacy of five plant products against gastrointestinal trichostrongylids in artificially infected lambs. *Veterinary Parasitology*, 117: 51-60. DOI: <https://www.doi.org/10.1016/j.vetpar.2003.07.027>
- Hounzangbe-Adote MS, Zinsou FE, Affognon KJ, Koutinhoun B, Adamou N'Diaye M, and Moutairou K (2001). Efficacité antiparasitaire de la poudre de graines de papaye (*Carica papaya*) sur les strongles gastro-intestinaux des moutons Djallonké au sud du Bénin [Antiparasitic efficacy of papaya (*Carica papaya*) seed powder on gastrointestinal roundworms of Djallonké sheep in southern Benin]. *Revue d'élevage et de Médecine Vétérinaire Des Pays Tropicaux*, 54(3-4): 225. DOI: <https://www.doi.org/10.19182/remvt.9778>
- Hunduza A, Kagira J, Maina N, Andala D, Cheruiyot K, and Kahiro S (2020). *In vitro* Anthelmintic activity of chitosan encapsulated bromelain against eggs, larval and adult stages of *haemonchus contortus*. *Journal of Applied Life Sciences International*, 23(3): 28-38. DOI: <https://www.doi.org/10.9734/jalsi/2020/v23i330151>
- Ibrahim N, Tefera M, Bekele M, and Alemu S (2014). Prevalence of gastrointestinal parasites of small ruminants in and around Jimma Town, Western Ethiopia. *Acta Parasitologica Globalis*, 5(1): 12-18. Available at: <https://b2n.in/r52213>
- Jackson PG and Cockcroft PD (2002). *Clinical examination of farm animals*. Wiley-Blackwell Science Ltd., p. 302. DOI: <https://www.doi.org/10.1002/9780470752425.ch17>
- Jansen MS, Nyangiwe N, Yawa M, Dastile M, Mabhece V, Muchenje V, and Mpendulo TC (2020). Prevalence and seasonal variation of gastrointestinal nematodes and coccidia infecting ovine grazing on communal rangelands in the Eastern Cape, South Africa. *Parasitology Research*, 119(12): 4169-4175. DOI: <https://www.doi.org/10.1007/s00436-020-06927-6>
- Juasook A, Aengwanich W, Chalalai T, Watwiengkam N, Asawapattanakul T, and Promsud W (2017). Changes in sporulation, packed cell volume, malondialdehyde level, fecal oocyst count and histopathology of *Eimeria tenella*-infected broilers treated with pineapple (*Ananas comosus*) crude extracts. *International Journal of Poultry Science*, 16(5): 189-195. DOI: <https://www.doi.org/10.3923/ijps.2017.189.195>
- Kanyari PWN, Kagira JM, and Mhoma RJ (2009). Prevalence and intensity of endoparasites in small ruminants kept by farmers in Kisumu Municipality, Kenya. *Livestock Research for Rural Development*, 21(11): 202. Available at: <http://www.lrrd.org/lrrd21/11/kany21202.htm>
- Kaplan RM, Klei TR, Lyons ET, Lester G, Courtney CH, French, DD, Tolliver SC, Vidyashankar AN, and Zhao Y (2004). Prevalence of anthelmintic resistant cyathostomes on horse farms. *Journal of the American Veterinary Medical Association*, 225(6): 903-910. DOI: <https://www.doi.org/10.2460/javma.2004.225.903>
- King JM, Roth-Johnson L, Dodd DC, and Newsom ME (2013). *The necropsy book: A guide for veterinary students, residents, clinicians, pathologists, and biological researchers*. The Internet-First University Press., pp. 33-35. Available at: <http://hdl.handle.net/1813/37948>
- Leary S, Anthony R, Cartner S, Grandin T, Collins F, Greenacre C, Gwaltney-brant S, McCrackin MA, Meyer R, Miller D et al. (2020). AVMA guidelines for the euthanasia of animals: 2020 Edition. Available at: <https://www.avma.org/sites/default/files/2020-02/Guidelines-on-Euthanasia-2020.pdf>
- Maichomo MW, Kagira JM, and Walker T (2004). The point prevalence of gastrointestinal parasites in calves, sheep and goats in Magadi division, South-Western Kenya. *Onderstepoort Journal of Veterinary Research*, 71(4): 257-261. DOI: <https://www.doi.org/10.4102/ojvr.v71i4.229>
- Maingi N and Munyua WK (1994). The prevalence and intensity of infection with *Eimeria* species in sheep in nyandarua district of Kenya. *Veterinary Research Communications*, 18: 19-25. DOI: <https://www.doi.org/10.1007/BF01839257>
- Mat Yusof A and Md Isa ML (2016). Prevalence of gastrointestinal nematodiasis and coccidiosis in goats from three selected farms in Terengganu, Malaysia. *Asian Pacific Journal of Tropical Biomedicine*, 6(9): 735-739. DOI: <https://www.doi.org/10.1016/j.apjtb.2016.07.001>
- Menge DMS, Makobe M, Monda EO, and Okemo PO (2014). Effects of crude extracts on some selected physiological parameters of French beans (*Phaseolus vulgaris*) infected with rust (*Uromyces appendiculatus*). *African Journal of Plant Science*, 8(7): 356-363. DOI: <https://www.doi.org/10.5897/AJPS12.033>
- Mickiewicz M, Czopowicz M, Moroz A, Potárniche AV, Szaluś-Jordanow O, Spinu M, Górski P, Markowska-Daniel I, Várady M, and Kaba J (2021). Prevalence of anthelmintic resistance of gastrointestinal nematodes in Polish goat herds assessed by the larval development test. *BMC Veterinary Research*, 17(1): 19. DOI: <https://www.doi.org/10.1186/s12917-020-02721-9>
- Misran E, Idris A, Mat Sarip SH, and Ya'akob H (2019). Properties of bromelain extract from different parts of the pineapple variety Morris. *Biocatalysis and Agricultural Biotechnology*, 18: 101095. DOI: <https://www.doi.org/10.1016/j.bcab.2019.101095>
- Mohamaden WI, Sallam NH, and Abouelhassan EM (2018). Prevalence of *Eimeria* species among sheep and goats in Suez Governorate, Egypt. *International Journal of Veterinary Science and Medicine*, 6(1): 65-72. DOI: <https://www.doi.org/10.1016/j.ijvsm.2018.02.004>
- Molan AL, Liu Z, and De S (2009). Effect of pine bark (*Pinus radiata*) extracts on sporulation of coccidian oocysts. *Folia Parasitologica*, 56(1): 1-5. DOI: <https://www.doi.org/10.14411/fp.2009.001>

- Noack S, Chapman HD, and Selzer PM (2019). Anticoccidial drugs of the livestock industry. *Parasitology Research*, 118(7): 2009-2026. DOI: <https://www.doi.org/10.1007/s00436-019-06343-5>
- Odden A, Denwood MJ, Stuen S, Robertson LJ, Ruiz A, Hammes IS, Hektoen L, and Enemark HL (2018). Field evaluation of anticoccidial efficacy: A novel approach demonstrates reduced efficacy of toltrazuril against ovine *Eimeria spp.* in Norway. *International Journal for Parasitology: Drugs and Drug Resistance*, 8(2): 304-311. DOI: <https://www.doi.org/10.1016/j.ijpddr.2018.05.002>
- Organization for economic cooperation and development (OECD) (2002). OECD guideline for testing of chemicals. Test No. 423: Acute oral toxicity - Acute toxic class method, pp. 1-14. Available at: https://www.oecd-ilibrary.org/environment/test-no-423-acute-oraltoxicity-acute-toxic-class-method_9789264071001-en
- Parasuraman S (2011). Toxicological screening. *Journal of Pharmacology and Pharmacotherapeutics*, 2(2): 74-79. DOI: <https://www.doi.org/10.4103/0976-500X.81895>
- Pascal OA, Eloi AY, Bertrand AEV, Sylvie HAM, and Hervé H (2017). Effet *In Vivo* de *newbouldia laevis* (Bignoniaceae) sur des strongles gastro-intestinaux des moutons [*In vivo* effect of *newbouldia laevis* (Bignoniaceae) on gastrointestinal roundworms of sheep]. *European Scientific Journal*, 13(12): 335. DOI: <https://www.doi.org/10.19044/esj.2017.v13n12p335>
- Potârniche AV, Mickiewicz M, Olah D, Cerbu C, Spînu M, Hari A, Györke A, Moroz A, Czopowicz M, Várady M et al. (2021). First report of anthelmintic resistance in gastrointestinal nematodes in goats in Romania. *Animals*, 11(10): 2761. DOI: <https://www.doi.org/10.3390/ani11102761>
- Radostitis CC, Gray DC, and Hinchcliff KK (2000). Blood and diseases caused by trypanosomes. In: M. Otto, C. Clive, C. Douglas, W. Kenneth, C. Gay, K. Hinchcliff, and D. Russel (Editors), *A text book of the diseases of cattle, sheep, pigs, goats and horse*, 9th Edition. WB Saunders Company Ltd., New York, p. 1877. Available at: http://sutlib2.sut.ac.th/sut_contents/H111504.pdf
- Rousselle SD, Wicks JR, Tabb BC, Tellez A, and O'Brien M (2019). Histology strategies for medical implants and interventional device studies. *Toxicologic Pathology*, 47(3): 235-249. DOI: <https://www.doi.org/10.1177/0192623319827288>
- Sadr S, Ahmadi SP, Kasaei M, Gholipour LM, Borji H, and Adhami G (2022). Potential of anthelmintic herbal drugs against gastrointestinal nematodes in farm animals: A review. *Farm Animal Health and Nutrition*, 1(1): 26-30. DOI: <https://doi.org/10.58803/fahn.v1i1.9>
- Shamaki BU, Sandabe UK, Abdulrahman FI, Ogbe AO, Hassan ZI, Yusuf IL, Bitrus W, Zongoma Y, and Isikhuemhen OS (2017). Toxicity studies and body weights changes in wistar rats following oral administration of methanol extract from indigenous *Ganoderma* Sp. In Nigeria. *MOJ Biology and Medicine*, 1(5): 138-141. DOI: <https://www.doi.org/10.15406/mojbm.2017.01.00030>
- Steppek G, Buttle DJ, Duce IR, Lowe A, and Behnke JM (2005). Assessment of the anthelmintic effect of natural plant cysteine proteinases against the gastrointestinal nematode, *Heligmosomoides polygyrus*, *in vitro*. *Parasitology*, 130(2): 203-211. DOI: <https://www.doi.org/10.1017/S0031182004006225>
- Steppek G, Lowe AE, Buttle DJ, Duce IR, and Behnke JM (2006). *In vitro* and *in vivo* anthelmintic efficacy of plant cysteine proteinases against the rodent gastrointestinal nematode, *Trichuris muris*. *Parasitology*, 132(5): 681-689. DOI: <https://www.doi.org/10.1017/S003118200500973X>
- Waruru RM, Mutune MN, and Otieno RO (2005). Gastrointestinal parasite infections of sheep and goats in a semi-arid area of Machakos District, Kenya. *Bulletin of Animal Health and Production in Africa*, 53(1): 25-34. DOI: <https://www.doi.org/10.4314/bahpa.v53i1.32686>
- Wasso S, Maina N, and Kagira J (2020). Toxicity and anthelmintic efficacy of chitosan encapsulated bromelain against gastrointestinal strongyles in small East African goats in Kenya. *Veterinary World*, 13(1): 177-183. DOI: <https://www.doi.org/10.14202/vetworld.2020.177-183>
- Wondimu A and Bayu Y (2022). Anthelmintic drug resistance of gastrointestinal nematodes of naturally infected goats in Haramaya, Ethiopia. *Journal of Parasitology Research*, 2022: 4025902. DOI: <https://www.doi.org/10.1155/2022/4025902>

Publisher's note: [Scienceline Publication](#) Ltd. remains neutral with regard to jurisdictional claims in published maps and institutional affiliations.



Open Access: This article is licensed under a Creative Commons Attribution 4.0 International License, which permits use, sharing, adaptation, distribution and reproduction in any medium or format, as long as you give appropriate credit to the original author(s) and the source, provide a link to the Creative Commons licence, and indicate if changes were made. The images or other third party material in this article are included in the article's Creative Commons licence, unless indicated otherwise in a credit line to the material. If material is not included in the article's Creative Commons licence and your intended use is not permitted by statutory regulation or exceeds the permitted use, you will need to obtain permission directly from the copyright holder. To view a copy of this licence, visit <https://creativecommons.org/licenses/by/4.0/>.

© The Author(s) 2023