



The Toxicity Assessment of Chicken Liver-Based Drug Filler Supplemented with Itraconazole

Prapatantio Teteg Pringgodigdoyo^{1*}, Wasmen Manalu², Andriyanto², Aulia Andi Mustika², and Lina Noviyanti Sutardi²

¹Animal Biomedical Science Study Program, School of Veterinary Medicine and Biomedical Sciences (SVMBBS), IPB University, Bogor 16680, Indonesia

²Division of Physiology, Pharmacology and Toxicology, and Subdivision of Pharmacy, School of Veterinary Medicine and Biomedical Sciences (SVMBBS), IPB University, Bogor 16680, Indonesia

*Corresponding author's Email: prapatantio@gmail.com

ABSTRACT

Itraconazole is a systemic antifungal often used for fungal infection treatment in cats. This study aimed to evaluate the safety of chicken liver paste as a drug filler through an acute toxicity test when supplemented with itraconazole. A total of 25 female mice were used and divided into five groups, each consisting of five mice. The control group received chicken liver paste without any itraconazole supplementation. In contrast, the treatment groups were administered chicken liver paste supplemented with itraconazole at 5, 10, 15, and 20 g/kg body weight dosages. Observations were conducted for two weeks. The evaluated parameters included abnormal clinical signs, mortality, body temperature, weight gain, and hematology profile. During the 14 days of observation, no mortality or abnormal clinical signs were observed. Other parameters such as body temperature and weight increase showed no significant difference. Hematology profile including red blood cells (RBC), hemoglobin (HB), hematocrit (Hct), mean corpuscular volume (MCV), mean corpuscular hemoglobin (MCH), red cell distribution width (RDW), thrombocyte (PLT), mean platelet volume (MPV), platelet distribution width (PDW), plateletcrit (PCT), white blood cells (WBC), lymphocytes, monocytes, and granulocytes remained within the standard ranges and showed no significant difference. The present study indicated that chicken liver paste supplemented with itraconazole falls into the practically nontoxic category with an estimated LD50 value exceeding 20 g/kg body weight.

Keywords: Chicken, Hematology, Itraconazole, LD50, Liver, Mice

INTRODUCTION

In recent years, there has been an increase in pet ownership all over the globe. Pets, such as dogs and cats, provide companionship and passionate support, regularly considered integral members of the family. While owning pets comes with numerous benefits, it also entails responsibilities, particularly in maintaining their health. It is estimated that there are roughly around 470 million dogs and 370 million cats owned and kept as pets worldwide (Jalongo, 2021). Numerous observational studies suggest that interactions and relationships with companion animals may be beneficial for human mental and physical health, with hypothesized mechanisms involving attachment to and companionship provided by pets (Brooks et al., 2018).

Pets require regular visits to veterinarians periodically, either for preventive care or for treating diseases (Suchodolski, 2024). Cat owners frequently report challenges in administering medicine, such as cats refusing to take medicine even though it is blended with food, spitting out the medicine, or experiencing hypersalivation (Sivén et al., 2017). These challenges may lead to injuries for pet owners trying to convince unwilling cats to take medication. Additionally, failing to complete prescribed treatments can have broader health implications, including the development of antimicrobial, antifungal, and antiparasitic resistance, which is a growing concern in both veterinary and human medication (Joosten et al., 2020). One of the ways to make oral drug administration easier in cats is to ensure that the medicines are palatable (Taylor et al., 2022). The palatability of cat food is often related to flavor, smell, shape, texture, and mouthfeel sensation. If the medicine formulation suits the palatability, cats are more likely to consume it voluntarily (Petry et al., 2014). Cats are known to seldom ingest the medication in oral form such as tablets, especially if the drug is bitter or odorous (Ekweremadu et al., 2020). Cats are originally solitary hunters and obligate carnivores which often kill much smaller prey than their body size. Smaller prey is often consumed in one portion, with the flesh of larger prey ripped off and the organs such as the liver are eaten (Aldrich and Koppel, 2015). Despite being classified as carnivores, cats have specific dietary requirements, especially for protein, with a 30% protein daily requirement (Watson et al., 2023). According to the U.S. Department of Agriculture (2019), a 100-gram portion of chicken liver contains 66.8 g of water, 24.5 g of protein, 6.51 g of total lipid (fat), 1.36 g ash content, and 0.87 g of carbohydrate. Chicken liver is a

ORIGINAL ARTICLE
Received: October 13, 2024
Revised: November 14, 2024
Accepted: November 28, 2024
Published: December 30, 2024

nutrient-rich food, high in protein, and is palatable to carnivorous animals (Pinto et al., 2021). Given these properties, chicken liver could serve as an ideal palatable drug filler for administering medications to cats, particularly in a semi-solid or paste form, which may be more convenient for both cats and their owners than tablets or capsules.

Skin lesions due to fungal infestation or dermatophytosis are common diseases and common health issues for cats (Thakare et al., 2019). Itraconazole, a systemic antifungal agent, is often used in the management and treatment of fungal infections. It is of the high frequently used in treating cases of dermatophytosis and is particularly effective and safer than other antifungals such as ketoconazole for treating dermatophytosis in cats (Thakare et al., 2019). This study aimed to evaluate the safety of chicken liver paste supplemented with itraconazole as a drug filler via acute toxicity tests in mice.

MATERIALS AND METHODS

Ethical approval

This study was approved by the Animal Ethics Committee of the School of Veterinary Medicine and Biomedical Sciences (SVMBS), IPB University, Indonesia under approval number 185/KEH/SKE/III/2024. This study was conducted at the Laboratory Animal Management Unit of SVMBS, IPB University, Indonesia. The production process of hydrolyzed chicken liver was conducted at Nutricell Pacific, Indonesia, and chicken liver formulation as a drug filler was conducted at the Pharmacy Laboratory of the School of Veterinary Medicine and Biomedical Sciences (SVMBS), IPB University, Indonesia.

Formulation of chicken liver paste

The base formulation was developed using 3% xanthan gum, 5% propylene glycol, 0.1% Ethylenediaminetetraacetic acid (EDTA), and aquadest. The base formulation of the paste was prepared by dispersing gelling agent xanthan gum in distilled water containing dissolved propylene glycol and EDTA. The resulting mixture was heated at a temperature of 60 °C for 5 minutes and stirred continuously until it formed a gel. Afterward, 10% chicken liver powder was added using a mortar and pestle. The base of chicken liver paste formulations was labeled as F0, while the paste supplemented with itraconazole was labeled as F1, as shown in Table 1 and Figure 1.

Acute toxicity test of chicken liver paste

The acute toxicity test followed the method of determining the lethal dose (LD50) according to the BPOM (2014) guidelines for determining the toxicity of chicken liver paste supplemented with itraconazole. To reduce stress levels, the mice were adapted to the environment for 14 days before the study. They received an oral dose of ivermectin (0.04 mg/kg body weight) as an antiparasitic agent on the first day of acclimation (Jusuf et al., 2023).

A total of 25 female mice acclimatized to the environment, were divided into five groups, each consisting of five animals. Group 1 (the control group) was given the base chicken liver paste (F0). The other four treatment groups (Groups 2, 3, 4, and 5) were administered chicken liver paste supplemented with itraconazole at doses of 5, 10, 15, and 20 g/kg body weight mice via oral gavage as shown in Figure 2. Each mouse received a single oral gavage dose on the first day of the study. During the 14 days of the study, the mice were monitored for any abnormal clinical signs, which included inappetence, skin changes such as inflammation signs, behavioral abnormalities, irregular breathing, abnormal stool consistency, abnormal signs of urinating, incoordination, and hypersalivation. Average body temperatures and mortality rates were also observed. Their body weights were measured on days 0, 7, and 14, and increases in body weight were calculated from days 0 to 7 and from days 7 to 14. At the end of the 14-day observation period, a blood sample (1 mL) was collected for hematological analysis.

Hematology analysis

One mL of blood was taken intracardiac using an EDTA tube on day 14 to analyze the hematology profile. The hematology profile was analyzed using a hematology analyzer (Vetscan HM5, PT. Mega Utama Medica, Indonesia). The parameters analyzed included red blood cells (RBC), hemoglobin (HB), white blood cells (WBC), lymphocytes, monocytes, granulocytes, hematocrit (Hct), mean corpuscular volume (MCV), mean corpuscular hemoglobin (MCH), mean corpuscular hemoglobin concentration (MCHC), red cell distribution width (RDW), thrombocyte (PLT), mean platelet volume (MPV), platelet distribution width (PDW), and plateletcrit (PCT).

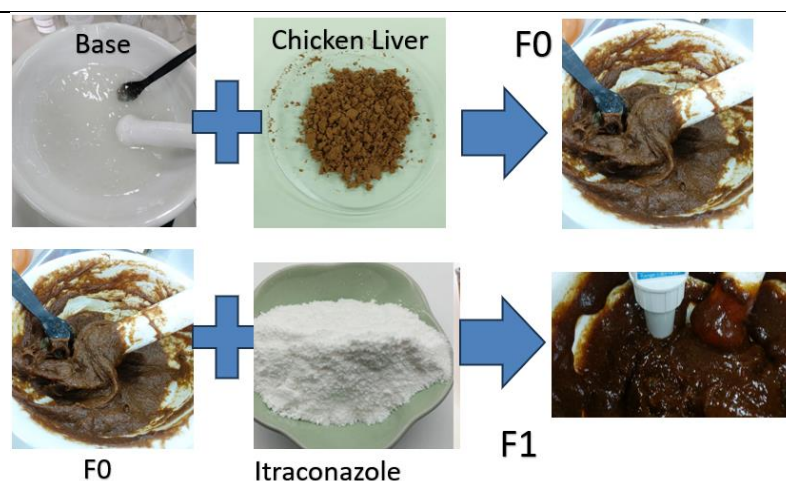
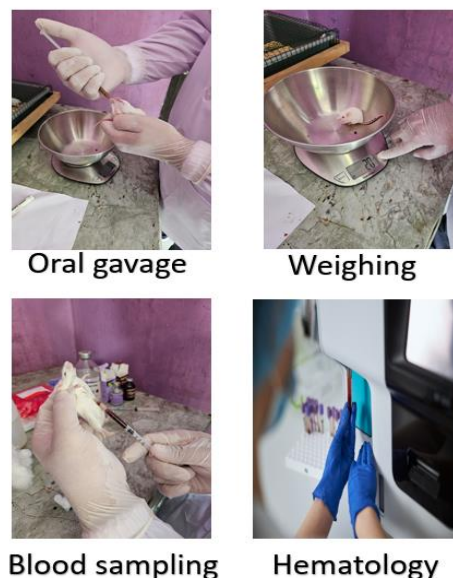
Data analysis

Data was analyzed using Analysis of Variance (ANOVA), with a significant level set at $p < 0.05$, followed by the Tukey test using SPSS 20 software.

Table 1. Formulation of chicken liver as a drug filler in paste form

Materials	Role	F0 (%)	F1 (%)
Itraconazole	Antifungal	0	0.2
Chicken liver powder	Filler	10	10
Xanthan gum	Gelling agent	3	3
Propylene glycol	Binding agent	5	5
EDTA	Chelating agent	0.1	0.1
Aquadest	Solvent	81.9	81.7

The base of chicken liver paste formulations was labeled as F0 and paste supplemented with itraconazole as F1; Source: [Silva et al. \(2020\)](#).

**Figure 1.** Preparation of chicken liver paste**Figure 2.** Mice's oral gavage preparation and evaluation of body weight, blood sampling, and hematology.

RESULTS AND DISCUSSION

Acute toxicity (LD50)

Determination of toxic range is expressed by Lethal Dose 50 or LD50. If a substance with a dose of 20 g/kg of body weight does not cause mortality and toxicity clinical signs up to 14 days posttreatment, then the substance can be categorized as practically non-toxic ([BPOM, 2014](#)). In this study, none of the mice showed any mortality during the 14 days of observation, indicating that the substance falls into the practically nontoxic category, with an LD50 value greater than 20 g/kg body weight.

The results concerning the observation of abnormal clinical signs are presented in Table 2. None of the mice showed any abnormal clinical signs during the 14 days of observation. All mice showed normal behavior, normal water, and feed intake, no abnormal skin changes, regular breathing, normal stool consistency, and no abnormal signs of urinating. Furthermore, there were no signs of incoordination, convulsion, paralysis, tremors, or hypersalivation. These findings suggest that the administration of chicken liver paste supplemented with itraconazole did not cause any abnormal clinical signs.

Table 2. Body weight increase of mice per week during the observation period

Treatment group	BWI 1 (g)	BWI 2 (g)
Group 1	2.00 ± 1.10 ^a	1.67 ± 0.85 ^a
Group 2	1.50 ± 0.85 ^a	2.00 ± 0.89 ^a
Group 3	2.00 ± 0.63 ^a	2.00.33 ± 0.82 ^a
Group 4	2.50 ± 0.84 ^a	1.67 ± 0.82 ^a
Group 5	2.33 ± 0.82 ^a	1.50 ± 0.55 ^a

Different superscript letters in each column indicate significant differences ($p < 0.05$). BWI: Body weight increase, BWI 1: Body weight increase during the first week; BWI 2: Body weight increase during the second week

The average body temperature of the mice during the observation period for Groups 1 to 5 were $36.97 \pm 0.32^{\circ}\text{C}$, $37.15 \pm 0.55^{\circ}\text{C}$, $36.92 \pm 0.32^{\circ}\text{C}$, $36.83 \pm 0.44^{\circ}\text{C}$ and $37.183 \pm 0.30^{\circ}\text{C}$, consecutively. Based on the result, no significant differences in body temperature were observed between the groups ($p > 0.05$). The average body temperature ranged from 36.8 to 37.1°C . It is worth noting that changes in body temperature can show signs of toxicity. Drugs and all types of substances with toxic potential can affect the body temperature of animals. This change in body temperature is mostly shown with hyperthermia (Mozafari *et al.*, 2016). According to Ribeiro *et al.* (2022), the normal range of body temperature in mice falls within the range of $36.5\text{--}38.0^{\circ}\text{C}$. Considering the fact that the temperatures shown by experimental animals fell within this range, it can be suggested that the administration of chicken liver paste supplemented with itraconazole did not cause any fluctuation in the body temperature of the mice.

Body weight increases per week are shown in Table 2. The purpose of observing this parameter was to find out whether the mice experienced fluctuated body weight increase after the administration of preparation. Conditions that indicate the experimental animals had, in general, experienced any kind of pain or suffering could be seen if the body weight had decreased by more than 20% in seven days or more. Animals with no experience of fluctuating changes in body weight indicate that they have not experienced pain or suffering after the administration of the substance (Nurfaat, 2016). Based on the result, the animals did not experience any body weight decrease but experienced a mean increase instead. This increase does not show any significant difference between the control group and the treatment groups. This finding indicated that the administration of chicken liver paste supplemented with itraconazole did not alter the growth of the mice under study.

According to the National Center for Biotechnology Information (NCBI, 2024), itraconazole has different LD50 values depending on the animal species. For instance, in rats and mice, the LD50 is greater than 320 mg/kg, while in dogs and guinea pigs, it is greater than 200 mg/kg and 160 mg/kg, respectively. In the present study, the chicken liver paste supplemented with itraconazole in mice showed a much higher safety range (greater than 20,000 mg/kg or 20 g/kg) compared to previous studies due to the dilution effect of the chicken liver, which acts as a drug filler. The low dose of itraconazole in this formulation likely contributed to the low toxicity observed, making it easier and more precise to administer compared to commercially available higher doses (e.g., 100 mg tablets).

Hematology profile

Hematology analysis was performed on day 14 by collecting 1 ml of blood from each mouse. The results of the hematology profile are shown in Table 3. No significant differences were observed between the groups ($p > 0.05$), and all parameters fell within the normal range. Hematological and clinical biochemical parameters are critical markers of the overall health status of animals and can be used to investigate the toxicity of drugs and chemicals (Niyomchan *et al.*, 2023). Available evidence has shown that the consumption of toxic plants or agents can cause alterations in the hematology profile (Zahmati and Saljooghi, 2016). The results of this study showed no significant differences between the control group and the treatment groups, with almost all hematological parameters still falling within the normal range as compared to a study done by Haney *et al.* (2019).

The only hematology profile parameter that was not within the normal range was MCHC (mean corpuscular hemoglobin concentration, g/dL) in Group 4, which received the highest dose of chicken liver paste supplemented with itraconazole. However, it is not significantly different compared to other groups ($p > 0.05$). The MCHC in Group 4 was 32.61 g/dL, slightly above the normal range of 22.3–32 g/dL. MCHC is the hemoglobin concentration in a group of red blood cells (Cascio and DeLoughery, 2017). MCHC values above the normal range may indicate hyperchromic anemia, which can be caused by the hemolysis of red blood cells, causing the release of hemoglobin into the plasma, which ultimately leads to hemoglobinemia (Lepkov *et al.*, 2023). This is mostly caused by vitamin B12 deficiency. Although the MCHC value in Group 4 was found to be slightly above the normal range, Hb and RBC counts were still within the normal range. This may indicate a small amount of vitamin deficiency, which will not affect overall health.

Itraconazole is an orally administered triazole antifungal agent used in the treatment of systemic and superficial fungal infections. Itraconazole therapy is associated with transient, mild-to-moderate serum elevations and can lead to clinically apparent acute drug-induced liver injury. The liver injury from itraconazole typically presents 1 to 6 months after starting therapy with symptoms of fatigue and jaundice (NCBI, 2024). Jaundice is, in fact, the yellow color of skin and mucous membranes due to the accumulation of bile pigments in blood and their deposition in body tissues. The hematology profile may provide evidence for hemolysis by demonstrating anemia (Stillman *et al.*, 1990). According to the World Health Organization (WHO), anemia is defined as a condition in which the hemoglobin content is below normal. Based on Table 3, the hemoglobin (Hb) level for all treatments was within the normal range of 11–15.10 g/dL with no significant difference ($p > 0.05$). This result indicates that the chicken liver paste supplemented with itraconazole in mice would not develop anemia.

Table 3. The hematology profile of the female mice treated with Chicken Liver-Based Drug Filler Supplemented with Itraconazole

Treatment groups	Group 1 (negative control)	Group 2 (5 g/kg body weight)	Group 3 (10 g/kg body weight)	Group 4 (15 g/kg body weight)	Group 5 (20 g/kg body weight)
Hematological parameters					
RBC ($10^6/\mu\text{L}$)	7.57 ± 0.55 ^a	8.44 ± 0.56 ^a	8.79 ± 0.15 ^a	7.99 ± 0.85 ^a	8.21 ± 0.54 ^a
Hb (g/dL)	12.03 ± 0.31 ^a	13.03 ± 1.21 ^a	11.86 ± 0.53 ^a	11.44 ± 0.76 ^a	12.81 ± 0.82 ^a
Hct (%)	37.53 ± 2.11 ^a	39.48 ± 2.35 ^a	40.64 ± 3.22 ^a	39.39 ± 1.23 ^a	36.43 ± 2.88 ^a
MCV (fL)	50.54 ± 2.82 ^a	49.87 ± 0.95 ^a	50.40 ± 0.33 ^a	49.13 ± 1.15 ^a	50.30 ± 0.87 ^a
MCH (pg)	17.34 ± 0.42 ^a	16.72 ± 0.74 ^a	15.97 ± 1.45 ^a	17.10 ± 0.35 ^a	16.80 ± 0.95 ^a
MCHC (g/dL)	31.9 ± 1.07 ^a	30.73 ± 1.53 ^a	31.40 ± 0.45 ^a	31.09 ± 1.65 ^a	32.61 ± 0.49 ^a
RDW (%)	15.32 ± 0.48 ^a	16.00 ± 0.85 ^a	15.10 ± 0.78 ^a	16.50 ± 1.39 ^a	16.00 ± 0.72 ^a
PLT ($10^3/\mu\text{L}$)	1063.13 ± 21.35 ^a	1065.33 ± 18.35 ^a	1079.67 ± 16.45 ^a	1070.70 ± 19.88 ^a	1071.67 ± 16.56 ^a
MPV (fL)	4.81 ± 1.30 ^a	5.03 ± 0.93 ^a	4.79 ± 0.65 ^a	4.93 ± 1.05 ^a	4.90 ± 1.55 ^a
PDW (%)	17.02 ± 0.22 ^a	16.70 ± 0.85 ^a	16.63 ± 0.88 ^a	17.13 ± 0.22 ^a	16.60 ± 0.85 ^a
PCT (%)	0.27 ± 0.12 ^a	0.21 ± 0.15 ^a	0.24 ± 0.05 ^a	0.32 ± 0.25 ^a	0.24 ± 0.11 ^a
WBC ($10^3/\mu\text{L}$)	5.35 ± 1.02 ^a	5.23 ± 0.55 ^a	6.13 ± 1.02 ^a	5.73 ± 0.66 ^a	5.70 ± 0.78 ^a
Lymphocyte ($10^3/\mu\text{L}$)	4.23 ± 0.34 ^a	4.08 ± 0.50 ^a	4.67 ± 0.51 ^a	3.93 ± 0.65 ^a	4.1 ± 0.31 ^a
Monocyte ($10^3/\mu\text{L}$)	0.25 ± 0.01 ^a	0.24 ± 0.05 ^a	0.23 ± 0.04 ^a	0.27 ± 0.08 ^a	0.23 ± 0.02 ^a
Granulocyte ($10^3/\mu\text{L}$)	1.50 ± 0.03 ^a	1.57 ± 0.07 ^a	1.54 ± 0.15 ^a	1.6 ± 0.23 ^a	1.56 ± 0.76 ^a
Lymphocyte (%)	71.42 ± 3.22 ^a	72.33 ± 2.24 ^a	71.30 ± 3.02 ^a	72.53 ± 3.25 ^a	73.40 ± 3.12 ^a
Monocyte (%)	2.09 ± 1.16 ^a	2.23 ± 0.98 ^a	2.10 ± 1.03 ^a	2.06 ± 0.22 ^a	2.31 ± 0.05 ^a
Granulocyte (%)	43.30 ± 2.16 ^a	40.43 ± 4.45 ^a	43.38 ± 3.12 ^a	42.87 ± 2.34 ^a	41.77 ± 1.78 ^a

Note: Different superscript letters in same row indicate significant differences ($p < 0.05$). Group 1: Control negative; Group 2 (5 g/kg body weight); Group 3 (10 g/kg body weight); Group 4 (15 g/kg body weight); Group 5 (20 g/kg body weight); RBC: Red blood cell; Hb: Hemoglobin; Hct: Hematocrit; MCV: Mean corpuscular volume; MCH: Mean corpuscular hemoglobin; MCHC: Mean corpuscular hemoglobin concentration; RDW: Red cell distribution width; PLT: Platelet; MPV: Mean platelet volume; PDW: Platelet distribution width; PCT: Plateletcrit; WBC: White blood cell

CONCLUSION

An acute toxicity test on chicken liver paste supplemented with itraconazole did not show any mortality or abnormal clinical signs during the 14 days of observation. Parameters of body temperature, body weight increase, and hematology profile also showed no significant differences. These findings indicated that chicken liver paste supplemented with itraconazole falls into the category of practically nontoxic medications, with an LD50 value greater than 20 g/kg body weight. It is recommended that a long-term toxicity evaluation be conducted to further assess any potential effects and side effects.

DECLARATIONS

Funding

This study received no financial support.

Acknowledgments

We would like to thank all employees and management of the Anatomy, Physiology, and Pharmacology Division, School of Veterinary Medicine and Biomedical Sciences (SVMBS), IPB University, and PT Nutricell Pacific for providing data, information, and assistance for the implementation of this study.

Authors' contributions

Prapatantio Teteg Pringgodigdoyo and Lina Noviyanti Sutardi performed the experiments and data analysis for the chicken liver-based drug formulation. Wasmen Manalu designed and drafted the experimental model and the manuscript. Andriyanto and Aulia Andi Mustika performed the experiments and data analysis for acute toxicity (LD50). The manuscript was read and approved by all authors.

Competing interests

The authors declare that there are no conflicts of interest.

Ethical considerations

This paper was originally written by the authors and has not been published elsewhere. The authors checked the text of the article for plagiarism index and confirmed that the text of the article is written based on their original scientific results.

Availability of data and materials

The data supporting the findings of this study are available upon reasonable request from the corresponding author.

REFERENCES

- Aldrich GC and Koppel K (2015). Pet food palatability evaluation: A review standard assay techniques and interpretation of results with primary focus on limitations. *Animals*, 5: 43-45. DOI: <https://www.doi.org/10.3390/ani5010043>
- Brooks HL, Rushton K, Lovell K, Bee P, Walker L, Grant L, and Rogers A (2018). The power of support from companion animals for people living with mental health problems: a systematic review and narrative synthesis of the evidence. *BMC Psychiatry*, 18(1): 31. DOI: <https://www.doi.org/10.1186/s12888-018-1613-2>
- Badan Pengawas Obat dan Makanan (BPOM) (2014). Peraturan kepala badan pengawas obat dan makanan nomor 7 tahun 2014 tentang pedoman uji toksisitas nonklinik secara *in vivo* [Regulation of the head of the drug and food regulatory agency number 7 of 2014 concerning guidelines for *in vivo* non-clinical toxicity tests]. Peraturan Badan Pengawas Obat dan Makanan Republik Indonesia. Jakarta. Available at: <https://static.buku.kemdikbud.go.id/content/media/pdf/SMK/FRM/BG2/BG-Lampiran-2-3.pdf>
- Cascio MJ and DeLoughery TG (2017). Anemia: Evaluation and diagnostic tests. *Medical Clinics of North America*, 101(2): 263-284. DOI: <https://www.doi.org/10.1016/j.mcna.2016.09.003>
- Ekweremadu CS, Abdelhakim HE, Craig HQ, and Barker SA (2020). Development of evaluation of feline tailored amlodipine besylate mini-tablets using L-lysine as a candidate flavouring agent. *Pharmaceutics*, 12(10): 917. DOI: <https://www.doi.org/10.3390/pharmaceutics12100917>
- Haney SL, Chhonker YS, Varney ML, Talmon G, Smith LM, Murry DJ, and Holstein SA (2019). *In vivo* evaluation of isoprenoid triazole bisphosphonate inhibitors of geranylgeranyl diphosphate synthase: Impact of olefin stereochemistry on toxicity and biodistribution. *Journal of Pharmacology and Experimental Therapeutics*, 371(2): 327-338. DOI: <https://www.doi.org/10.1124/jpet.119.258624>
- Lepkov S, Gavrilina N, Borisovskaya S, Savkina K, Ivashenko R, Manuylova O, Zaharov O, Chernova N, Blagova M, Pozharskiy E et al. (2023). PB2030: Hyperchromic anemia as the first manifestation of myeloproliferative disease. *Hemasphere*, 7 (3Suppl): e51819ee. DOI: <https://www.doi.org/10.1097/01.HS9.0000974928.51819.ee>
- Jalongo MR (2021). Pet keeping in the time of COVID-19: The canine and feline companions of young children. *Early Childhood Education Journal*, 51: 1067-1077. DOI: <https://www.doi.org/10.1007/s10643-021-01251-9>
- Joosten P, Ceccarelli D, Odent E, Sarrazin S, Graveland H, Van Gompel L, Battisti A, Caprioli A, Franco A, Wagenaar JA et al. (2020). Antimicrobial usage and resistance in companion animals: A cross-sectional study in three European countries. *Antibiotics*, 9(2): 87. DOI: <https://www.doi.org/10.3390/antibiotics9020087>
- Jusuf EA, Mustika AA, and Andriyanto A (2023). Immunostimulatory activity of avocado oil in mice (*Mus musculus*). *Current Biomedicine*, 1(2): 95-102. DOI: <https://www.doi.org/10.29244/currbiomed.1.2.95-102>
- Mozafari N, Talaie H, Shoaie SD, Hashemian M, and Mahdavinjad A (2016). Survey on hypothermia and hyperthermia in poisoned patients in a Unique Referral Hospital, Tehran, Iran. *Iranian Red Crescent Medical Journal*, 18(4): e35483. DOI: <https://www.doi.org/10.5812/ircmj.35483>
- National center for biotechnology information (NCBI) (2024). PubChem compound summary for CID 55283, itraconazole. Available at: <https://pubchem.ncbi.nlm.nih.gov/compound/Itraconazole>
- Niyomchan A, Chatgat W, Chatawatee B, Keereekoch T, Issuriya A, Jaisamut P, Chusri S, and Kunworarath N (2023). Safety evaluation of the polyherbal formulation NawaTab: acute and subacute oral toxicity studies in rats. *Evidence Based Complementary Alternative Medicine*, 2024: 9413458. DOI: <https://www.doi.org/10.1155/2023/9413458>
- Nurfaat DL (2016). Uji toksisitas akut ekstrak etanol benalu manga (*Dendrophthoe petandra*) terhadap mencit Swiss Webster [Acute toxicity test of ethanol extract of manga mistletoe (*Dendrophthoe petandra*) on Swiss Webster mice]. *Indonesian Journal of Pharmaceutical Science and Technology*, 3(2): 53-65. Available at: <https://jurnal.unpad.ac.id/ijpst/article/view/7941>
- Petry G, Fourie J, and Wolken S (2014). Comparison of the palatability of a new flavoured drontal Plus tablet (Drontal plus treat 10 kg) and Milbemax chewable tablets when presented to privately owned dogs. *Open Journal of Veterinary Medicine*, 4: 163-169. DOI: <https://www.doi.org/10.4236/ojvm.2014.48018>
- Pinto CFD, Bortolo M, Marx FR, and Trevizan L (2021). Characterisation of spray dried hydrolysed chicken liver powder: Effects on palatability and digestibility when included as single source of animal protein in dog diets. *Italian Journal of Animal Science*, 20: 2086-2094. DOI: <https://www.doi.org/10.1080/1828051x.2021.1993091>
- Ribeiro FM, Correia PMM, Santos AC, and Veloso JFCA (2012). A guideline proposal for mice preparation and care in F-FDG PET imaging. *EJNMMI Research*, 12: 49. DOI: <https://www.doi.org/10.1186/s13550-022-00921-y>
- Silva T, Bolzan TCA, Zanini MS, Alencar T, Rodrigues WD, Bastos KA, Severi JA, Resende JA, and Villanova JCO (2020). Development and evaluation of a novel oral mucoadhesive ointment containing pomegranate peel extract as an adjuvant for oral hygiene of dogs. *Journal of Veterinary Dentistry*, 37(3): 133-140. DOI: <https://www.doi.org/10.1177/0898756420973470>
- Sivén M, Savolainen S, Rântilä S, Männikkö, Vainionpää M, Airaksinen S, Raekallio M, Vainio O, and Juppo AM (2017). Difficulties in administration of oral medication formulations to pet cats: An e-survey of cat owners. *Veterinary Record*, 180(10): 250. DOI: <https://www.doi.org/10.1136/vr.103991>
- Stillman AE (1990). Jaundice. In: H. K. Walker, W. D. Hall, and J. W. Hurst (Editors), *Clinical methods: The history, physical, and laboratory examinations*, 3rd Edition. Butterworths., Boston, Chapter 87. Available at: <https://www.ncbi.nlm.nih.gov/books/NBK413/>
- Suchodolski JS (2024). A new journal focusing on companion animals – A welcome message from the editor-in-chief. *Pets*, 1(1): 1-2. DOI: <https://www.doi.org/10.3390/pets1010001>
- Taylor S, Caney S, Bessant C, and Gunn-Moore D (2022). Online survey of owners' experiences of medicating their cats at home. *Journal of Feline Medicine and Surgery*, 24(12): 1283-1293. DOI: <https://www.doi.org/10.1177/1098612X221083752>
- Thakare JG, Pandey C, Mahapatra MM, and Mulik RS (2019). An assessment for mechanical and microstructure behavior of

- dissimilar material welded joint between nuclear grade martensitic P91 and austenitic Ss304 L steel. Journal of Manufacturing Process, 48: 249-259. DOI: <https://www.doi.org/10.1177/1098612X221083752>
- U. S. department of agriculture (2019). Chicken, liver, all classes, cooked, simmered. Food data central food details. SR Legacy, NO. 5028. Available at: <https://fdc.nal.usda.gov/fdc-app.html#/food-details/171061/nutrients>
- Watson PE, Thomas DG, Bermingham EN, Schreurs NM, and Parker ME (2023). Drivers of palatability for cats and dogs – what it means for pet food development. Animals, 13(7): 1134. DOI: <https://www.doi.org/10.3390/ani13071134>
- World Health Organization (WHO) (2001). Iron deficiency anaemia: Assesment, prevention and control: A guide for programme managers. World Health Organization. Available at: <https://www.who.int/publications/m/item/iron-children-6to23--archived-iron-deficiency-anaemia-assessment-prevention-and-control>
- Zahmati M and Saljooghi AS (2016). The evaluation of deferasirox on hematological parameters after lead administration. Asian Pacific Journal of Medical Toxicology, 5: 124-129. DOI: <https://www.doi.org/10.22038/apjmt.2016.8139>

Publisher's note: Scienceline Publication Ltd. remains neutral with regard to jurisdictional claims in published maps and institutional affiliations.



Open Access: This article is licensed under a Creative Commons Attribution 4.0 International License, which permits use, sharing, adaptation, distribution and reproduction in any medium or format, as long as you give appropriate credit to the original author(s) and the source, provide a link to the Creative Commons licence, and indicate if changes were made. The images or other third party material in this article are included in the article's Creative Commons licence, unless indicated otherwise in a credit line to the material. If material is not included in the article's Creative Commons licence and your intended use is not permitted by statutory regulation or exceeds the permitted use, you will need to obtain permission directly from the copyright holder. To view a copy of this licence, visit <https://creativecommons.org/licenses/by/4.0/>.