



# Sebaceous Adenitis in an Akita: Symptoms and Therapeutic Approaches

Mykola Zhelavskiy<sup>1\*</sup> , Mykola Maryniuk<sup>2</sup> , and Maryna Drobot<sup>2</sup> 

<sup>1</sup>Vinnitsia National Agrarian University, Sonyachna Str., 3, Vinnitsia, 21008, Ukraine

<sup>2</sup>National University of Life and Environmental Sciences of Ukraine, Heroiv Oborony Str., 15, Kyiv, 03041, Ukraine

\*Corresponding author's Email: nicoladoctor@gmail.com

## ABSTRACT

Sebaceous adenitis is observed in different animal species, with dogs being the most commonly diagnosed. This study aimed to report a case of sebaceous adenitis in a 5-year-old male Akita dog weighing 35.8 kg, initially presented with pruritus and alopecia on the inner ear surfaces, face, and head. Over time, signs of changes in sebaceous glands appeared in other body parts. The dog was sent to a veterinary clinic in Kamyanets-Podilsky, Ukraine. During the clinical examination, the body temperature was 38.4°C, heart rate 78 bpm, and a respiratory rate 27 breaths per minute, with no change in appetite. Clinical and dermatological methods and histopathological examination were used to detect the disease. The hair on the head was curling, and the lesions appeared on the dorsal tail, the distal front and hind legs, the groin, and the abdomen. Initially, redness and itching occurred in the affected areas, and the skin lost elasticity and became dry. The hair was stuck together with gray crusts. The diagnosis was confirmed based on pathohistological studies. An inflammatory infiltrate with migration of lymphocytes, histiocytes, neutrophils, and atrophy of sebaceous glands was diagnosed, focusing on the pathology of the dermis. Treatment included topical therapy with shampoo applied for 3-5 minutes, then rinsed and followed by Conditioner for 2 minutes, over 30 days. Omega-3 was administered orally at 1000 mg twice daily. Isotretinoin (Roaccutane<sup>®</sup>, 20 mg) was administered orally twice daily for 30 days. Moreover, Cyclosporine was dosed at 5 mg/kg once daily orally, on an empty stomach, for 30 days. During the treatment, signs of inflammation gradually disappeared, with itching and hyperemia disappearing from day 3. From day 7, desquamation and hair loss decreased, and on day 12, signs of new hair growth appeared. The areas were completely restored on day 28 of treatment. Sebaceous adenitis was found to lead to the destruction of sebaceous glands, causing scaling, hair loss, and skin inflammation, which could be a hereditary condition in Akitas. Immunomodulation and normalization of trophic processes in the skin are crucial in the treatment.

**Keywords:** Akita, Diagnosis, Dog, Sebaceous Adenitis, Treatment

## INTRODUCTION

Sebaceous adenitis is defined as inflammation of the skin glands characterized by degenerative changes and their atrophy. Sebaceous adenitis is observed in various animal species, though it is most frequently diagnosed in dogs. Sebaceous glands play an important physiological role in dogs and provide protective mechanisms for the body's natural defense and maintaining homeostasis. These glands also play a vital role in dogs in maintaining the health of the skin and coat by secreting sebum, an oily substance that provides moisture and protection. Sebum forms a barrier that prevents moisture loss, reduces the risk of microbial infections, and enhances skin elasticity. Moreover, sebaceous glands play a crucial role in sustaining the natural equilibrium of the skin's microbiome (Abbas et al., 2021; Harris et al., 2022; Anderson et al., 2023).

Skin glands secrete sebum, an oily substance that moisturizes the skin and hair, ensuring their flexibility (Wang et al., 2022; Older et al., 2023). Located primarily near the hair follicles, their activity is regulated by hormones and other physiological factors. Neutered or spayed dogs may experience changes in sebaceous gland activity, which can affect the condition of their skin and coat (Lee et al., 2020; Older et al., 2021; Outerbridge and Jordan, 2021). Sebum forms a protective barrier on the skin's surface, helping to prevent the entry of bacteria, fungi, and other pathogens (Zhelavskiy et al., 2023a).

Since dogs spend a lot of time outdoors, with their skin exposed to various environmental factors, the protective function of sebum is particularly significant. Sebaceous glands are situated in the dermis, typically at the upper part of hair follicles (Cugmas and Olivry, 2020). Sebaceous glands are distributed throughout the dog's body, with the highest concentration found in areas with dense hair, such as the back, neck, and tail.

CASE REPORT  
Received: September 22, 2024  
Revised: October 30, 2024  
Accepted: November 24, 2024  
Published: December 30, 2024

Diet plays a key role in preventing and controlling sebaceous adenitis in dogs, as proper nutrition supports skin and coat health. A diet rich in omega-3 and omega-6 fatty acids reduces inflammation and improves the skin barrier (Olivry et al., 2020). Sebaceous adenitis in dogs can be triggered by foods containing allergens or inadequately balanced nutrients. Products high in artificial additives, preservatives, or low-quality protein sources can negatively impact skin health and cause inflammation of the sebaceous glands (Outerbridge and Jordan, 2021).

Previous studies have shown that sebaceous adenitis is influenced by genetic factors, breed predisposition, and autoimmune mechanisms (Hayashi et al., 2021; Patel et al., 2021; Zhelavskiy et al., 2023b). Key mechanisms in the pathophysiology of sebaceous adenitis are attributed to immune defense mechanisms. The immune system mistakenly attacks sebaceous gland cells, which leads to inflammation and their gradual destruction. Lymphocytes, histiocytes, and other inflammatory cells surround the affected sebaceous glands (Hayashi et al., 2021). This causes chronic inflammation and gradual atrophy of the glands. Excessive keratin formation in the epidermis can lead to scales and crusts on the skin (Tomotake et al., 2021). Immune mechanisms are central to the development of sebaceous adenitis in dogs, which is regarded as an autoimmune condition. The immune system mistakenly targets and destroys the sebaceous glands, resulting in their dysfunction. T lymphocytes, particularly CD8+ cytotoxic T cells, play a significant role in the destruction of sebaceous glands by triggering an immune response to specific antigens within the glands or their products. They recognize antigens on the surface of sebaceous gland cells and initiate an autoimmune response (Sartori and Peruccio, 2020). Sebaceous glands are surrounded by inflammatory cells, including lymphocytes, histiocytes, and neutrophils. Immune cells release proinflammatory cytokines (Patel et al., 2021), including interleukins (IL-1, IL-6) and tumor necrosis factor-alpha (TNF- $\alpha$ ), which amplify the inflammatory response (Jolly et al., 2023). Some cells, such as macrophages and cytotoxic T lymphocytes, directly attack sebaceous gland cells and destroy them.

The first step in diagnosing sebaceous adenitis involves taking a detailed clinical history and observing the dog's symptoms. Sebaceous adenitis typically manifests as hair loss (alopecia), scaling, dull or brittle hair, and, in some cases, secondary bacterial infections. Akitas, for instance, may develop severe generalized scaling and thickened skin. A veterinarian will typically begin by conducting a broad clinical examination to rule out other dermatological conditions such as hypothyroidism, allergies, or fungal infections (Sharkey et al., 2020).

The age of onset and breed predisposition are important clues. Sebaceous adenitis commonly affects dogs in their young adult years, and certain breeds, such as Akitas and Standard Poodles, are genetically predisposed. A thorough clinical history, including any familial history of skin disorders, can help narrow down the diagnosis (Brown et al., 2023). A detailed dermatological examination is crucial for identifying characteristic skin changes, such as patchy hair loss, excessive scaling, and follicular casts (which are accumulations of keratin around hair shafts). Follicular cysts are one of the hallmark signs of sebaceous adenitis, particularly in Standard Poodles. This physical examination helps the veterinarian determine whether sebaceous adenitis is a likely diagnosis or if further testing is necessary (Olivry et al., 2020).

Trichography, or microscopic examination of hair samples, can be used as a non-invasive method to evaluate hair follicle health. In sebaceous adenitis, the hair may show signs of brittleness, breakage, and other abnormalities due to the lack of sebum. Follicular casts around the hair shafts can also be observed under a microscope, which is a significant indicator of sebaceous adenitis. While this method is useful for initial suspicion, it is not conclusive and usually needs to be combined with more specific tests like skin biopsies (Cugmas and Olivry, 2020).

Cytology involves taking samples of the skin surface (e.g., through skin scrapings or impression smears) and examining them under a microscope to detect signs of inflammation or secondary infections (Thompson et al., 2023). In cases of sebaceous adenitis, cytology might reveal inflammatory cells like lymphocytes and macrophages, but these findings are not unique to the disease (Diaz, 2021; Sharkey et al., 2020).

A definitive diagnostic tool for sebaceous adenitis is a 'skin biopsy' followed by histopathological examination. A biopsy involves taking small samples of the affected skin, usually from multiple sites, to ensure that representative areas are analyzed (Brown et al., 2023). In the early stages of sebaceous adenitis, histopathology will typically reveal "granulomatous or pyogranulomatous inflammation" targeting the sebaceous glands, along with the destruction or absence of these glands. As the disease progresses, sebaceous glands may completely disappear, and the skin may develop hyperkeratosis, i.e., the thickened outer layer of the skin (Sharkey et al., 2020).

Histopathology is critical for differentiating sebaceous adenitis from other skin disorders that might present with similar symptoms, such as demodicosis or certain autoimmune diseases. Importantly, this test can confirm the diagnosis with a high degree of accuracy, making it the gold standard for diagnosing sebaceous adenitis (Reichler et al., 2001). In certain cases, advanced diagnostic imaging techniques, such as "dermoscopy" or "confocal microscopy" may be used to provide further insight into the structure of the skin and hair follicles. These imaging methods allow for non-invasive or minimally invasive visualization of the skin, helping to identify abnormalities in the sebaceous glands or hair follicles

(Forbes et al., 2024). While not commonly used in routine veterinary practice, these tools can be helpful in research settings or in complicated cases where a biopsy may be inconclusive or too invasive for the patient.

Immunohistochemistry is a more specialized diagnostic method that involves staining biopsy samples with antibodies to identify specific immune cells or proteins involved in the disease process (Tomotake et al., 2023; Zhelavskiy et al., 2024). This method is particularly useful in distinguishing sebaceous adenitis from autoimmune skin disorders that may present with similar histopathological findings. While not always necessary for routine diagnosis, immunohistochemistry can provide valuable additional information in complex or atypical cases (Abbas et al., 2021).

While molecular testing is not yet widely available for routine clinical diagnosis, ongoing research is exploring the genetic basis of sebaceous adenitis in dogs. In the future, genetic testing may become an important diagnostic tool, allowing for earlier detection and better management of dogs predisposed to the condition (Sharkey et al., 2020).

Although sebaceous adenitis is not primarily an allergic condition, dogs with the disease may develop secondary allergies or sensitivities due to the impaired skin barrier. In some cases, veterinarians may perform allergy testing or conduct food elimination trials to rule out concurrent allergic dermatitis. While these tests do not directly diagnose sebaceous adenitis, they can help manage the overall skin health of the affected dogs (Lee et al., 2020).

These treatments predominantly target the underlying disease mechanisms, focusing on the enhancement of the trophic processes in the skin. In addition to antibiotics, veterinarians also prescribe immunosuppression (Palmeiro, 2013; Tomotake et al., 2021; Zhelavskiy et al., 2023a). Treatment often needs to be tailored individually for each patient.

The differential diagnosis of sebaceous adenitis in dogs includes conditions, such as hypothyroidism, demodicosis, and autoimmune skin diseases like pemphigus foliaceus (Reichler et al., 2001). Hypothyroidism can lead to similar hair loss and skin changes but is usually accompanied by systemic signs (Diaz, 2021). Demodicosis, caused by mites, can mimic sebaceous adenitis with hair loss and scaling but typically involves other diagnostic findings like mite presence. Autoimmune diseases, such as pemphigus, often present with pustules and erosions, which are less common in sebaceous adenitis (Abbas et al., 2021).

Treatment of sebaceous adenitis in dogs is often complex and requires a long-term and comprehensive approach. There are many factors to consider when treating this disease, including sebaceous adenitis. Sebaceous adenitis is often chronic, requiring long-term treatment and constant monitoring. The disease may periodically worsen, which requires adjustment of therapy. Certain medications, such as cyclosporine or corticosteroids, may not always be effective for all dogs. In addition, long-term use of these drugs can lead to side effects. Even with successful treatment, recurrences of sebaceous adenitis are frequent. Consequently, therapy must be monitored and corrected constantly (Olivry et al., 2020). The present study aimed to report a case of sebaceous adenitis in an Akita dog with a description of the methods employed for diagnosis and treatment.

## CASE REPORT

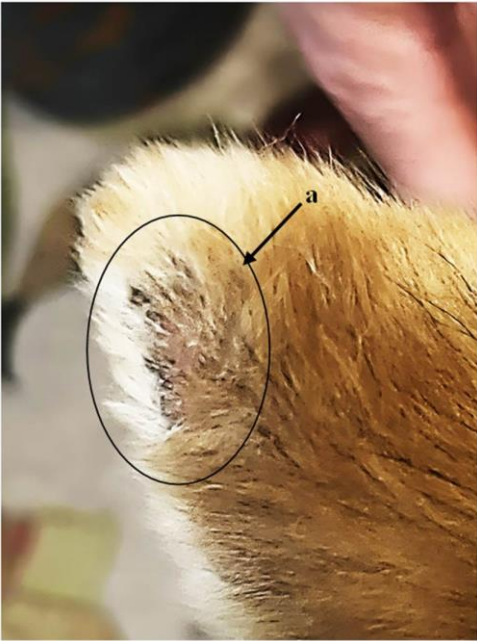### Clinical signs

A 5-year-old male Akita weighing 35.8 kg was presented for pruritus and alopecia on the inner surface of the ears, face, and head and was sent to a veterinary clinic (21 April 2024) located in Kamyanyets-Podilsky, Ukraine. During the clinical examination, the body temperature was recorded at 38.4 °C, the heart rate at 78 bpm, and the respiratory rate at 27 breaths per minute. The appetite did not change. Over time, changes appeared in other parts of the skin. During the clinical examination, dermatological examinations were performed including trichogram, acetate tape test, skin scraping, mycological examination (luminescent method, inoculation on indicator nutrient media), and parasitological dermatology (Diaz, 2021). The results did not reveal any change in the characteristics of infections. Verification of the diagnosis (sebaceous adenitis) was based on histopathological examination (Diaz, 2021).

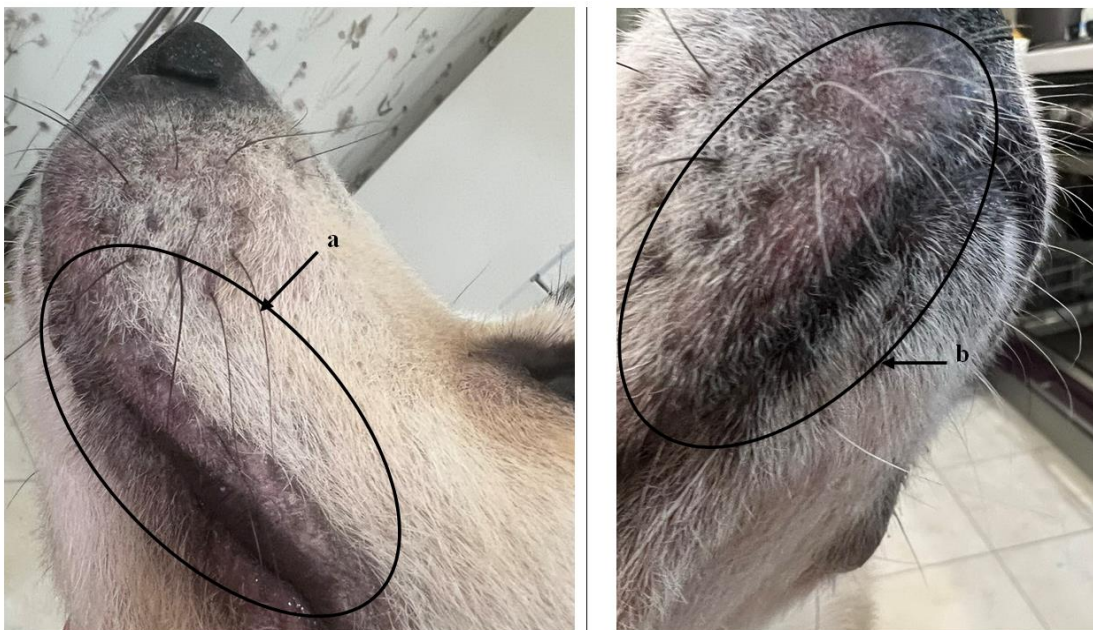
The first signs were the erythema of the skin on the ears (Figure 1) and on the snout (Figure 2). The hair on the head was becoming curly (Figure 3). The alopecia and clumping of hair were also found on the dorsal part of the tail (Figure 4), the distal part of the front and hind legs, the groin, and the abdomen. At first, redness and itching appeared in the areas. The skin lost elasticity and became dry. The hair was stuck together with gray crusts. Inflammatory infiltration was accompanied by cellular migration of lymphocytes, histiocytes, and neutrophils (Figure 5).

Changes in the size and structure of hair follicles with signs of hyperkeratosis, cysts, and atrophy of sebaceous glands were diagnosed. During the treatment, the gradual disappearance of inflammation signs was well noted. Starting from the third day, itching and hyperemia disappeared. From day 7, desquamation and hair loss decreased. On day 12, signs of new hair growth appeared. The areas were completely restored on day 28 of the treatment.

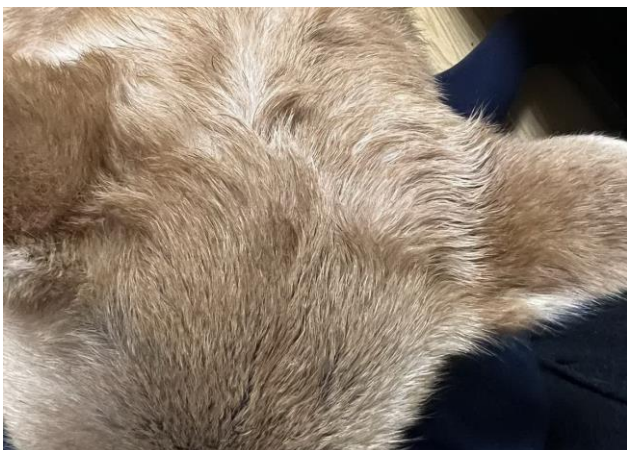



**Figure 1.** Sebaceous adenitis in the left ear of a 5-year-old, Akita male dog. **a:** visualization of alopecia.

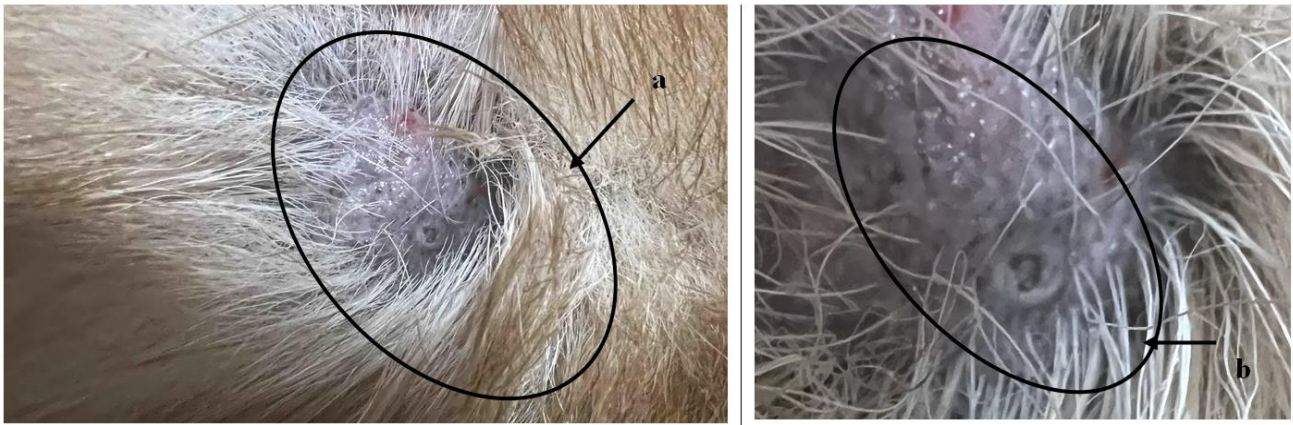


**Figure 2.** Clinical characteristics of sebaceous adenitis of a 5-year-old, Akita male dog (on the snout). **a:** Visualization of hair loss around the lips, **b:** Redness of the skin and gluing of hair.

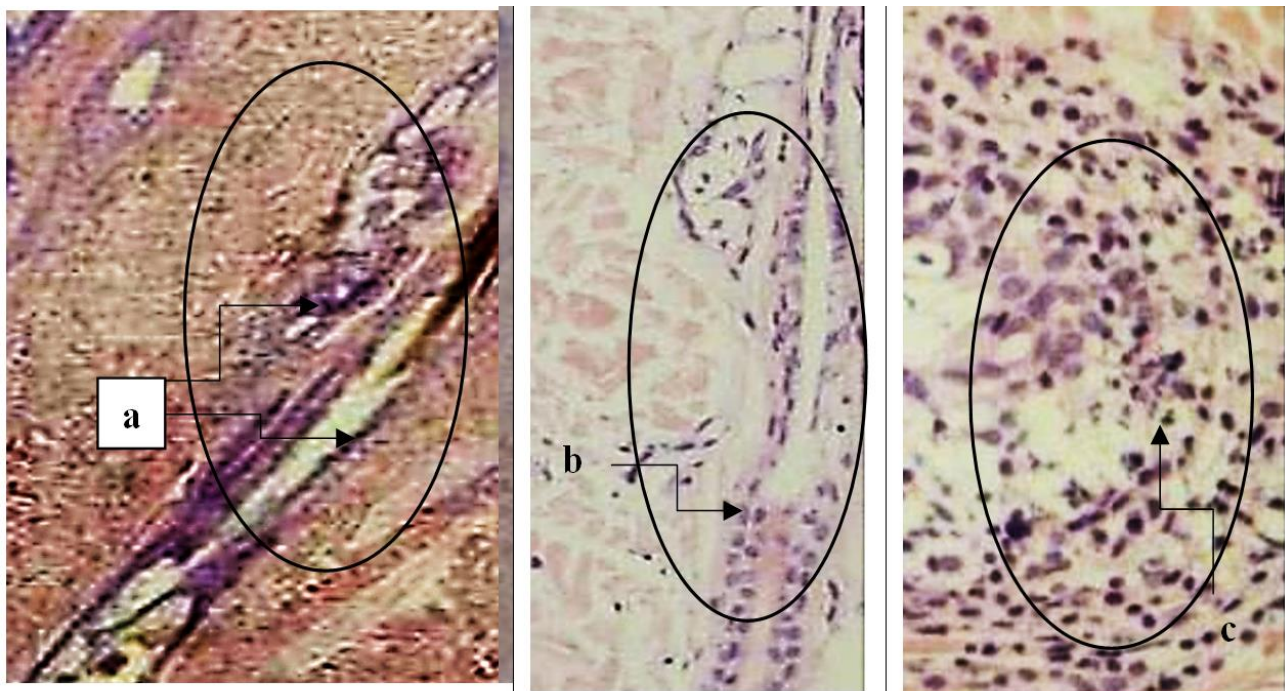


**Figure 3.** Sebaceous adenitis of a 5-year-old, Akita male dog. Clinical signs: Curling hair is visible on the head.





**Figure 4.** Sebaceous adenitis in a 5-year-old, Akita male dog (on the dorsal part of the tail). **a:** Alopecia and glued hair are visible, **b:** Accumulation of sticky exudate and damage to the epidermis (magnification x4).



**Figure 5.** Sebaceous adenitis in a 5-year-old, Akita male dog. **a:** Visualization of reactive inflammation of sebaceous glands (magnification x800), **b:** Cellular infiltration phagocytes and destruction of sebaceous glands, **c:** Reactive phagocytes and lymphocytes (magnification x3000), stained with H and E.

#### Sample selection and drug preparation

A laboratory test was performed in the clinic and a biopsy location was determined. A marker MEANT (Mini Traditional Gentian Violet Ink Surgical Marker, Viscot Medical LLC, USA) was used to mark the place of biopsy selection. For local anesthesia, 2% lidocaine hydrochloride (lidocaine, B. Braun Medical, UK) was used. The area was cleaned with 70° ethyl alcohol (Emsure®, Sigma-Aldrich, Germany). A skin sample (epidermis, dermis, hypodermis) was taken with a biopsy needle (Diaz, 2021). The biopsies were placed in a container with a 10% aqueous solution of formaldehyde (Sigma-Aldrich, Germany), marked, and sent to the laboratory (Kamyanets-Podilsky, Ukraine). A sterile dressing was applied to the biopsy. The skin biopsy was fixed in 10% formaldehyde (Sigma-Aldrich, Germany) for at least 24-48 hours. Next, the preparations were prepared according to the protocol (Diaz, 2021) for staining with hematoxylin and eosin (H and E, Sigma-Aldrich, Germany).

#### Treatment

The treatment involved the use of shampoo (8 in 1 Natural Oatmeal, USA), which was applied to the wool and gently treated for 3-5 minutes on the affected skin areas. After that, the shampoo was washed off with clean water and thoroughly wiped with a towel. After treatment with shampoo, Conditioner (8 in1 Hypoallergenic Conditioner, USA) was applied to lesions for 2 minutes. Afterward, it was thoroughly washed with clean water and dried with a towel. This treatment course lasted for 30 days. Omega-3 (Omega-3 for Dogs/Cat, Now Foods, USA) was administered orally in a

dose of 1 capsule (1000 mg, containing 180 mg of eicosatrienic acid, 120 mg of docosapentaenoic acid), twice a day with an interval of 12 hours, in the course of 30 days (Diaz, 2021). Isotretinoin (stereoisomer of trans-retinoic acid (tretinoin, Roaccutane<sup>®</sup>, F. Hoffmann-La Roche Ltd., Switzerland) was also administered orally. The drug was prescribed in a dose of 1 capsule (20 mg) twice a day. The course of treatment was 30 days (Pye, 2021). Cyclosporine (Atopica<sup>®</sup>, Novartis, UK) was administered orally at 5.0 mg/kg once daily (over 30 days), on an empty stomach, 2 hours after a meal (Palmeiro, 2013).

## DISCUSSION

Sebaceous adenitis is a rare disease among dermatological diseases of animals. The disease was first described in a poodle dog in 1987. Subsequently, sebaceous adenitis was diagnosed in cats, rabbits, horses, and humans (Reichler *et al.*, 2001; Olivry *et al.*, 2020; Forbes *et al.*, 2024). Sebaceous gland disease is infrequently observed in cats, typically manifesting as chronic and progressive dermatologic issues. These include non-itchy scaling, crusting, hair loss, and localized skin depigmentation (Sartori and Peruccio, 2020; Thompson *et al.*, 2021; Gonzalez *et al.*, 2023). In dogs, the breeds at higher risk include Poodles, Akitas, Hungarian Sheepdogs, Samoyeds, and Springer Spaniels (Brown *et al.*, 2023). Parasitic infections, dermatomycoses, allergies, autoimmune processes, and metabolic disorders are taken into account during differentiation (Denti *et al.*, 2022; Jolly *et al.*, 2023). In the clinical case, the main lesions were localized on the inner and outer surfaces of the auricle of the left and right ears. The lesions were localized on the dorsal part of the tail. The patient had itching, alopecia was formed on the affected areas, and hair was sticking together, which formed gray crusts. Similar signs have been described in previous studies (Reichler *et al.*, 2001; Olivry *et al.*, 2020).

In the Akita, the disease may have a genetic determination (Reichler *et al.*, 2001; Olivry *et al.*, 2020; Pye, 2021). Additionally, climatic factors should be considered as well. In this case, the patient's main sebadenitis lesions were on the ears, the dorsal part of the tail, and the distal parts of the forelimbs. Clinical signs were consistent with those observed in other dog breeds, including hypotrichosis, alopecia, follicular casts, comedones, scaling, and bilateral otitis externa. Pruritus ranged from moderate to severe, likely linked to skin and coat dryness (xerosis).

The diagnosis was based on dermatological signs and confirmed by biopsy and histopathology. For treatment, the drugs were used with a pathogenetic and etiotropic direction. The treatment consisted of normalizing the animal's trophic processes and modulating its immune response. Using specialized shampoos offers several key benefits in managing sebaceous adenitis in dogs. Natural ingredients, including oatmeal and aloe vera, help soothe and moisturize irritated skin, reducing inflammation and dryness. Massaging the shampoo into the dog's coat for 3-5 minutes not only ensures even application but also promotes circulation, aiding in skin healing. After thoroughly rinsing the shampoo, applying a hypoallergenic conditioner further enhances the treatment by moisturizing both skin and fur, reducing irritation, and improving overall coat texture. Recent formulations of conditioners may also include essential fatty acids, which help restore the lipid barrier of the skin, providing long-term benefits in managing dryness and irritation associated with sebaceous adenitis (Reichler *et al.*, 2001).

Omega-3 fatty acids in a dog's diet can be a valuable additive to the overall treatment plan for sebaceous adenitis. Fatty acids, including eicosapentaenoic acid (EPA) and docosahexaenoic acid (DHA), help reduce inflammation by suppressing the production of pro-inflammatory cytokines and other inflammatory mediators.

Additionally, omega-3 fatty acids help retain moisture in the skin, reducing dryness and flakiness that often accompany sebaceous adenitis. It has been shown that omega-3 fatty acids affect immunomodulatory, helping to balance the immune response and reduce autoimmune reactions, which may cause or contribute to the development of sebaceous adenitis. Isotretinoin stimulates skin cell renewal, which aids in the regeneration of damaged skin and the restoration of its normal structure. As a result of the medication, keratinization processes are normalized, reducing excess keratin production that can block sebaceous glands and result in crusts and scales on the skin (Cugmas and Olivry, 2020). Isotretinoin dramatically decreases sebaceous gland activity, leading to a reduction in sebum production. This helps to reduce the inflammatory processes associated with blocked sebaceous glands. The applied therapy yielded positive results (Outerbridge and Jordan, 2021; Patel *et al.*, 2021; Pye, 2021).

The effectiveness of cyclosporine has been described in several publications (Palmeiro, 2013; Outerbridge and Jordan, 2021; Jolly *et al.*, 2023). Cyclosporine is an immunosuppressant widely used for the treatment of sebaceous adenitis in dogs. Its action involves suppressing the activity of the immune system, which helps to reduce inflammation and alleviate the symptoms of the disease. Cyclosporine suppresses the activation and proliferation of T lymphocytes, which are crucial cells in the immune response. This reduces the production of pro-inflammatory cytokines, including interleukins and interferons, reducing inflammation in the sebaceous glands (Olivry *et al.*, 2020; Denti *et al.*, 2022; Tomotake *et al.*, 2021). Possible complications have been reported in recent studies (Pye, 2021; Jolly *et al.*, 2023).

## CONCLUSION

Sebaceous adenitis of Akita has a spontaneous nature, often without determining the cause. Treatment is aimed at using the means and methods necessary to restore the functioning of the skin and the sebaceous glands. Further research may focus on studying the immune mechanisms involved in the development of this pathology, which will, in turn, open new avenues for improving diagnosis and treatment. The immune system plays a key role in many diseases, including those associated with autoimmune processes, inflammatory responses, or dysregulation of immune function. Understanding how these mechanisms interact with other systems in the body will allow for the development of more precise diagnostic markers and targeted therapies, leading to more effective and personalized treatments for patients.

## DECLARATIONS

### Funding

This research received no specific grant from any funding agency in the public, commercial, or not-for-profit sectors.

### Availability of data and materials

The datasets generated and/or analyzed during the current study are available from the corresponding author upon reasonable request.

### Acknowledgments

The authors appreciate who helped us to gather the data for this case report.

### Authors' contributions

Mykola Zhelavskiy developed the initial concept, verified the medical history, collected data, and conducted the experiment. Mykola Maryniuk was responsible for designing the study and conducting clinical research. Maryna Drobot carried out laboratory research. Each author played a significant role in critically reviewing and giving final approval to the manuscript, ensuring the integrity and quality of the work. All the authors thoroughly reviewed the content and contributed to refining the final version of the manuscripts. After careful evaluation, they unanimously approved the manuscripts for submission, confirming that the content accurately reflects their research findings, perspectives, and collective input. All authors read and approved the final version of the manuscript.

### Competing interests

The authors declare no competing interests.

### Ethical considerations

The authors addressed all relevant ethical considerations, including but not limited to, ensuring the originality of the work, obtaining publication consent, preventing research misconduct, avoiding data fabrication or falsification, and preventing duplicate publication or redundancy.

## REFERENCES

- Abbas AK, Lichtman AH, and Pillai S (2021). Cellular and molecular immunology, 10<sup>th</sup> Edition. Elsevier Health Sciences., Amsterdam, the Netherlands, pp. 883-953. Available at: <https://shop.elsevier.com/books/cellular-and-molecular-immunology/abbas/978-0-323-75748-5>
- Anderson M, Roberts C, and Smith J (2023). Paraconiothyrium cyclothyrioides, a novel cutaneous fungal pathogen in a dog and a cat. Veterinary Dermatology, 34: 363-366. DOI: <https://www.doi.org/10.1111/vde.13155>
- Brown R, Davis L, and Thompson A (2023). Skin biopsy guidelines: tips and advice from veterinary pathologists to practitioners. Journal of the American Veterinary Medical Association, 261(S1): S114-S121. DOI: <https://www.doi.org/10.2460/javma.22.12.0586>
- Older CE, Hoffmann AR, and Diesel AB (2023). The feline skin microbiome: Interrelationship between health and disease. Journal of Feline Medicine and Surgery, 25(7): 1-9. DOI: <https://www.doi.org/10.1177/1098612X231180231>
- Cugmas B and Olivry T (2020). Evaluation of skin erythema severity by dermatoscopy in dogs with atopic dermatitis. Veterinary Dermatology, 32: 183-e146. DOI: <https://www.doi.org/10.1111/vde.12932>
- Denti D, Caldin M, Ventura L, and De Lucia M (2022). Prolonged twice-daily administration of oclacitinib for the control of canine atopic dermatitis: A retrospective study of 53 client-owned atopic dogs. Veterinary Dermatology, 33: 149-e42. DOI: <https://www.doi.org/10.1111/vde.13053>
- Diaz S (2021). Sebaceous adenitis in dogs and cats, professional version. MSM manual veterinary manual. Available at: <https://www.msdrvmanual.com/ear-disorders/diseases-of-the-pinna/sebaceous-adenitis-in-dogs-and-cats>



- Forbes S, Bettenay S, Meertens NM, Wildermuth BE, Wildermuth K, and Mueller RS (2024). Diascopy and histopathological evaluation of nonblanching erythematous dermatoses in dogs. *Veterinary Dermatology*, 35(3): 255-262. DOI: <https://www.doi.org/10.1111/vde.13230>
- Gonzalez S, Johnson K, and Rivera M (2023). Tolerability and the effect on skin *Staphylococcus pseudintermedius* density of repeated diluted sodium hypochlorite (bleach) baths at 0.005% in healthy dogs. *Veterinary Dermatology*, 34: 489-494. DOI: <https://www.doi.org/10.1111/vde.13186>
- Harris E, Lewis G, and Perez F (2022). *Talaromyces* spp. infections in dogs from the Southern United States. *Veterinary Pathology*, 59: 451-454. DOI: <https://www.doi.org/10.1177/03009858221075589>
- Hayashi M, Yasuno K, and Onuma M (2021). Expression profiling of Toll-like receptors in canine sebaceous adenitis. *Veterinary Dermatology*, 32(1): 58-e12. DOI: <https://www.doi.org/10.1111/vde.12942>
- Jolly JA, Grumstrup-Scott J, and Thomasy SM (2023). Assessment of immune cell infiltrates in canine sebaceous adenitis. *Veterinary Pathology*, 60(1): 54-61. DOI: <https://www.doi.org/10.1177/03009858221068016>
- Lee C, Shin JH, and Park S (2020). Comparative analysis of skin microbiota in dogs with sebaceous adenitis. *Animals*, 10(6): 952. DOI: <https://www.doi.org/10.3390/ani10060952>
- Older CE, Diesel AB, Starks JM, Lawhon SD, and Rodrigues Hoffmann A (2021). Characterization of staphylococcal communities on healthy and allergic feline skin. *Veterinary Dermatology*, 32(1): 61-e10. DOI: <https://www.doi.org/10.1111/vde.12885>
- Olivry T, Linder KE, Paps JS, Bizikova P, and Sousa CA (2020). Sebaceous adenitis in dogs: Advances in understanding and treatment. *Veterinary Dermatology*, 31(1): 1-12. DOI: <https://www.doi.org/10.1111/vde.12784>
- Outerbridge CA and Jordan TJM (2021). Current knowledge on canine atopic dermatitis. *Pathogenesis and Treatment. Advances in Small Animal Care*, 2: 101-115. Available at: <https://www.ncbi.nlm.nih.gov/pmc/articles/PMC9204668/>
- Palmeiro BS (2013). Cyclosporine in veterinary dermatology. *The Veterinary Clinics of North America: Small Animal Practice*, 43(1): 153-171. DOI: <https://www.doi.org/10.1016/j.cvsm.2012.09.007>
- Patel S, Rivera J, and Smith L (2021). Cytokine expression in feline allergic dermatitis and feline asthma. *Veterinary Dermatology*, 32(6): 613-e163. DOI: <https://www.doi.org/10.1111/vde.13022>
- Pye C (2021). Canine sebaceous adenitis. *The Canadian Veterinary Journal*, 62(3): 293-296. Available at: [https://www.ncbi.nlm.nih.gov/pmc/articles/PMC7877684/pdf/cvj\\_03\\_293.pdf](https://www.ncbi.nlm.nih.gov/pmc/articles/PMC7877684/pdf/cvj_03_293.pdf)
- Reichler IM, Hauser B, Schiller I, Dunstan RW, Credille KM, Binder H, Glaus T, and Arnold S (2001). Sebaceous adenitis in the Akita: Clinical observations, histopathology and heredity. *Veterinary Dermatology*, 12(5): 243-53. DOI: <https://www.doi.org/10.1046/j.0959-4493.2001.00251>
- Sartori R and Peruccio C (2020). A case of Sebaceous adenitis and concurrent meibomian gland dysfunction in a dog. *Veterinary Sciences*, 7(2): 37. DOI: <https://www.doi.org/10.3390/vetsci7020037>
- Sharkey LC, Radin MJ, Wellman ML, and Kruger JM (2020). *Veterinary cytology*, 2<sup>nd</sup> Edition. Elsevier., Davis, pp. 1-550. DOI: <https://www.doi.org/10.1002/9781119380559>
- Thompson J, Underwood M, and Vega E (2021). Diagnostic accuracy of a direct panfungal polymerase chain reaction assay performed on stained cytology slides. *Veterinary Pathology*, 58: 542-548. DOI: <https://www.doi.org/10.1177/0300985821991562>
- Tomotake Y, Uchida S, and Oyama T (2021). Immunohistochemical characterization of canine sebaceous adenitis lesions. *Veterinary Pathology*, 58(4): 738-745. DOI: <https://www.doi.org/10.1177/0300985820988560>
- Wang Y, Liu D, and Qian W (2022). RNA-Seq transcriptome analysis of canine sebaceous adenitis skin provides insights into disease pathogenesis. *Genes*, 13(1): 48. DOI: <https://www.doi.org/10.3390/genes13010048>
- Zhelavskiy M, Kernychnyi S, and Betlinska T (2023a). Hematological and biochemical parameters of macropod progressive periodontal disease in wild Western gray kangaroos. *World's Veterinary Journal*, 13(4): 630-635. DOI: <https://www.doi.org/10.54203/scil.2023.wvj68>
- Zhelavskiy MM, Kernychnyi SP, and Betlinska TV (2023b). Effects of hydroxychloroquine and tacrolimus on discoid facial Lupus Erythematosus in a dog. *World's Veterinary Journal*, 13(2): 360-364. DOI: <https://www.doi.org/10.54203/scil.2023.wvj39>
- Zhelavskiy M, Maryniuk M, and Drobot M (2024). The role of neutrophils and NETosis in local immunity of feline inflammatory aural polyps. *World's Veterinary Journal*, 14(1): 137-144. DOI: <https://www.doi.org/10.54203/scil.2024.wvj17>

**Publisher's note:** [Scienceline Publication](#) Ltd. remains neutral with regard to jurisdictional claims in published maps and institutional affiliations.



**Open Access:** This article is licensed under a Creative Commons Attribution 4.0 International License, which permits use, sharing, adaptation, distribution and reproduction in any medium or format, as long as you give appropriate credit to the original author(s) and the source, provide a link to the Creative Commons licence, and indicate if changes were made. The images or other third party material in this article are included in the article's Creative Commons licence, unless indicated otherwise in a credit line to the material. If material is not included in the article's Creative Commons licence and your intended use is not permitted by statutory regulation or exceeds the permitted use, you will need to obtain permission directly from the copyright holder. To view a copy of this licence, visit <https://creativecommons.org/licenses/by/4.0/>.