



Effect of Vitamin E on the Prevention of Peritoneal Adhesions in Sheep

Luisa Pucci Bueno Borges¹, Ewaldo de Mattos-Junior², Marco Augusto Machado Silva³, Maria Augusta Adami Pereira dos Santos², Débora Oliveira Garcia², Ilan Munhoz Ayer², Felipe Farias Pereira da Câmara Barros⁴ and Pedro Paulo Maia Teixeira¹

¹ Pará Federal University, Veterinary Institute (BR 316, km 62, PO Box 68743-970, Castanhal, Pará), Brazil

² Veterinary Science Post Graduation, Franca University, Franca (Armando Salles Oliveira street, 201- Parque Universitário, PO Box 14404-600, Franca, São Paulo), Brazil

³ Goiás Federal University, UFG, Chácaras de Recreio Samambaia (Esperança Street, UFG, PO Box 74690-900, Jataí, Goiás), Brazil

⁴ Rio de Janeiro Rural Federal University, Veterinary Surgery and Medicine Department (BR 465 road, km 07, Zona Rural, PO Box 23890-000, Seropédica, Rio de Janeiro), Brazil

* Corresponding author's Email: luisa_pucci@hotmail.com

ABSTRACT

The objective of this study was to assess vitamin E solution on the prophylaxis of intraperitoneal adhesions in ovine uterine serosal damage model with bipolar diathermy. Therefore, 19 ewes underwent laparotomy for induction of adhesions, using a uterine serosal bipolar electrocauterization model. Cauterizations were performed on the right uterine horn serosa and right ovary. Ewes were randomly divided into three groups: control group (GCT, n=5), with no treatment following electrocoagulation, another group using local rinse of 20 mL of normal saline (GNS, n=8), and the last group using local rinse of 20 mL of vitamin E injection solution (GVE, n=6). On day 21 postoperative, animals underwent laparoscopy for scoring and comparison of intraperitoneal adhesion according to frequency and number. The number of adhesions was compared among groups using the Kruskal-Wallis test and Dunn's post-hoc test. As results, the bipolar uterine serosal coagulation model triggered uterine adhesions in 74% (14/19) of the animals. Frequency of postoperative intraperitoneal adhesions was similar ($P=0.819$) among groups (80% ewes of GCT, 62.5% of GNS and 83% of GVE). There was no significant difference between treatment groups, however, number of adhesions was lower in GVE and GNS groups than in control group ($P=0.032$), showing that the addition of these kind of substances are better than not using any type of barrier to prevent the formation of intraperitoneal adhesions.

Key words: Adhesions, Bipolar diathermy, Laparoscopy, Sheep, Uterus

INTRODUCTION

Ovine specie has been widely used as an animal model on surgical research and skills training. Moreover, surgical approaches are extensively performed in ovine reproduction science and biotechnology (Teixeira et al., 2013). However, post-operative adhesion formation is one of the main concerns in surgical approach for Artificial Insemination (AI) and Ovum Pick-Up (OPU) in small ruminants (Ward and Panitch, 2011; Menchaca et al., 2016 and Zarkawi and Soukouti, 2018).

Post-operative intraperitoneal adhesions affect both human and veterinary patients, causing chronic abdominal and pelvic pain, bowel obstructions and infertility (Reijnen et al., 2003; Moris et al., 2017). As a result, patients are under risk of repeated surgical approaches for adhesiolysis (Koninckx et al., 2016). There is a growing interest for researches on prophylaxis of adhesions using barrier methods and low molecular weight intraperitoneal solutions (Decherney and Dizerega, 1997; Kamel, 2010; Yildiz et al., 2011).

Pathogenesis of adhesion formation is complex and multifactorial. Peritoneal surgical damage disrupts mesothelial cells and exposes connective tissue layers, triggering inflammation, coagulation, fibrin deposition and fibrinolysis. In a favorable intraperitoneal environment, fibrinolysis overcome fibrin deposition and mesothelial layer heals without permanent adhesion formation (Reijnen et al., 2003). However, intraperitoneal surgical trauma and inflammation may comprise fibrinolysis, resulting in coagulation/fibrinolysis imbalance. In that environment, fibroblasts migrate onto the fibrin matrix and organized collagen fibers, small blood vessels and connective tissue forms. Finally, mesothelial cells cover the connective tissue (Koninckx et al., 2017). At that point, permanent adhesions form and surgery for adhesiolysis is the treatment of choice in cases of adhesion-related complications (Reijnen et al., 2003). Surgical approaches to the

ORIGINAL ARTICLE
 pii: S2322-45681800010-8
 Received: 20 Oct 2018
 Accepted: 22 Nov 2018

uterus are both traumatic and invasive, requiring meticulous and aseptic technique to avoid postoperative adhesiogenesis (Ishwar and Memon, 1996; Wilde et al., 2017). As usual, abdominal cavity should be constantly rinsed with proper solution. The use of an intraperitoneal prophylactic method should also be considered (Decherney and Dizerega, 1997; Moris et al., 2017).

Carboxymethylcellulose, lidocaine chloride, hyaluronic acid, sodium heparin, methylene blue solution and normal saline were assessed as anti-adhesion therapies (Elkelani et al., 2002; Durmus et al., 2011; Mariano et al., 2015). Other management include selection of minimally invasive approaches such as laparoscopy, use of powder free gloves, meticulous hemostasis, use of NSAIDs and antibiotics, cautious visceral handling and less organ exposition (Reijnen et al., 2003 and Kamel, 2010). Vitamin E, a natural cell antioxidant, avoids membrane lipid peroxidation. Vitamin E showed anti-inflammatory, anticoagulant, enzymatic, genic expression and anti-fibroblast properties (Jiang, 2014). Intraperitoneal vitamin E was efficient in preventing intraperitoneal adhesion formation in rat and mouse models (Kokcam and Nairoglu, 2002; Yetkin et al., 2009; Yildiz et al., 2011; Durmus et al., 2011). Moreover, intraperitoneal vitamin E rinse decreased adhesion formation in a mouse uterine horn trauma model (Yildiz et al., 2011).

To the authors' knowledge, there is a gap in the literature concerning the use of vitamin E on the prophylaxis of adhesiogenesis in small ruminants. Thus, the purpose of this study was to assess the efficacy of intraperitoneal vitamin E solution on the prevention of adhesion formation in an ovine uterine and ovarian electrosurgical trauma model.

MATERIALS AND METHODS

Ethical approval

This study was carried out under approval by the committee for ethics in animal use of the university of Franca (protocol no. 2713070316).

Experimental animals

Nineteen healthy adult female Santa Ines ewes, aging two to five years old, weighting thirty to fifty kg and presenting mean corporal score three (scale ranging from one to five), were selected for this study. Inclusion criteria was absence of abnormalities based on clinical, hematological, coproparasitological, gynaecological and abdominal echography assessments. Animals underwent a thirty-day adaptation period, in the veterinary hospital of the university of Franca, São Paulo, Brazil, in 16m² collective stalls, receiving daily diet of Tifton hay, balanced commercial ration for ovine specie, mineral supplementation and water ad libitum.

Experimental design

Ewes were randomly divided into one out of three groups as follows: group GCT (n=5), the control group, without intraperitoneal rinse; group GNS (n=8), receiving intraperitoneal rinse of 20 ml of normal saline (Cloreto de sódio 0,9%, Baxter™, Jurubatuba, São Paulo, Brazil), and group GVE (n=6), undergoing intraperitoneal rinse of 20 ml of vitamin E (Acetato de Vitamina E, 2g, 20 mL, LaboVET™, Bahia, Brazil).

Surgical procedure

Animals were fasted for 48 hours. Prior surgery, ewes were weighted and undergone premedication with acepromazine (0.1 mg/kg, IV - Acepran®, Vetnil, Louveira, São Paulo, Brazil) and methadone (0.5 mg/kg, IM - Mytadon® Cristalia. São Paulo, São Paulo, Brazil). General anesthesia was induced using propofol (6 mg/kg, IV - Propofol® Cristalia. São Paulo, São Paulo, Brazil), 10 minutes following premedication, and maintained with isoflurane (Isoflurano® Cristalia. São Paulo, São Paulo, Brazil) vaporized in 100% oxygen delivered by tracheal tube. Ewes were positioned in dorsal recumbence, followed by aseptic prepare of the ventral abdomen and then positioned in 45° Trendelenburg as described by Teixeira et al. (2013). A 10-cm pre-pubic midline celiotomy was performed, followed by exposition of the uterus and ovaries. A uterine and ovarian serosa damage model was used to trigger adhesiogenesis. Thus, three spots of bipolar electrocoagulation (3-second period each coagulation spot) were performed on the right uterine horn. One spot was carried out on the right ovary using the same technique. A 42 cm laparoscopic bipolar forceps (Lina Tripol Powerblade™, LiNA Medical, Glostrup, Denmark) was used for electrocoagulation. After cauterization, animals were submitted to one of experimental treatments. Group GVE received 20 ml of vitamin E rinsed over the electrocoagulation spots, while group GNS received 20 ml of normal saline in the same fashion and group GCT (control) received no rinse. The reproductive tract was repositioned within the abdominal cavity. Linea alba was closed using cross mattress sutures, followed by subcutaneous space closure and skin synthesis with interrupted horizontal mattress sutures, using nylon 0 thread (Nylon 0 Bionline®, São Paulo, São Paulo, Brazil). A repellent ointment (Unguento Plus®, Pearson, São Paulo, São Paulo, Brazil) was applied on the skin around the surgical site. Skin sutures were removed following 10 days.

Exploratory laparoscopy

Ewes undergone diagnostic laparoscopy to assess uterine and ovarian adhesion formation 21 days after surgery. Anesthetic protocol and positioning for laparoscopy the same as the one employed for adhesion induction approach. A 12 mm trocar cannula was inserted through a small midline celiotomy slightly cranial to the previous surgery's scar. Carbon dioxide pneumoperitoneum was set to eight mmHg intra-abdominal pressure and 5 l/min flow rate. A 10 mm straight angle telescope was used. A 5 mm working port was established under laparoscopic assistance for insertion of an atraumatic Babcock laparoscopic forceps. The right uterine horn and ovary were handled and primarily assessed for presence of adhesion. Adhesions were classified using an adapted scoring system (Farzad et al., 2012 and Mariano et al., 2015). Scores could range from zero to five according to the number of adhesions, with five meaning ≥ 5 adhesion sites. Adhesions were also scored regarding organs involved as follows: (0) no adhesions; (1) on the uterine horn and ovarian bursa; (2) involving the uterus, ovary and uterine tube; (3) among the uterus, ovary and other organs or tissues (bowel, bladder, peritoneum). After laparoscopic adhesion scoring by macroscopic evaluation and manipulation with the forceps to analyze the integrity of viscera, pneumoperitoneum was drained and trocars were withdrawn from the abdominal wall. Skin incisions were closed with simple interrupted nylon 0 USP sutures. Animals were kept in collective stalls following complete anesthesia recovery.

Statistical analysis

All analysis was performed using the Rs (R foundation for statistical computing®, Vienna, Austria). Incidence of adhesion were compared among groups using the Fischer's exact test. Scores of the number of intraperitoneal adhesions were compared among groups using the Kruskal-Wallis test and Dunn's post-hoc test. Significance level was set to 5% ($P < 0.05$) for all tests.

RESULTS

Uterine serosa and ovarian bipolar coagulation induced adhesion formation in 14 out of 19 ewes (74%) regardless of group. Incidence of intraperitoneal adhesions did not differ statistically among groups ($P = 0.819$). Control group presented intraperitoneal adhesions in 80% of ewes (4/5), while group GNS had 62,5% cases (5/8) and GVE presented 83% cases (5/6) of post-op adhesions. Number of adhesions per animal was larger ($P = 0.032$) in control group than in both GNS and GVE (Figure 1). Adhesion scores did not differ statistically among groups regarding adhesion sites or organs ($P = 0.0869$).

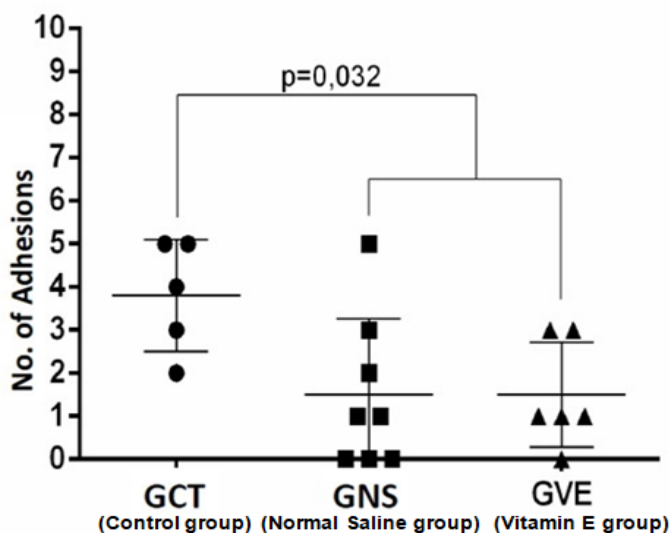


Figure 1. Grades of adhesions evaluated in experimental groups

DISCUSSION

Adhesions formed regardless of group in this study. Bipolar coagulation of uterine horn serosa and ovary was both feasible and effective in inducing intraperitoneal in the ovine experimental model. To the authors' opinion, laparotomy itself inflicts intraperitoneal trauma and desiccation, leading to inflammation, decreased fibrinolysis and adhesion formation (Ewoldt et al., 2004 and Hosseini et al., 2018). Other studies presented lower rates of adhesion induction in animal models, by laparoscopic uterine tract puncture (Mariano et al., 2015) and uterine serosa blunt trauma with

traumatic grasping forceps (Ewoldt et al., 2004). Besides decreased adhesion formation, those experimental models did not provide controlled focal damage to the reproductive tract.

Although adhesions formed in group GVE, intraperitoneal use of vitamin E resulted in fewer adhesion sites in comparison to the control group, as seen in other studies in rats undergone surgical serosa trauma (Corrales et al., 2008 and Yetkin et al., 2009). Another trial reported a decrease of 80% in adhesion formation with intraperitoneal use of vitamin E following laparotomy in rats (De La Portilla et al., 2004). Intraperitoneal vitamin E also decreased substantially adhesion formation following scalpel blade uterine horn scarification in rats (Durmus et al., 2011). Those authors attributed few adhesion formations due to the reactive oxygen specimen (ROS) scavenger and antioxidant properties of vitamin E. Normal saline did not avoid adhesion formation, as well as vitamin E, as reported in other trial (Kappas et al., 1981). That study also reported lower adhesion scores in normal saline group than in control group in a rat laparotomy model, which is in theory less traumatic adhesion induction model than the method applied in this study. Unlike Hosseini et al. (2018), who reported the same amount of adhesions after laparotomy in rats using normal saline and the control group, which no substance was applied. Vitamin E is well known as a natural anti-inflammatory agent, specifically by neutralizing ROS. However, vitamin E did not avoid adhesion formation in this reproductive tract electrocoagulation injury trial.

CONCLUSION

Vitamin E does not affect the incidence of intraperitoneal adhesions following uterine and ovary bipolar electrocoagulation injury in ewes. However, vitamin E reduces the number of adhesion sites and severity, as well as normal saline does when compared to not using any adhesion prevention. We hypothesize that a dose-dependent study should indicate if higher doses of vitamin E given intraperitoneal affect adhesiogenesis, as other studies pointed towards such property. Thus, further research is warranted to fill this gap in the literature. The experimental model of adhesiogenesis was safe and showed to be a controlled method of intraperitoneal adhesion induction since bipolar diathermy provided precise localized spot thermal injury to the ovine reproductive tract.

DECLARATIONS

Acknowledgments

The authors are thankful to the University of Franca and Fapesp (Fundação de Amparo a Pesquisa) for the support and allowing this research work to be performed. We also would like to appreciate all participants who contributed during the performance of the research, especially Dr. Ricardo Uscategui, who helped in the statistical analysis. Also, all the gratitude for Dr Lucas Pereira, who had his particular and unforgettable way of helping the involved ones in the team.

Competing interests

The authors declare that they have no competing interests.

Author's contribution

All authors have revised the work critically for important intellectual content, given their final approval of the version to be published and agreed to be accountable for all aspects of the work in ensuring that questions related to the accuracy or integrity of any part of the work are appropriately investigated and resolved. Furthermore, the authors have contributed as follows: substantial contributions to the conception, design and planning of the work, the acquisition, analysis and interpretation of data, and drafting of the work; contributions to the design of the work, and the acquisition and analysis of data. Therefore, all authors contributed equally to this work.

REFERENCES

- Corrales F, Corrales M and Schirmer CC (2008). Preventing Intraperitoneal Adhesions with Vitamin E and Sodium Hyaluronate/Carboxymethylcellulose. A Comparative Study in Rats. *Acta Cirurgica Brasileira*, 23: 36-41. Doi:<http://dx.doi.org/10.1590/S0102-86502008000100007>.
- Decherney AH and Dizerega DS (1997). Clinical problem of intraperitoneal postsurgical adhesion formation following general surgery and the use of adhesion prevention barriers. *Surgical Clinics of North America*, 77: 671-688. Doi:10.1016/s0039-6109(05)70574-0.
- De La Portilla F, Ynfante I, Bejarano D, Conde J, Fernández A, Ortega J M and Carranza G (2004). Prevention of Peritoneal Adhesions by Intraperitoneal Administration of Vitamin E: An Experimental Study in Rats. *Diseases of the Colon & Rectum*, 47: 2157-2161. Doi: 10.1007 / s10350-004-0741-6.

