



# Production of Newcastle Disease Polyclonal Antibody as the Alternative of Immunohistochemistry Primary Antibody against Newcastle Disease in Poultry

Muhammad Kholish Naf'an<sup>1</sup>, Kurniasih Kurniasih<sup>2\*</sup>, Tri Untari<sup>3</sup>, and Yos Adi Prakoso<sup>4</sup>

<sup>1</sup> Student of Master of Sciences Degree, Faculty of Veterinary Medicine, University of GadjahMada, Yogyakarta 55281, Indonesia

<sup>2</sup> Department of Pathology, Faculty of Veterinary Medicine, University of GadjahMada, Yogyakarta 55281, Indonesia

<sup>3</sup> Department of Microbiology, Faculty of Veterinary Medicine, University of GadjahMada, Yogyakarta 55281, Indonesia

<sup>4</sup> Faculty of Veterinary Medicine, University of WijayaKusuma Surabaya, East Java 60225, Indonesia

\* Corresponding author's Email: kurniasih\_1951@yahoo.co.id; ORCID: 0000-0002-3273-6958

## ABSTRACT

Newcastle disease (ND) is the most pathogenic viral infection in poultry. Furthermore, the availability of laboratories that support the molecular diagnosis of ND is still limited in Indonesia. The present study aimed to produce ND polyclonal antibody as the alternative of immunohistochemistry primary antibody against ND in poultry. Two adult male New Zealand White rabbits weighed 2.5 kg were vaccinated seven days after the adaptation using intraperitoneal injection of the ND live vaccine at multilevel doses weekly. The serum was collected inactivated, and purified in the sixth week. A total number of 31 chicken samples were collected and their samples of brain, lung, spleen, and intestine were tested using immunohistochemistry and Reverse Transcription Polymerase Chain reaction (RT-PCR). The result showed that 19/31 (61%) were positive against immunohistochemistry and RT-PCR and a total of 12/31 (39%) were negative. Based on the obtained results, immunohistochemistry using ND polyclonal antibody had a similar accuracy with RT-PCR. It can be concluded that ND polyclonal antibody produced by vaccination in the rabbit could be used as the alternative immunohistochemistry primary antibody for diagnosing ND in poultry.

**Keywords:** Immunohistochemistry, Newcastle disease, Polyclonal antibody, Poultry, RT-PCR

## INTRODUCTION

Newcastle disease (ND) is the most pathogenic viral infection in poultry. From the first outbreak of it in 1926 in Java and Newcastle, ND still has high morbidity and mortality among the poultry (Absalón et al., 2019). The ND causes severe lesions, including necrosis of brain tissue, intestine, and depression of the immune system. There are several types of ND infections in poultry including viscerotropic, neurotropic, mesogenic, respiratory, and asymptomatic. On the other hand, ND can be prevented by vaccination (Sarcheshmei et al., 2016).

The success of the vaccination program is still lacking in Indonesia due to the environmental factors, weather, and maintenance program. Newcastle disease infection in poultry is mostly undetected because of its manifestation types (Ogali et al., 2020). Furthermore, the distribution of laboratories in Indonesia that support the molecular test as a gold standard is quite limited and expensive compared to histopathology. In contrast, histopathology has low sensitivity, however, the sensitivity of tissue assessment can be increased by using the detection of an immunogenic molecule, such as an immunohistochemistry test (Zhang et al., 2017).

The immunohistochemistry increases the sensitivity and specificity of the tissue assessment performed by a pathologist since it can express the immunogenic molecule within the tissue section. The immunohistochemistry can be performed by using either monoclonal and polyclonal antibodies (Ascoli and Aggeler, 2018). Each type of antibody has a different procedure to be produced. Polyclonal antibody is commonly produced by vaccination in animal models, such as rabbits. The vaccination in rabbits induces the synthesis of antibodies by plasma cells. Nasiri et al. (2017) described that the vaccination in rabbits produces greater quantities of immunoglobulin G (IgG). The IgG is applicable for immunohistochemistry. The current study aimed to produce ND polyclonal antibodies through the vaccination in rabbits as the alternative of immunohistochemistry primary antibody against Newcastle disease compared to molecular tests using Reverse Transcription Polymerase Chain reaction (RT-PCR).

## MATERIALS AND METHODS

### Ethical approval

The animal experimentation in the present study was approved by the local ethical clearance committee from the Faculty of Veterinary Medicine, University of GadjahMada, Yogyakarta, Indonesia with reference number 0005/EC-FKH/2020. The committee conducted the monitoring and evaluation during this study.

ORIGINAL ARTICLE  
 pii: S2322-45682100024-11  
 Received: 30 Mar 2021  
 Accepted: 31 Apr 2021

### Time and place of study

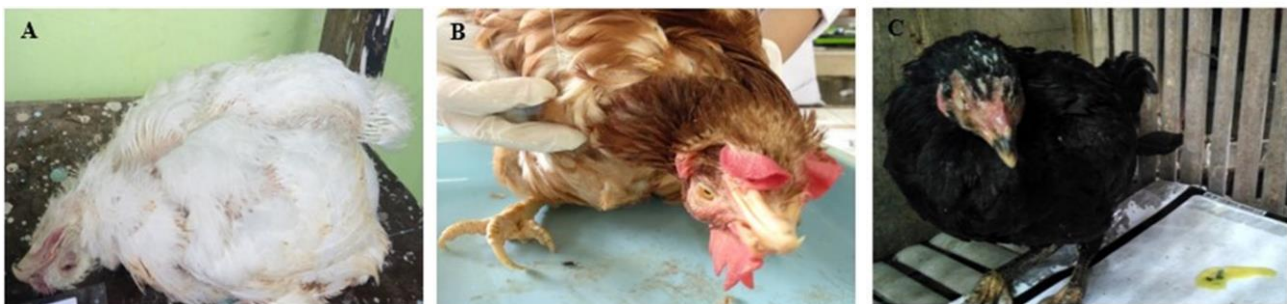The study was conducted from November 2019 until April 2020 in several places. The study was separated into three steps. The first step was antibody production and it was conducted in the Department of Pathology, Faculty of Veterinary Medicine, University of Gadjah Mada, Yogyakarta, Indonesia. The second step was an antibody purification and molecular test. Both antibody purification and the molecular test were conducted in the Laboratory of Microbiology and Virology, Station of Fish Quarantine and Quality Control, Yogyakarta, Indonesia. Finally, the third step was immunohistochemistry that conducted in the Integrated Laboratory, Faculty of Health, University of Muhammadiyah Sidoarjo, East Java, Indonesia.

### Newcastle disease polyclonal antibody production and purification

The vaccine used for producing polyclonal antibodies of ND was a live vaccine (Medivac, ND Lasota, Medion, Indonesia). The vaccination process was conducted in two male adult New Zealand White rabbits (Integrated Research and Testing Laboratory, University of Gadjah Mada, Yogyakarta, Indonesia) weighed 2.5 kg. The vaccine was injected intraperitoneally into the rabbits in the fourth week using multilevel doses 0.5 mL in the first week, 1.00 mL in the second week, 2.00 mL in the third week, and 3.00 mL in the fourth week. The serum was collected in the sixth week. Further, the serum was inactivated and purified following the procedure of Naf'an et al. (2020). The purified ND polyclonal antibody solution was stored inside the fridge at 4°C of temperature.

### Field sample collection

The samples were obtained from semi-intensive local poultry farms in Yogyakarta, Indonesia. A total of 31 samples were collected in the current study. The chickens were randomly selected regardless of sex and age. All the collected chickens should indicate the clinical signs of ND infection such as torticollis, paralysis, lethargy. The chicken samples were included 11 broiler chickens, 10 laying chickens, and 10 free-range chickens (Figure 1). The chickens were euthanized by the cervical dislocation and they were necropsied. The chicken's brain, lung, spleen, and intestine were collected and used as the tested specimens. All those organs were divided into two parts, the first part was fixed using Neutral Buffer Formalin (NBF) for immunohistochemistry and the second one was fixed in the ethanol absolute for a molecular test.



**Figure 1.** Several clinical manifestations of the chickens used in the present study. The broiler chicken with torticollis (A), laying chicken with paralysis (B), and free-range chicken with lethargy (C)

### Immunohistochemistry

The immunohistochemistry staining used the purified ND polyclonal antibody solution that has been produced in the first step of the study. The purified ND polyclonal antibody was used as the primary antibody. Further, the immunohistochemistry staining was performed following the procedure of the previous study (Prakoso et al., 2020). The positive result demonstrated a brown color, and the negative result did not demonstrate a brown color within the tissue section.

### Reverse transcription-polymerase chain reaction

The RT-PCR was used as the comparison against the immunohistochemistry. The RT-PCR was chosen as the comparison because the molecular test is a gold standard for the detection of ND in poultry. The following primer was used as the molecular target, F: 5'-GCTGTATCTGTCTGACAAGCTCTC-3' and R: 5'-AGGTTGAGTTCTACACCAACCTGT-3' (Angeliya and Wibowo, 2014). The primer was obtained from the Disease Investigation Center (DIC) Lampung, Indonesia. The procedure of RT-PCR was conducted following the procedure of the previous study without any modification (Dhar et al., 2018).

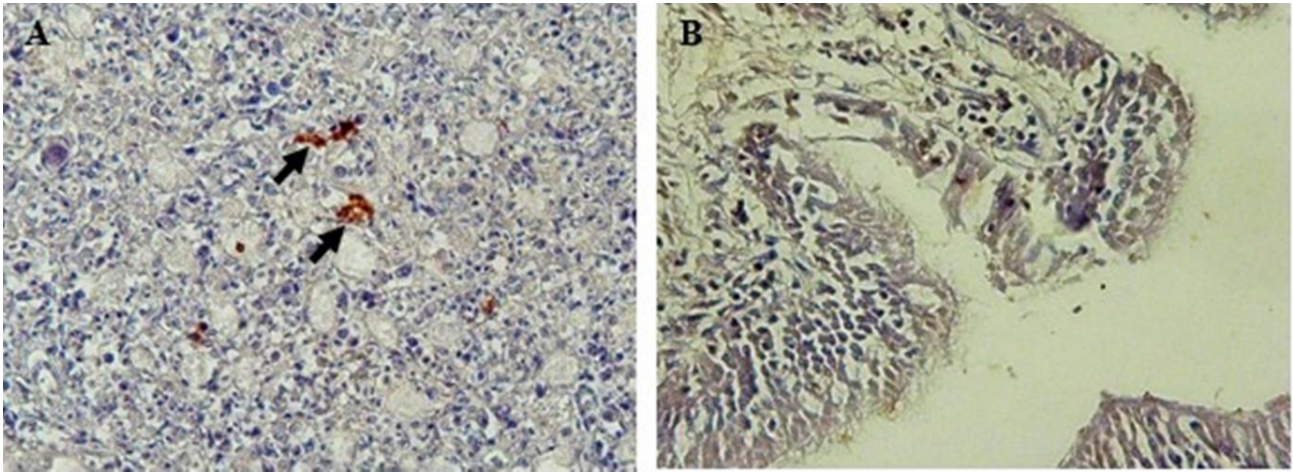
### Data analysis

All collected data were expressed as positive and negative. The data of immunohistochemistry and RT-PCR were analyzed by using descriptive qualitative methods. The sensitivity and specificity were measured using the following formulae: Sensitivity = (number of positive samples/ number of positive samples + number of false-positive samples) × 100%; Specificity = (number of negative samples/ number of negative samples + number of false-negative samples) ×

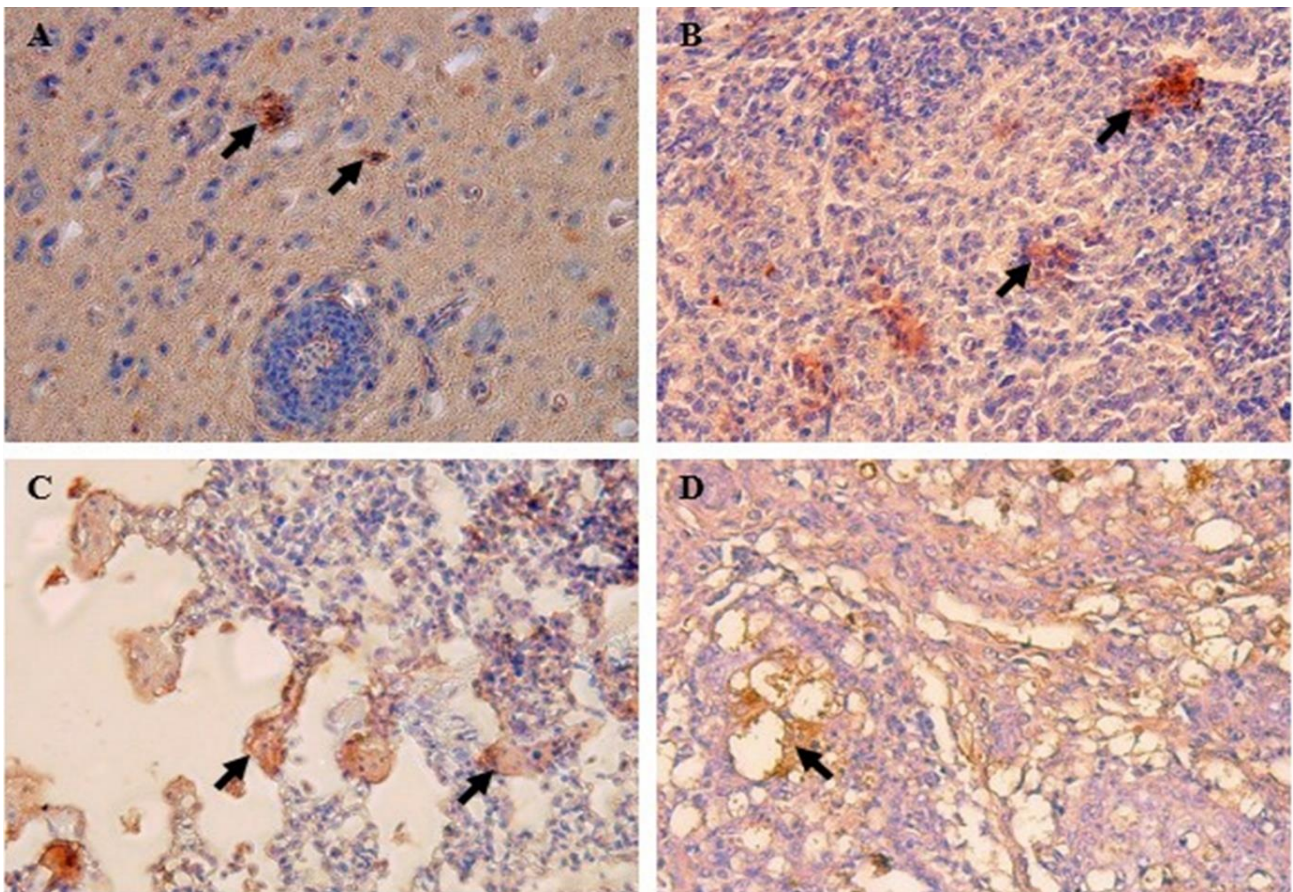
100%.

## RESULTS AND DISCUSSION

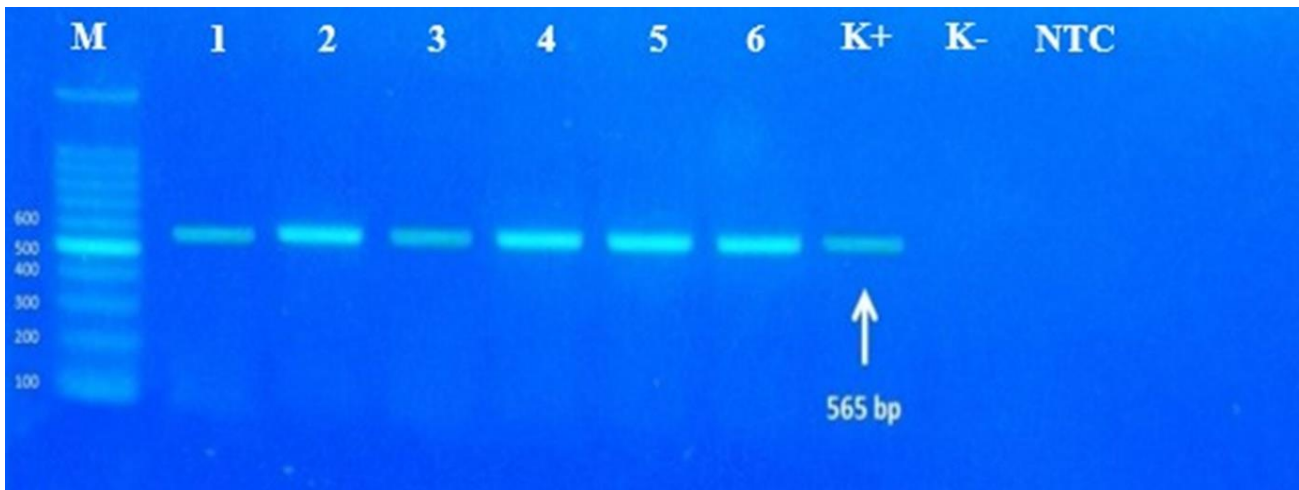
The results indicated that immunohistochemistry staining using ND polyclonal antibody stained brown color in the tissue that belonging to ND infection. The brown color appeared because of the utilization of diethylaminobenzidine (DAB) that was used as a chromogen during immunohistochemistry. The brown color was expressed as the reflection of antigen-antibody binding within the tissue (Figure 2A). In contrast, the negative control specimen did not present any reactivity (Figure 2B).



**Figure 2.** Positive and negative immunoreactivity of Newcastle Disease polyclonal antibodies within the spleen and intestine tissues from broiler chickens. The brown color expressed a positive immunoreactivity within a spleen tissue (A), there is no brown color within the intestine tissue that indicated negative immunoreactivity (B). Immunohistochemistry, ND polyclonal antibody, 200 × (A, B).



**Figure 3.** Immunoreactivity of Newcastle disease polyclonal antibodies in several organs of infected chickens. Positive immunoreactivity in the brain (A), spleen (B), lung's parabronchus (C), intestine mucosa (D). Immunohistochemistry, ND polyclonal antibody, 200 × (A, B).



**Figure 4.** The RT-PCR results from the samples that have been stained with immunohistochemistry using Newcastle disease polyclonal antibody. M = marker, 1-6 = samples; K+ = positive control; K- = negative control; NTC = non template control.

**Table 1.** The comparison of immunohistochemistry staining using Newcastle disease polyclonal antibody and RT-PCR results against Newcastle disease infection from the collected specimens of infected chickens

Status of the sample	RT-PCR		Total
	Positive	Negative	
Immunohistochemistry using ND polyclonal antibody	Positive	19 (61%)	19 (61%)
	Negative	0 (0%)	12 (39%)
Total	19 (61%)	12 (39%)	31 (100%)

The immunohistochemistry using ND polyclonal antibody indicated that 19/31 (61%) of the collected specimens were positive against ND infection and the others were negative. The antigen-antibody binding within the tissue was detected on several organs including the brain (Figure 3A), spleen (Figure 3B), lung (Figure 3C), and intestine (Figure 3D). As the confirmation test, all the specimens that have been running with ND polyclonal antibodies were tested using RT-PCR. The RT-PCR demonstrated that 19/31 (61%) were positive and 12/31 (39%) were negative. That is similar to the result of immunohistochemistry using the ND polyclonal antibody (Table 1). Representation of RT-PCR from the collected specimens could be identified in Figure 4.

ND infection causes several clinical manifestations with high economic losses among the poultry industry. The disease is marked by its ability to spread and cause death. The primary gold standard test for the detection of ND infection is based on a molecular test, such as RT-PCR. However, RT-PCR is one of the expensive laboratory procedures for Indonesian farmers. Besides, the availability of RT-PCR in Indonesia is still limited, and not all veterinary laboratories can perform this test (Adi et al., 2010). Those limitations aggravate the incidence and prevalence of ND infection in a local poultry farm in Indonesia. The diagnosis of ND in the local poultry farm is commonly conducted based on its clinical signs, macroscopic, and microscopical lesion. The microscopical lesion is majority tested using histopathology (Cardiff et al., 2006).

The local farmer has been familiar to send the chickens to the laboratory for histopathology. Histopathology becomes the recommended laboratory test, because it is cheaper than the molecular test, even though histopathology is time-consuming, and has low sensitivity. The histopathology has low sensitivity because the pathognomonic lesion is not always representing within the tissue section (Knoblauch et al., 2018). On the other hand, the sensitivity of tissue assessment can be increased by using immunohistochemistry. Immunohistochemistry has more accurate results because it detects the immunogenic molecule either in cells and tissue (Kim et al., 2016). It takes a long time to obtain the primary antibody for immunohistochemistry in Indonesia since limited companies are producing the primary antibody for immunohistochemistry in Indonesia. These factors potentially impact the availability of primary antibodies in the Indonesian market, and it makes both the researcher and technician waiting more than two months for the chemicals. One of the alternatives to conduct immunohistochemistry is by producing the polyclonal antibody through the vaccination of rabbits. The vaccination of New Zealand White rabbit produces a specific polyclonal antibody (Wicaksono et al., 2015).

The vaccination of the rabbit generates serum contained immunoglobulins which are specific for the detection of antigen within the samples. The polyclonal antibody is produced by the presentation of antigen with numerous epitopes during the vaccination. The numerous epitope antigen activates a large number of lymphocytes (Lipman et al., 2005). Further, the lymphocytes proliferate and differentiate into plasma cells that synthesize antibodies (Pioli, 2019). In the

current study, the produced antibodies were determined as the polyclonal antibody. These polyclonal antibodies have high specificity because of their ability to recognize a specific epitope rather than forming cross-reaction.

The previous study described that utilization of polyclonal antibody produced by rabbit vaccination could be used as coagglutination kit with high sensitivity for diagnosing ND in poultry (Naf'an et al., 2020) and diagnosing viral nervous necrosis in fish (Sulistiyono et al., 2020). The findings of the present study indicated that ND polyclonal antibodies produced by vaccination can be used as the primary polyclonal antibody in chickens' tissue staining. The present study proved that ND polyclonal antibody has similar sensitivity and specificity compared to RT-PCR. It is also representing that produced ND polyclonal antibody in the current study had high affinity rather than avidity because it was able to bind the specific location and forming specific antigen-antibody binding. The present study provided an alternative primary antibody for immunohistochemistry against the ND virus that could be replaced the RT-PCR dependency to diagnosing ND infection. Like many other breakthroughs in veterinary medicine, the production of a polyclonal antibody for immunohistochemistry by using rabbit vaccination is a brilliantly simple idea.

## CONCLUSION

The vaccination of ND live vaccine in New Zealand White rabbit generates serum consisted of polyclonal antibody. The ND polyclonal antibody produced by vaccination in the current study could be applied as an alternative polyclonal antibody for immunohistochemistry in diagnosing ND infection with high sensitivity and specificity compared to RT-PCR.

## DECLARATIONS

### Authors' contribution

All the authors contributed equally to the present study.

### Competing interests

The authors have not declared any conflict of interests.

### Acknowledgments

All the staff from the Department of Pathology, Faculty of Veterinary Medicine, University of Gadjah Mada; staff from Laboratory of Microbiology and Virology, Station of Fish Quarantine and Quality Control, Indonesia, and staff from Integrated Laboratory, Faculty of Health, University of Muhammadiyah Sidoarjo, Indonesia were acknowledged for their assistance in the present study.

### Ethical consideration

Ethical issues (Including plagiarism, consent to publish, misconduct, data fabrication and/or falsification, double publication and/or submission, and redundancy) have been checked by the authors.

## REFERENCES

- Absalón AE, Cortés-Espinosa DV, Lucio E, Miller PJ, and Afonso CL (2019). Epidemiology, control, and prevention of Newcastle disease in endemic regions. Latin America. *Tropical Animal Health and Production*, 51(5): 1033-1048. DOI: <https://www.doi.org/10.1007/s11250-019-01843-z>.
- Adi AA, Astawa NM, Putra KS, Hayashi Y, and Matsumoto Y (2010). Isolation and characterization of a pathogenic Newcastle disease virus from a natural case in indonesia. *The Journal of Veterinary Medical Science*, 72(3): 313-319. <https://www.doi.org/10.1292/jvms.09-0303>.
- Angeliya L, and Wibowo MH (2014). Molecular characterization of fusion gene fragment of Newcastle disease virus isolates in Disease Investigation Center Lampung working area from 2010-2013. Theses. Universitas Gadjah Mada, Indonesia. Available at: <https://repository.ugm.ac.id/130667/>.
- Ascoli CA, and Aggeler B (2018). Overlooked benefits of using polyclonal antibodies. *Biotechniques*, 65(3): 127-136. DOI: <https://www.doi.org/10.2144/btn-2018-0065>.
- Cardiff RD, Gregg JP, Miller JW, Axelrod DE, and Borowsky AD (2006). Histopathology as a predictive biomarker: Strengths and limitations. *The Journal of Nutrition*, 136(10): 2673-2675. DOI: <https://www.doi.org/10.1093/jn/136.10.2673S>
- Dhar PK, Dutta A, Das A, Jalal MS, Barua H, and Biswas PK (2018). Validation of real-time reverse transcription-polymerase chain reaction to detect virus titer and thermostability of Newcastle disease live virus vaccine. *Veterinary World*, 11(11): 1597-1603. DOI: <https://www.dx.doi.org/10.14202%2Fvetworld.2018.1597-1603>.
- Kim SW, Roh J, and Park CS (2016). Immunohistochemistry for pathologist: Protocols, pitfalls, and tips. *Journal of Pathology and Translational Medicine*, 50(6): 411-418. DOI: <https://www.doi.org/10.4132/jptm.2016.08.08>.
- Knoblaugh SE, Hohl TM, and La Perle K (2018). Pathology principles and practices for analysis of animal models. *ILAR Journal*, 59(1): 40-50. <https://www.doi.org/10.1093/ilar/ilz001>.
- Lipman NS, Jackson LR, Trudel LJ, and Weis-Garcia F (2005). Monoclonal versus polyclonal antibodies: distinguishing characteristics, applications, and information resources. *ILAR Journal*, 46(3): 258-268. DOI: <https://www.doi.org/10.1093/ilar.46.3.258>.
- Naf'an MK, Kurniasih K, Untari T, and Prakoso YA (2020). Development of coagglutination kit as rapid test for diagnosing

Newcastle disease in poultry. *Veterinary World*, 13(8): 1719-1724. DOI: <https://www.doi.org/10.14202/vetworld.2020.1719-1724>.

- Nasiri H, Valedkarimi Z, Aghebati-Maleki L, Abdolalizadeh J, Kazemi T, Esparvarinha M, and Majidi J (2017). Production and purification of polyclonal antibody against F(ab')<sub>2</sub> fragment of human immunoglobulin G. *Veterinary Research Forum : An International Quarterly Journal*, 8(4): 307-312. Available at: <https://www.ncbi.nlm.nih.gov/pubmed/29326789>.
- Ogali IN, Okumu PO, Mungube OO, Lichoti JK, Ogada S, Moraa GK, Agwanda BR, and Ommeh SC (2020). Genomic and pathogenic characteristic of virulent Newcastle disease virus isolated from chicken in live bird markets and backyard flocks in Kenya. *International Journal of Microbiology*, pp. 1-11. DOI: <https://www.doi.org/10.1155/2020/4705768>.
- Pioli PD (2019). Plasma cells, the next generation: beyond antibody secretion. *Frontiers in Immunology*, 10(2768): 1-7. DOI: <https://www.doi.org/10.3389/fimmu.2019.02768>.
- Prakoso YA, Rini CS, Rahayu A, Sigit M, and Widhowati D (2020). Celery (*Apiumgraveolens*) as a potential antibacterial agent and its effect on cytokeratin-17 and other healing promoters in skin wounds infected with methicillin-resistant *Staphylococcus aureus*. *Veterinary World*, 13(5): 865-871. DOI: <https://www.doi.org/10.14202/vetworld.2020.865-871>.
- Sarcheshmei M, Dadras H, Mosleh N, and Mehrabanpour MJ (2016). Comparative evaluation of the protective efficacy of different vaccination programs against a virulent field strain of the Newcastle disease virus in broilers. *Brazilian Journal of Poultry Science*, 18(3): 363-370. DOI: <http://www.dx.doi.org/10.1590/1806-9061-2015-0128>.
- Sulistiyono A, Kurniasih K, and Untari T (2020). Detection of nervous necrosis virus of grouper fish in Lombok Island, Indonesia based on serological and molecular studies. *Egyptian Journal of Aquatic Biology and Fisheries*, 24(1): 329-335. DOI: <https://www.dx.doi.org/10.21608/ejabf.2020.70593>.
- Wicaksono WP, Permana DS, Maryam R, and Einaga Y (2015). Synthesis of polyclonal antibody against aflatoxin B1. *Makara Journal of Science*, 19(3): 91-95. DOI: <https://www.doi.org/10.7454/mss.v19i3.4847>.
- Zhang H, Wen W, and Yan J (2017). Application of immunohistochemistry in hydrobiological studies. *Aquaculture and Fisheries*, 2(3): 140-144. DOI: <https://www.doi.org/10.1016/j.aaf.2017.04.004>.