



Carrageenan-Induced Acute Inflammation on Back-Skin of Mice: Histopathological Features, Number of Inflammatory Cells, and Expression of COX-2, COX-1, and IL-6

Sitarina Widyarini^{1*}, Sugiyono¹, Afif Muhammad Akrom^{1*}, and Alsida Paryuni²

¹Department of Pathology, Faculty of Veterinary Medicine, University Gadjah Mada, Yogyakarta, Indonesia

²Department of Internal Medicine, Faculty of Veterinary Medicine, University Gadjah Mada, Yogyakarta, Indonesia

*Corresponding author's Email: sitarina@ugm.ac.id

ABSTRACT

Carrageenan is a sulfated polysaccharide obtained from red seaweed (Rhodophyceae) and can trigger inflammatory activation in both humans and laboratory animals. This study aimed to investigate the expression of cyclooxygenase-2 (COX-2), cyclooxygenase-1 (COX-1), and interleukin-6 (IL-6) and the number of inflammatory cells (neutrophil) involved in a carrageenan-induced acute inflammatory model in the back skin of mice. Paraffin blocks from the back skin of female Swiss mice aged 8 weeks were used in this study. The back-skins of 4 groups of 5 mice in each group were subcutaneously injected with 1%, 2%, and 4% carrageenan powder in 0.9% buffer saline and 0.9% buffer saline as control. Skin samples on paraffin blocks were taken 6 hours after carrageenan injection. Furthermore, paraffin blocks were stained with hematoxylin-eosin (HE) to count the number of inflammatory cells. Immunohistochemistry staining using anti-COX-2, COX-1, and IL-6 antibodies was performed to determine the role of inflammatory mediators. The results showed that the number of inflammatory cells (neutrophils) increased significantly following an increase in carrageenan concentrations. The COX-2, COX-1, and IL-6 expressed by inflammatory cells increased significantly at carrageenan concentrations of 1% to 4%. Histopathological features supported the results obtained from the calculation of the number of inflammatory cells and the expression of COX-2, COX-1, and IL-6. The inflammatory markers consisting of COX-2, COX-1, and IL-6 were expressed on the back skin of mice at 6 hours post-injection with 1% to 4% carrageenan. It can be concluded that carrageenan can be used for an acute inflammatory model of the back skin of a mouse. This inflammation model is intended to facilitate the evaluation or measurement of therapeutic and inflammatory responses when test substances are administered topically or transdermal.

Keywords: Carrageenan, Cyclooxygenase-2, Cyclooxygenase-1, Interleukin-6, Inflammatory cell, Skin inflammation

INTRODUCTION

The development of inflammatory models in experimental animals has been widely carried out to know the release of inflammatory mediators at the inflammation site and determine antiinflammatory activity and efficacy (Fehrenbacher et al., 2012). Previous studies have reported various models to test inflammatory activity using a variety of chemicals and physical agents as inductors (Widyarini et al., 2001; Wei et al., 2016; Wu et al., 2017). Both chemicals and physical agents have been reported to be used in skin and colonic inflammation models in experimental animals (Widyarini et al., 2001; Huang et al., 2014; Wei et al., 2016; Wu et al., 2017). Chemical inductors for inflammatory models are formalin, kaolin, yeast, dextran, croton oil, carrageenan (Fehrenbacher et al., 2012), a combination of oxazolone and carrageenan (Wu et al., 2016), and a combination of 2,4,6-trinitrobenzene sulfonic acid (TNBS) and carrageenan (Wei et al., 2016).

One of the ingredients that are widely used for the activation of inflammatory pathways is carrageenan. Carrageenan is a sulfated polysaccharide obtained from red seaweed named Rhodophyceae (Necas and Bartosikova, 2013) and has been widely used as a thickener, stabilizer, and communitizing agent in the processing of dairy and cosmetic products (Pereira et al., 2018; Shafie et al., 2022; Kot et al., 2023). Carrageenan has been reported by some researchers as a model for inflammatory research in guinea pigs, rats, and mice (Fehrenbacher et al., 2012; Necas and Bartosikova, 2013). In addition, carrageenan is not only used for inflammatory models but has also been reported to trigger the occurrence of colorectal tumors in the *Apc^{min/+}* mice and colitis in C57BL/6J mice (Bhattacharyya et al., 2017; Shang et al., 2017; Wang et al., 2023).

Subcutaneous injection of carrageenan causes local inflammation characterized by inflammatory signs, namely tumor, color, dolor, rubor, and function laesa (Fehrenbacher et al., 2012). Furthermore, carrageenan injection as a model of paw edema showed macroscopic changes in the form of erythema, swelling, and hyperalgesia (Ben Khedir et al., 2016; Szekalska et al., 2020). Carrageenan injection on the paws of the mice also showed microscopic images in the form of

ORIGINAL ARTICLE
pII: S232245682300055-13
Received: 27 September 2023
Accepted: 05 November 2023

acute edema, expanded epidermal thickness, vasculitis, and invasion of immune cells within the epidermis and dermis (Szekalska et al., 2020; Vysakh et al., 2020).

Inflammatory models with carrageenan as an irritant are used to trigger transient inflammation (acute inflammatory model, Fehrenbacher et al., 2012). Furthermore, carrageenan, as an acute inflammatory model, can be used to observe inflammation that occurs in animal models and as a method to monitor the inflammatory response due to the administration of antiinflammatory drugs in experimental animals. Carrageenan injection induces inflammation through a biphasic phase. In the vascular phase, proinflammatory cytokines such as TNF- α , IL-6, and IL- β are involved from the first hour after injection, while prostaglandins play an important role in the cellular phase (second phase), which occurs in the 3-5th hour post injection (Reanmongkol et al., 2009). The mediators mentioned above are responsible for erythema, edema, and pain at the injection site.

Previous studies have stated that more than 400 studies have reported that carrageenan is widely used as a model for inflammatory evaluation of mouse paw edema (Posadas et al., 2004; Suralkar et al., 2008; Fehrenbacher et al., 2012). Evaluation of acute inflammatory models using the back skin of mice has been widely practiced but not by using carrageenan as an inducer (Widyarini et al., 2001; Widyarini et al., 2006; D'Orazio et al., 2013; Kim, 2016). It has been reported that inflammatory models with subcutaneous injection of carrageenan (1-4%) on the back skin of mice result in maximum inflammatory response obtained at a concentration of 4% (Widyarini et al., 2023). The acute inflammatory model using the back skin of mice is expected to facilitate treatment and its evaluation or measurement of inflammatory responses when the test material is administered topically or transcutaneous. Moreover, topical application of the antiinflammatory test material will be easier if carrageenin is injected subcutaneously into the back skin of the mouse than if it is injected into the mouse paw. This study aimed to determine the role of inflammatory mediators in the acute inflammatory process of the back skin of mice triggered by carrageenan. Observations were made by microscopic examination of hematoxylin-eosin (HE) and immunostaining to calculate the number of inflammatory cells and the expression of COX-2, COX-1, and IL-6 in the back skin tissue of mice at 6 hours after injection of carrageenan.

MATERIALS AND METHODS

Ethical approval

This research has received research ethics feasibility from the Research Ethics Commission of the Faculty of Veterinary Medicine, University Gadjah Mada, Indonesia (Number: 024/EC-FKH/Addn./2022).

Study period and location

This study was conducted in January 2022 at the Department of Pathology, Faculty of Veterinary Medicine, University Gadjah Mada, Yogyakarta, Indonesia, and Pathology Laboratory of Prof Dr. Sardjito Hospital, Yogyakarta, Indonesia.

Experimental designs

Paraffin blocks were derived from a previous study (Widyarini et al., 2023). Twenty (20) female Swiss mice aged 8 weeks with an average weight of 30 grams were divided into four groups of five. Mice were purchased from the Integrated Laboratory for Research and Testing, University Gadjah Mada, Indonesia. All animals except the control group were received subcutaneously (SC injection), in the back area with 0.1 mL λ -carrageenan in 0.9% buffer saline (Sigma Chemical Co, USA), with concentrations of 1%, 2%, and 4%. The control group was only injected subcutaneously with 0.9% buffered saline. At six hours post-injection with carrageenan, all animals were euthanized by cervical dislocation technique. Subsequently, the skin in the injection area is excised for 1 cm² and then fixed in 10% buffer formalin for tissue processing and making paraffin blocks at the Department of Pathology, Faculty of Veterinary Medicine, University Gadjah Mada, Indonesia. Other materials used in this study were microtome for paraffin block cutting (Olympus, Japan), poly-L-lysine-coated slides (Sigma Chemical. Co., USA), and a set of tools for tissue staining with hematoxylin-eosin (HE, Leica Biosystem, USA), as well as anti-COX-2, COX-1 and IL-6 antibodies (Biocare Medical, USA).

Histopathological preparations

Histopathological preparations were carried out according to the standards of the Pathology Laboratory of the Faculty of Veterinary Medicine, University Gadjah Mada Indonesia. Paraffin blocks containing samples (back of mouse skin) were cut to a thickness of 5 μ m using a microtome, then placed in a water bath and glued to a glass object. Next, the slides were soaked in xylol I and xylol II solutions each for ten minutes and then placed in alcohol (absolute I, absolute II, alcohol 90%, alcohol 80%, and alcohol 70%) for five minutes each. The slides were then soaked in hematoxylin for ten minutes and rinsed under running tap water for 15 minutes. Subsequently, the slides were immersed in eosin for three to five minutes. After that, the slides were placed into alcohol series (70%, 90%, 100% of absolute

alcohol I and absolute alcohol II), once for one minute, then the slides were placed into xylol for five minutes, mounted with mounting medium DPX (Merck, Germany), and covered with a deck glass.

Immunohistochemistry staining

The preparation of immunohistopathological examinations was carried out according to the standards of the Pathology Laboratory of Prof. Dr. Sardjito Hospital Indonesia. Paraffin blocks containing samples (back-skin mice) were cut to 5 µm thick using a microtome, placed on a water bath, and affixed to a glass object overlaid with poly-L-lysine (Sigma Chemical. Co., USA). Next, the slides were immersed in a solution of xylol I and xylol II for ten minutes each and then placed into alcohol series (absolute I, absolute II, absolute III, alcohol 90%, alcohol 80%, and alcohol 70%) for five minutes each. Then, slides were immersed in 0.3% H₂O₂ in methanol for 30 min and washed with pH PBS. 7.2, three times in 5 minutes. Rabbit polyclonal antibodies to COX-2, COX-1, and IL-6 (Biocare Medical, USA) diluted 1:200 was dripped to 100 µl to cover the tissue area to be stained and incubated at room temperature for an hour. After incubation, the slides were washed with PBS three times for 5 min and then incubated with secondary antibodies (Starr Trek Universal HRP Detection System, Biocare Medical, USA) for one hour at room temperature. After washing, slides were incubated with DAB for two minutes at room temperature and then washed under running water. Counterstains were performed by using HE for 10 seconds, followed by washing with running water. In the final stage, slides were immersed in alcohol series (90% alcohol, absolute I, absolute II) once for one minute. Then, the slides were placed into xylol for five minutes, mounted using DPX mounting media (Merck, Germany), and covered with a deck glass.

Statistical analysis

Observations of the number of inflammatory cells were carried out using a binocular light microscope (Olympus CX-23, Japan) with a magnification of 200x. Inflammatory cells in the dermis and subcutaneous areas were calculated from five fields of view using Image Raster 3.7. The average number of inflammatory cells in the treatment group with different percentages of carrageenan was then analyzed using One Way Anova and followed by the Tukey-HSD Test (SPSS Statistics version 26, USA). The p-value less than 0.05 was considered statistically significant. The location of COX-2, COX-1, and IL-6 expression was observed, and the number of inflammatory cells that expressed COX-2, COX-1, and IL-6 was also calculated.

RESULTS

Histopathological examination and inflammatory cell count

Histopathological examination was carried out by taking a skin sample six hours after carrageenan injection for examination under a microscope with hematoxylin-eosin staining. The histopathological pictures show that the group injected with carrageenan at the level of 1-4% showed changes in the dermis and subcutaneous areas. The changes are in the form of edema in the dermis area accompanied by infiltration of inflammatory cells that are increasingly visible along with the increase of the carrageenan concentration (Figure 1), which were in accordance with research conducted by Widyarini et al. (2023). The results of histopathological observation by HE staining in this study showed main changes in the form of edema and inflammatory cell infiltration in the dermis and subcutaneous area (Figure 1). In addition, the results of calculating the number of inflammatory cells in the dorsal skin of mice injected with 1-4% carrageenan can be presented in Figure 2. Figure 2 shows that in normal skin or untreated mice, there were also inflammatory cells were found only in mouse skin. Injections of 1% and 2% carrageenan showed no significant difference in inflammatory cell counts ($p > 0.05$). However, injecting 4% carrageenan into the back skin of mice increased the number of inflammatory cells more than the injection of 1% and 2% carrageenan ($p < 0.05$). Hence, the higher concentration of carrageenin (4%) resulted in more severe tissue damage, and more inflammatory cells were found.

Cyclooxygenase-2, Cyclooxygenase-1 and Interleukin-6

Immunohistochemistry analysis of the back skin of mice injected with 1-4% carrageenan showed an increase in COX-2, COX-1, and IL-6 expression compared with the dorsal skin group without carrageenan treatment (Figures 3, 4, 5, 6, 7, and 8). Expression is characterized by the presence of brown staining in skin epithelial cells and inflammatory cells. The results of this study only calculated the expression of COX-2, COX-1, and IL-6 by inflammatory cells found in the dermis and subcutaneous areas. COX-2 expression on the back skin of mice after injection with carrageenan can be seen in Figure 3. In Figure 3A (normal back skin), no COX-2 expression was found. COX-2 expression was found in the dermis of the group that was given 1% and 2% carrageenin. Interestingly, the injection of carrageenin 4% showed COX-2 expression not only in the dermis area but also in the subcutis area. Figure 4 shows the average number of inflammatory cells expressing COX-2. The number of inflammatory cells expressing COX-2 increased along with the

increase in carrageenin concentration ($p < 0.05$). Injection of 4% carrageenin showed COX-2 expression in more inflammatory cells (approximately 30%) than those given 1% and 2% carrageenin ($p < 0.05$).

Figure 5 shows the expression of COX-1 on the back skin of mice injected with carrageenan. COX-1 expression is found in normal skin (Figure 5A). There is an increase in COX-1 expression in inflammatory cells of approximately 60%, compared to expression in normal skin ($p < 0.05$, Figure 6). However, there was no significant difference in COX-1 expression in the 1-4% carrageenin group. IL-6 expression in inflammatory cells and the number of IL-6-expressing cells can be seen in Figures 7 and 8. Normal skin does not express IL-6. On the other hand, IL-6 expression increased in the dermis area after 1-4% carrageenin injection (Figure 7). The number of inflammatory cells expressing IL-6 increased in line with the increase in carrageenin concentration (Figure 8). Injection of carrageenin 1%, 2%, and 4% significantly increased the number of inflammatory cells expressing IL-6 with an optimal concentration of 4%.

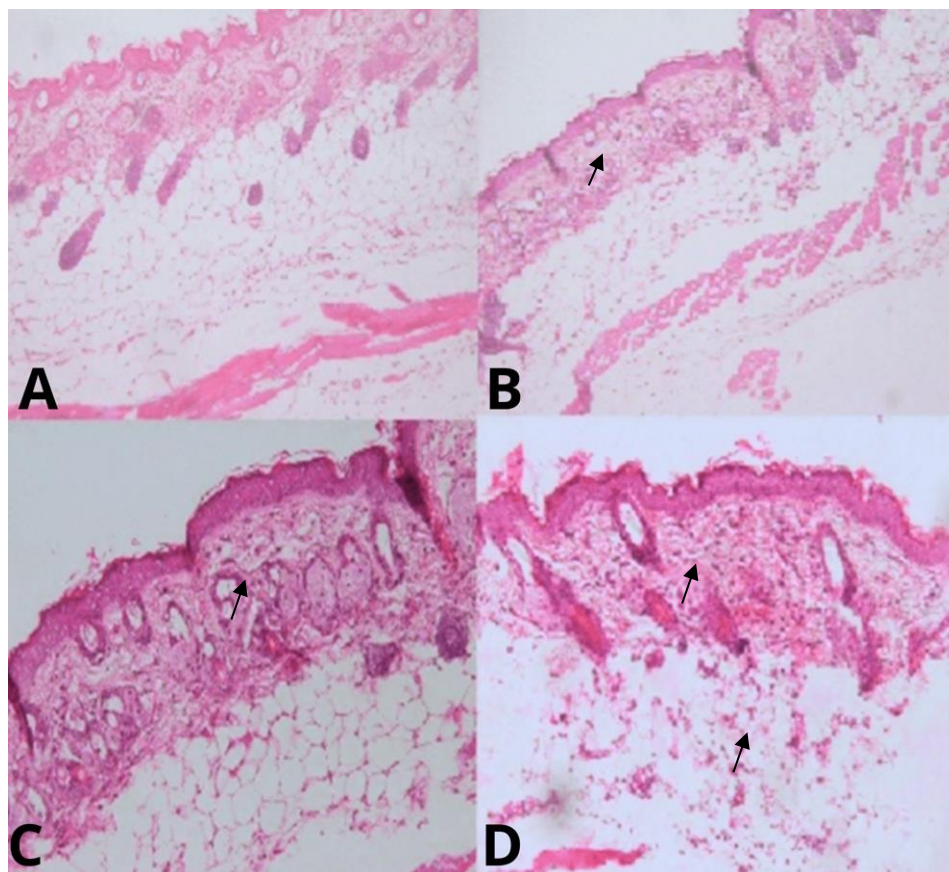


Figure 1. Microphotography of back-skin mice post-injection of 1-4% carrageenan. **A:** Mouse skin without carrageenan treatment. **B, C, and D:** Mouse skin with carrageenan treatment at 1-4%. Area's infiltration inflammatory cells of dermal (**B, C**; black arrow) and areas infiltration inflammatory cells (neutrophile) of dermal and subcutaneous edema (**D**; black arrow). HE staining, 200X magnification.

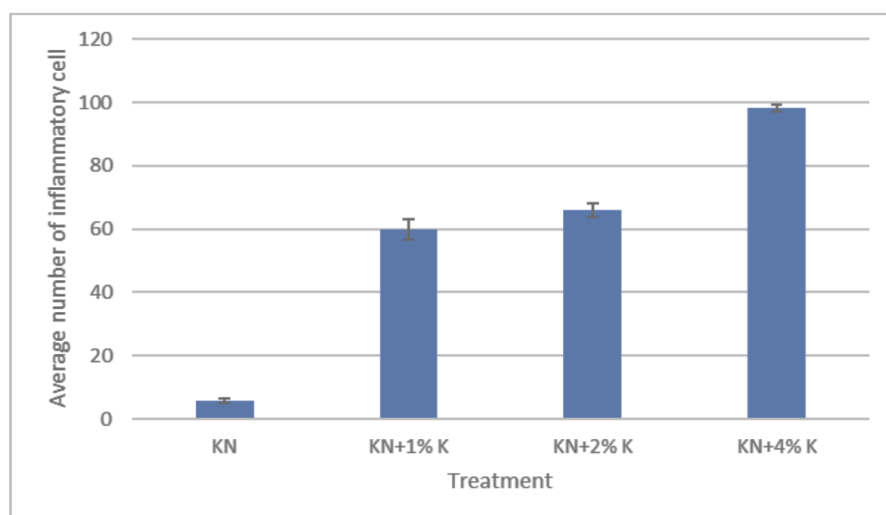


Figure 2. The average number of inflammatory cells (neutrophils) in the back skin of mice injected with 1-4% carrageenan. KN: Untreated mice skin. KN+1%, KN+2%, and KN+4%: Mice skin with carrageenan treatment 1-4%, respectively.

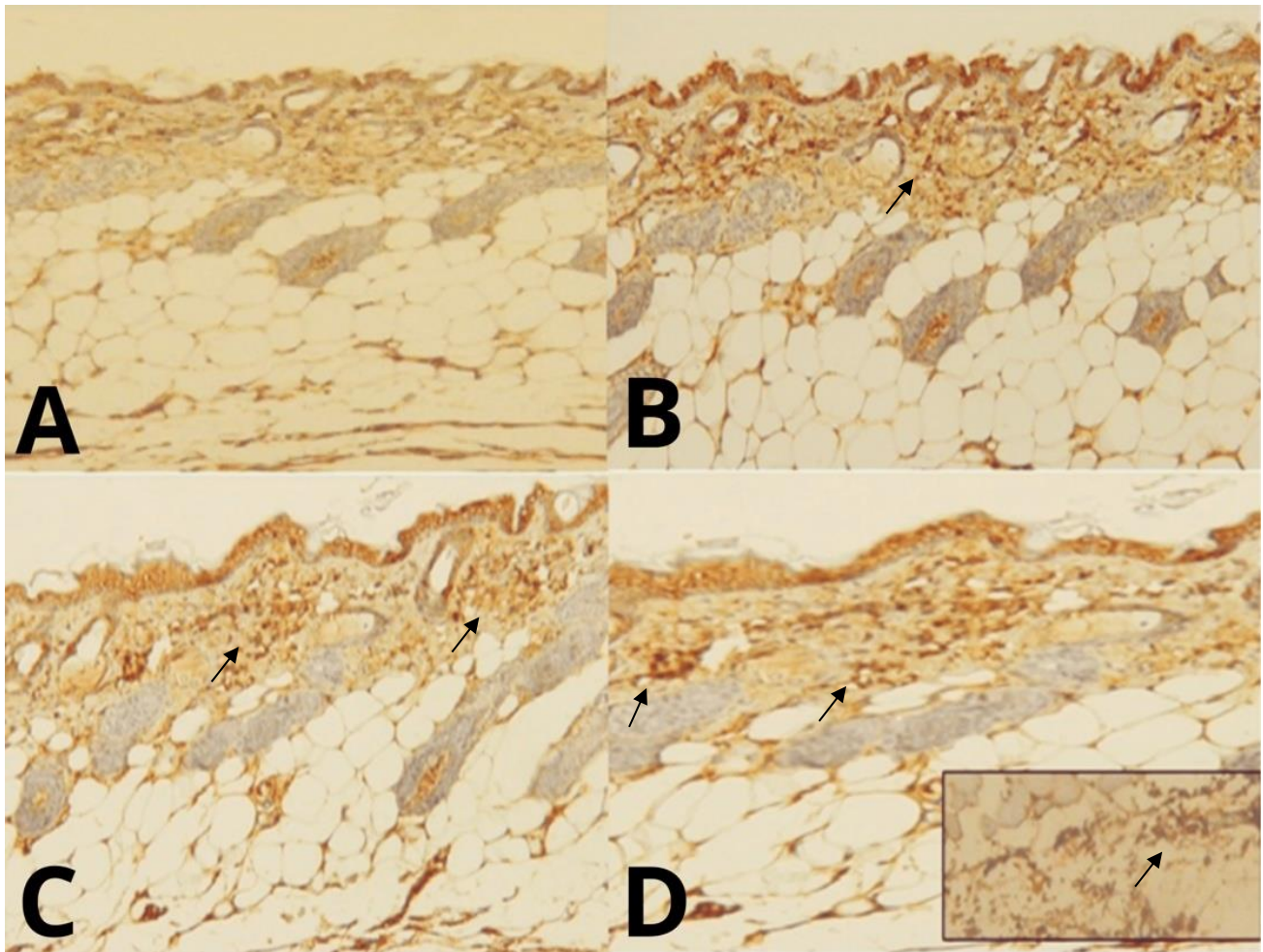


Figure 3. Microphotography expression of COX-2 in the back skin of mice post injection of 1-4% carrageenan. **A:** Mouse skin without carrageenan treatment. **B, C, and D:** Mouse skin with carrageenan treatment at 1-4%. COX-2 expression was found in the dermal area (**B, C, and D;** black arrow) and in the right corner box-subcutaneous area (**D;** black arrow). Anti-COX-2 antibody staining, 200× magnification.

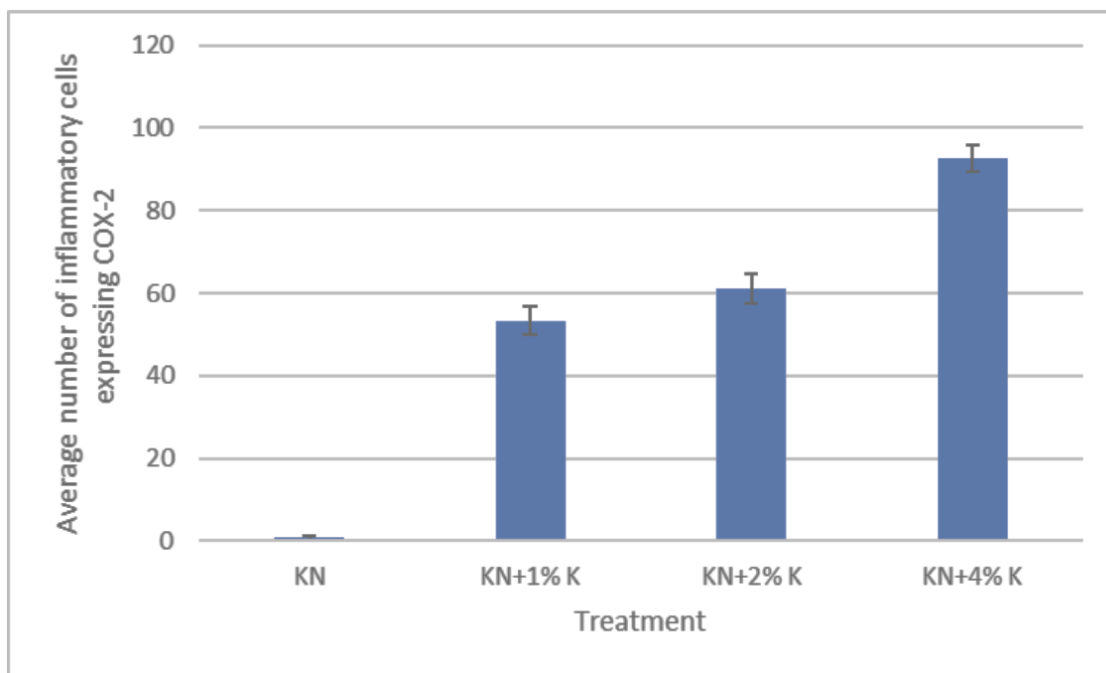


Figure 4. The average number of inflammatory cells in the back skin of mice injected with 1-4% carrageenan expressing COX-2. KN: Untreated mice skin. KN+1%, KN+2%, and KN+4%: Mice skin with carrageenan treatment 1-4%.

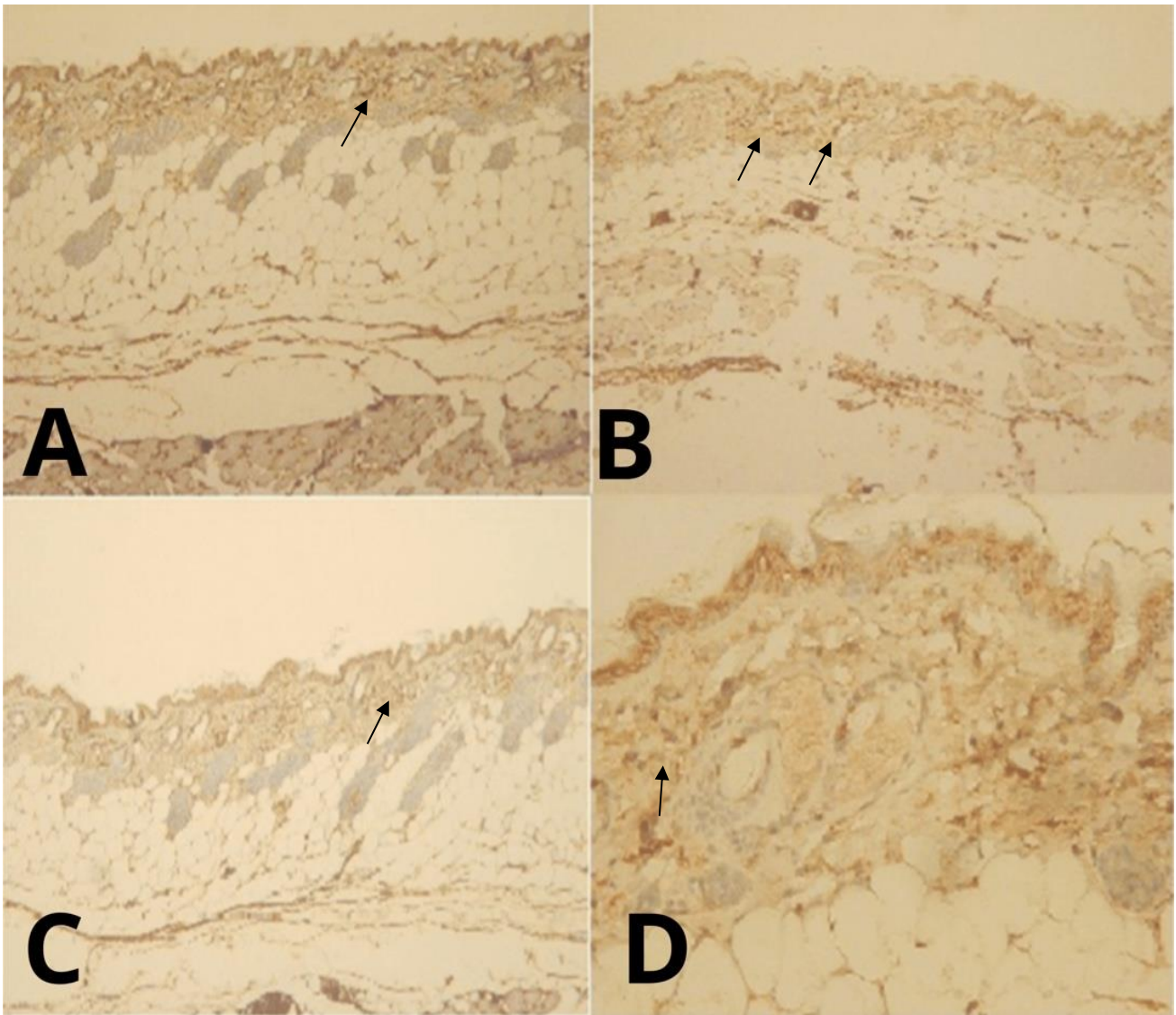


Figure 5. Microphotography of back-skin mice post-injection of 1-4% carrageenan. **A:** Mouse skin without carrageenan treatment. **B, C, and D:** Mouse skin with carrageenan treatment at 1-4%. COX-1 expression was found in the dermis area (black arrow). Anti-COX-1 antibody staining, 200× magnification.

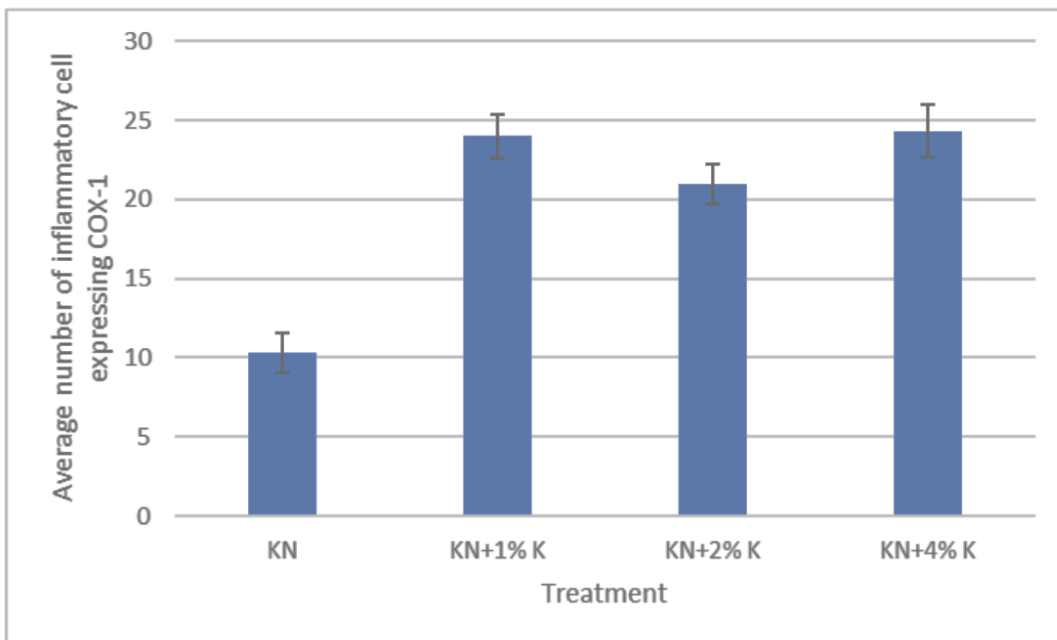


Figure 6. The average number of inflammatory cells in the back skin of mice injected with 1-4% carrageenan expressing COX-1. KN: Untreated mice skin. KN+1%, KN+2%, and KN+4%: Mice skin with carrageenan treatment 1-4%.

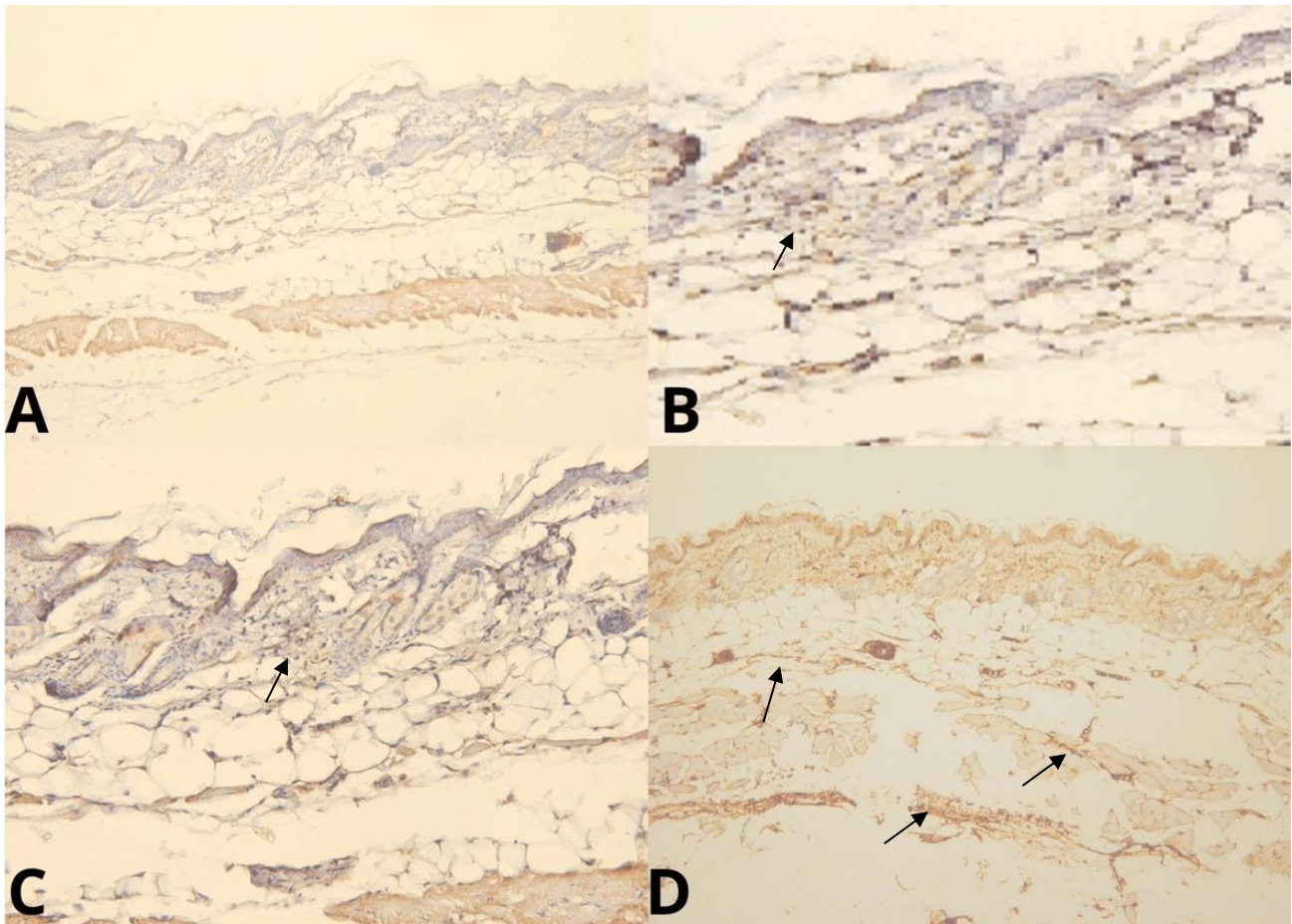


Figure 7. Microphotography of back-skin mice post-injection of 1-4% carrageenan. **A:** Mouse skin without carrageenan treatment. **B, C, and D:** Mouse skin with carrageenan treatment at 1-4%. IL-6 expression was found in the dermis area (black arrow). Anti-IL-6 antibody staining, 200× magnification.

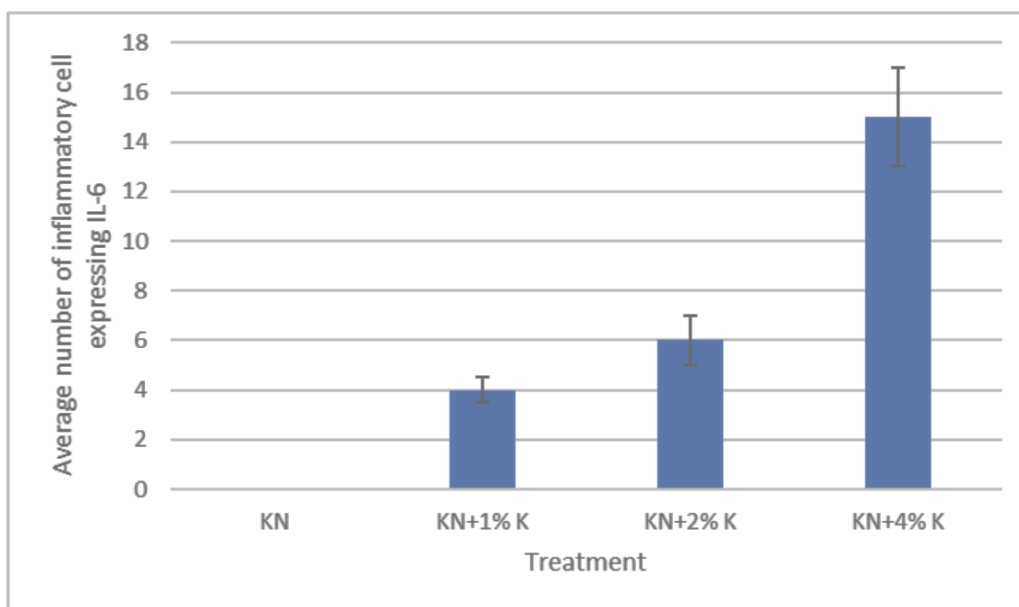


Figure 8. The average number of inflammatory cells in the back skin of mice injected with 1-4% carrageenan expressing IL-6. KN: Untreated mice skin. KN+1%, KN+2%, and KN+4%: Mice skin with carrageenan treatment 1-4%.

DISCUSSION

A previous study by Widyarini et al. (2023) demonstrated that injection with carrageenan concentrations of 1% and 2% produced histopathological changes in the form of mild and moderate inflammation, which were observed as infiltration of inflammatory cells in the dermis accompanied by edema in the dermis. Furthermore, severe dorsal skin inflammation

of mice was observed in the 4% carrageenan injected group, demonstrating histopathological features in the form of inflammatory cell infiltration in the dermis. Carrageenan can increase vascular permeability and result in edema (Zhang et al., 2022) and panniculus accompanied by edema (Widyarini et al., 2023). A similar histopathological picture is shown in Figure 1.

Figure 1 shows that the higher the concentration of carrageenan results in more severe skin tissue damage. The studies performed by Szekalska et al. (2020) and Vysakh et al. (2020) reported the injection of carrageenan into the paws of mice showed microscopic features in the form of acute edema, increased epidermal thickness, vasculitis, swelling, and infiltration of inflammatory cells in the epidermis and dermis. Injection of different concentrations of carrageenan (1% to 4%) into the dorsal skin of mice revealed microscopic changes in the form of edema and infiltration of inflammatory cells into the dermis and panniculus of varying severity but no microscopic features of hyperemia or vasculitis were found (Figure 1). This is thought to be because the sampling of the back skin of mice in this study was carried out at the sixth hour after carrageenan injection where the effect of carrageenan in the vascular phase has passed, so hyperemia and vasculitis are not found on microscopic examination, as it has been reported by previous studies (Reanmongkol et al., 2009; Ben Khedir et al., 2016; Szekalska et al., 2020).

Previous studies have only reported an association between carrageenan injection on the paws of the mouse (paw edema model) and histopathological images of inflammatory responses (Zhang et al., 2013; Felhi et al., 2017). In this study, quantification of the number of inflammatory cells was performed. The results showed that carrageenan injection at concentrations increasing from 1% to 4% increased the average number of inflammatory cells (Figure 2). Increasing concentrations of carrageenan result in an increased accumulation of inflammatory cells as a result of tissue damage following carrageenan exposure. The increased carrageenan concentrations in this study were consistent with the increased mean inflammatory cell counts (Figure 2) and the histopathological features of edema formation (Figure 1). The results of this study are also consistent with previous studies indicating that some inflammatory cells and edema were observed in the paw tissue of rats after carrageenan injection (Zhang et al., 2013).

Interleukins, such as IL-1, IL-6, IL-12, tumor TNF, interferon, cyclooxygenase, and inducible nitric oxide synthase, are released during the inflammatory process. These cytokines play important roles in the initiation and amplification of inflammatory responses (Calixto et al., 2004). It has been reported that carrageenan injections can trigger acute inflammation due to the influence of various inflammatory mediators (Necas and Bartosikova, 2013). Histamine and serotonin release immediately after induction and decrease after two hours, followed by the release of bradykinin and prostaglandins, and persists in the third hour until the fifth hour after induction (Calixto et al., 2004; Halici et al., 2007). The release of the abovementioned inflammatory mediators affected the increase in the number of inflammatory cells and the expression of inflammatory mediators such as COX-2, COX-1, and IL-6, as well as the histopathological picture in the form of edema in this study.

Injection of 1% carrageenan increased COX-2 expression after 3 hours, according to research conducted by Carvalho et al. (2022). This study demonstrated that carrageenan injection with increased concentrations is in line with the increased expression of COX-2, COX-1, and IL-6 in inflammatory cells. Injection of 4% carrageenan showed a greater number of inflammatory cells expressing COX-2 compared to 1% and 2% carrageenan injections (Figure 4), and this corresponds to the high intensity of COX-2 found in Figure 3D (in the dermal and subcutaneous areas). It is reported that paw edema increased in accordance with the increase in carrageenin concentration (Silva et al., 2010). An increase in inflammatory cells expressing COX-2 after injection of 1-4% carrageenan might be related to the formation of edema and pain around inflammation. A study by Carvalho et al. (2022) reported that neutrophil-derived COX-2 plays an important role in inflammatory pain mediation.

In this study, COX-1 expression is found in the dermis area of normal skin and skin injected with carrageenan. Carrageenan injection at a concentration of 1%-4% increased COX-1 expression by approximately 60% compared to normal skin but did not differ significantly between concentration groups (Figures 5 and 6). COX-1 expressed in the untreated back skin indicates the homeostatic phase prior to inflammatory skin conditions, as previously mentioned by Carvalho et al. (2022).

IL6 is a cytokine that is expressed by cells under stressful conditions such as inflammation, infection, and cancer (Choy and Rose-John, 2017). Carrageenan injection (4%) showed an increase in IL-6 expression in the back skin of mice compared to the carrageenan concentrations of 1% and 2%. IL-6 expression was found in inflammatory cells in the dermal area (Figures 7 and 8). When compared to the expression of COX-2 and COX-1, IL-6 expression appeared to be lower in this study. This is likely due to IL-6 being involved at the beginning of the inflammatory phase, so there is less visible expression in skin tissue compared to COX-2 and COX-1 expressions. In the initial inflammatory phase, the IL-6 concentration increased within 1.5 hours and continued to increase in the next 4 hours after carrageenan injection (Chou, 2003). Increased concentrations of IL-6 facilitate the recruitment of leukocytes and mediate the formation of edema and pain, which are involved in the inflammatory response (Annamalai and Thangam, 2017). In this study, skin samples of the back of mice were taken 6 hours after carrageenan injection in accordance with previous studies (Widyarini et al., 2023). Six hours after injection, carrageenan initiates a cellular phase that will lead to the withdrawal of inflammatory

cells toward the edematous area (Reanmongkol et al., 2009), corresponding to the results of inflammatory cell counts, COX-2 and COX-1 expression in this study.

The results of this study show that an increase in carrageenan concentration affects the number of inflammatory cells and the expression of COX-1, COX-2, and IL-6 in dorsal skin mice. Histopathological appearance of the skin due to subcutaneous injection of carrageenan at various concentrations supports the result of inflammatory cell count and the expressions of COX-1, COX-2, and IL-6. Thus, the back skin of mice could be used for carrageenin-induced acute inflammation models. Moreover, the back skin area is quite easy and stable to measure and/or evaluate inflammatory responses when the test material is topically applied.

CONCLUSION

Carrageenan injections in the back skin of mice showed significantly different amounts of inflammatory cells at concentrations of 1%-4. Expression of inflammatory mediators was seen in the dermis and subcutaneous areas, where COX-2 expression was indicated at the highest level compared to COX-1 and IL-6. Carrageenan induces inflammation in back skin mice and can be used as a model of acute inflammation for evaluating testing material that will be given topically. The results of this study suggest using carrageenin 2% to 4% as an acute skin inflammatory inducer based on its activity in causing tissue damage, the number of inflammatory cells in the exposure area, and the expression of inflammatory mediators COX-2, COX-1, and IL-6.

DECLARATIONS

Funding

Development Grant of the Department of Pathology FKH UGM with BPPTN-BH FKH UGM funds contract number: 985/UN1/FKH/HK4/2022

Availability of data and materials

The authors confirm that the data supporting the findings of this study are available.

Acknowledgments

The researcher and team would like to thank the Faculty of Veterinary Medicine, University Gadjah Mada Yogyakarta, Indonesia, for providing research assistance through the Research Grant year 2022. In addition, current study authors, thank Mr. Yulius Lilik Bintarta for preparing skin tissue sections for histopathological examination.

Authors' contribution

Sitarina Widyarini conceptualized, managed, and supervised the study. Sitarina Widyarini and Sugiyono drafted the manuscript and performed all the experimental procedures. Sitarina Widyarini, Sugiyono, Alsi Dara Paryuni, and Akrom, Alsi Dara Paryuni, conducted data analysis and interpretation. All authors read and approved the final manuscript.

Ethical considerations

The authors carefully examined all ethical issues concerning plagiarism, and double publication, and submission.

Competing interests

The authors declare no conflict of interest concerning the work presented in this report.

REFERENCES

- Annamalai P and Thangam EB (2017). Local and systemic profiles of inflammatory cytokines in carrageenan-induced paw inflammation in rats. *Immunological Investigations*, 46(3): 247-238. DOI: <https://www.doi.org/10.1080/08820139.2016.1248562>
- Ben Khedir S, Mzid M, Bardaa S, Moalla D, Shanoun Z, and Rebai T (2016). *In vivo* evaluation of the antiinflammatory effect of pistacia lentiscus fruit oil and its effects on oxidative stress. *Evidence-Based Complementary and Alternative Medicine*, 2016: 6108203. DOI: <https://www.doi.org/10.1155/2016/6108203>
- Bhattacharyya S, Shumard T, Xie H, Dodda A, Krista A, Varady A, Feferman L, Halline AG, Goldstein JL, Hanauer SB et al. (2017). A randomized trial of the effects of the no-carrageenan diet on ulcerative colitis disease activity. *Nutrition of Healthy Aging*, 4(2): 181-192. Available at: <https://content.iospress.com/articles/nutrition-and-healthy-aging/nha170023>
- Calixto JB, Campos MM, Otuki MF, and Santos ARS (2004). Antiinflammatory compounds of plant origin. Part II. Modulation of pro-inflammatory cytokines, chemokines and adhesion molecules. *Planta Medica*, 70(2): 93-103. DOI: <https://www.doi.org/10.1055/s-2004-815483>
- Carvalho NS, Lemes JBP, Pagliusi JrM, Machado ACDS, Malange KF, Pral LP, Fachi JL, Nishijima CM, Santos GGD, Tambeli CH et al. (2022). Neutrophil-derived COX-2 has a key role during inflammatory hyperalgesia. *Inflammation*, 45: 2280-2293. DOI: <https://www.doi.org/10.1007/s10753-022-01690-5>

- Chou TC (2003). Antiinflammatory and analgesic effects of paeonol in carrageenan-evoked thermal hyperalgesia. *British Journal of Pharmacology*, 139(6): 1146-1152. DOI: <https://www.doi.org/10.1038/sj.bjp.0705360>
- Choy E and Rose-John S (2017). Interlekin-6 as a multifunctional regulator: Inflammation, immune response, and fibrosis. *Journal of Scleroderma Relation Disorder*, 2(2): S1-S5. DOI: <https://www.doi.org/10.5301/jsrd.5000265>
- D’Orazio J, Jarrett S, Amaro-Ortiz A, and Scott T (2013). UV radiation and the skin. *International Journal of Molecular Science*, 14(6): 12222-12248. DOI: <https://www.doi.org/10.3390/ijms140612222>
- Felhi S, Saodi M, Daoud A, Hajlaoui H, Ncir M, Chaabane R, El Feki A, Gharsallah N, and Kadri A (2017). Investigation of phytochemical contents, *in vitro* antioxidant and antibacterial behavior and *in vivo* antiinflammatory potential of *Ecballium elaterium* methanol fruits extract. *Food Science and Technology*, 37(4): 558-563. DOI: <http://www.doi.org/10.1590/1678-457X.26316>
- Halici Z, Dengiz GO, Odabasoglu F, Suleyman H, Cadirci E, and Halici M (2007). Amiodarone has antiinflammatory and anti-oxidative properties: An experimental study in rats with carrageenan-induced paw edema. *European Journal of Pharmacology*, 566(1-3): 215-221. DOI: <https://www.doi.org/10.1016/j.ejphar.2007.03.046>
- Huang SY, Feng CW, Hung HC, Chakraborty C, Chen CH, Chen WF, Jean YF, Wang HMD, Sung CS, Sun YM et al. (2014). A novel zebrafish model to provide mechanistic insights into the inflammatory events in carrageenan-induced abdominal edema. *PLoS One*, 9(8): e104414. DOI: <https://www.doi.org/10.1371/journal.pone.0104414>
- Fehrenbacher JC, Michael RV, and Djane DB (2012). Models of inflammation: Carrageenan- or complete freund’s adjuvant-induced edema and hypersensitivity in the rat. *Current Protocol in Pharmacology*, 56(1): 5-4. DOI: <https://www.doi.org/10.1002/0471141755.ph0504s56>
- Kim HK (2016). Garlic supplementation ameliorates UV-induced photoaging in Hairless mice by regulating antioxidative activity and MMPs expression. *Molecules*, 21(1): 70. DOI: <https://www.doi.org/10.3390/molecules21010070>
- Kot A, Jakubczyk E, Buniowska-Olejnik M, and Kamińska-Dwórznicza A (2023). Effect of iota-carrageenan and its hydrolysates on the stability of milk ice cream mixes. *Polish Journal of Food and Nutrition Science*, 73(2): 196-204. DOI: <http://www.doi.org/10.31883/pjfn/166382>
- Necas J and Bartosikova L (2013). Carrageenan: A review. *Veterinari Medicina*, 58(4): 187-205. DOI: <http://www.doi.org/10.17221/6758-VETMED>
- Pereira L (2018). Seaweeds as a source of bioactive substances and skin care therapy-Cosmeceuticals, algotherapy, and thalassotherapy. *Cosmetics*, 5(4): 68. DOI: <https://www.doi.org/10.3390/cosmetics5040068>
- Posadas I, Bucci M, Roviezzo F, Rossi A, Parente L, Sautebin L, and Cirino G (2004). Carrageenan-induced mouse paw edema is biphasic, aged-weight dependent and displays differential nitric oxide cyclooxygenase-2 expression. *British Journal of Pharmacology*, 142(2): 331-338. DOI: <https://www.doi.org/10.1038/sj.bjp.0705650>
- Reanmongkol W, Noppapan T, and Subhadhirasakul S (2009). Antinociceptive, antipyretic, antiinflammatory activities of *Putranjiva roxburghii* Wal. Leaf extract in experimental animals. *Journal of Natural Medicine*, 63(3): 290-296. DOI: <https://www.doi.org/10.1007/s11418-009-0336-6>
- Silva FRF, Dore CMPG, Marques CT, Nascimento MS, Benevides NMB, Rocha HAO, Chavante SF, and Leite EL (2010). Anticoagulant activity, paw edema and pleurisy induced carrageenan: Action of major types of commercial carrageenans. *Carbohydrate Polymers*, 79(1): 26-33. DOI: <https://www.doi.org/10.1016/j.carbpol.2009.07.010>
- Shafie MH, Kamal M, Zulkiflee FF, HasanS, Uyup NH, Abdullah S, Hussin NAS, Tan YC, and Zafarina Z (2022). Application of carrageenan extract from red seaweed (*Rhodophyta*) in cosmetic products: A review. *Journal of Indonesian Chemistry Society*, 99(9): 100613. DOI: <https://www.doi.org/10.1016/j.jics.2022.100613>
- Shang Q, Sun W, Shan X, Jiang H, Cai C, Hao J, Li G, and Yu G (2017). Carrageenan-induced colitis is associated with decreased population of antiinflammatory bacterium, *Akkermansia muciniphila*, in the gut microbiota of C57BL/6J mice. *Toxicology Letters*, 279: 87-95. DOI: <https://www.doi.org/10.1016/j.toxlet.2017.07.904>
- Suralkar AA, Sarda PS, Ghaisas MM, Thakare V, and Deshpande AD (2008). *In Vivo* animal models for evaluation of antiinflammatory activity. *Pharmaceutical Review*, 6(2): 1-9.
- Szekalska M, Sosnowska K, Tomcrykova M, Winnicka K, Kasacka I, and Tomczyk M (2020). *In vivo* antiinflammatory and anti-allergic activities of cymaroside evaluated by using hydrogel formulations. *Biomedicine and Pharmacotherapy*, 121: 109681. DOI: <https://www.doi.org/10.1016/j.biopha.2019.109681>
- Vysakh A, Jayesh K, Helen LR, Jyothis M, and Latha MS (2020). Acute oral toxicity and antiinflammatory evaluation of methanolic extract of *Rotua aquatica* roots in Wistar rats. *Journal of Ayurveda and Integrative Medicine*, 11(1): 45-52. DOI: <https://www.doi.org/10.1016/j.jaim.2017.09.007>
- Wang X, Fang Y, Liang W, Liang M, Xu L, and Yu J (2023). DDF2022-ABS-0253 dietary additive carrageenan metabolized by human GUT microbiota and promoting colorectal cancer. *Basic Gastroenterology*, 71(2): A66. DOI: <http://www.doi.org/10.1136/gutjnl-2022-IDDF.79>
- Wei W, Feng W, Xin G, Niu Tingting N, Zhanghe Z, Haimina C, and Xiaojun Y (2016). Enhanced effect of κ -carrageenan on TNBS-induced inflammation in mice. *International Immunopharmacology*, 39: 218-228. DOI: <http://www.doi.org/10.1016/j.intimp.2016.07.031>
- Widyarini S, Spinks N, Husband AJ, and Reeve VE (2001). Isoflavonoid compounds from red clover (*Trifolium pratense*) protect from inflammation and immune suppression induced by UV radiation. *Photochemistry and Photobiology*, 74(3): 465-470. DOI: [https://www.doi.org/10.1562/0031-8655\(2001\)074<0465:icfrct>2.0.co;2](https://www.doi.org/10.1562/0031-8655(2001)074<0465:icfrct>2.0.co;2)
- Widyarini S, Domanski D, Painter N, and Reeve VE (2006). Estrogen receptor signaling protects against immune suppression by UV radiation exposure. *Proceeding National Academic Science*, 103(34): 12837-12842. DOI: <https://www.doi.org/10.1073/pnas.0603642103>

- Widyarani S, Sugiyono, Kristianingrum YP, Sutrisno B (2023). Pembuatan model inflamasi topikal pada kulit mencit dengan karagenin [Creating a topical inflammation model in mouse skin with carrageenin]. *Jurnal Sain Veteriner*, 41(1): 88-97. DOI: <https://www.doi.org/10.22146/jsv.62689>
- Wu W, Wang F, Gao X, Niu T, Zhul X, Yan X, and Chen H (2016). Synergistic effect of κ -carrageenan on oxazolone-induced inflammation in BALB/c mice. *BMC Gastroenterology*, 16: 41. DOI: <https://www.doi.org/10.1186/s12876-016-0459-7>
- Wu W, Zhen Z, Niu T, Zhu X, Gao Y, Yan J, Chen Y, Yan X, and Chen H (2017). κ -Carrageenan enhances lipopolysaccharide-induced interleukin-8 secretion by stimulating the Bcl10-NF- κ B pathway in HT-29 cells and aggravates *C. freundii*-induced inflammation in mice. *Mediators of Inflammation*, 2017: 8634865. DOI: <https://www.doi.org/10.1155/2017/8634865>
- Zhang J, Wang H, Wang T, Chong Y, Yu P, Lu C, Xue Y, Fu F, and Zhang L (2013). Antiinflammatory activity of Yanshu spraying agent in animal models. *Experimental and Therapeutic Medicine*, 5(1): 73-76. DOI: <https://www.doi.org/10.3892%2Fetm.2012.761>
- Zhang X, Retyunskiy V, Qiao S, Zhao Y, and Chi-Meng T (2022). Alloferon-1 ameliorates acute inflammatory responses in λ -carrageenan-induced paw edema in mice. *Scientific Reports*, 12: 16689. DOI: <https://www.doi.org/10.1038/s41598-022-20648-z>

Publisher's note: Scienceline Publication Ltd. remains neutral with regard to jurisdictional claims in published maps and institutional affiliations.



Open Access: This article is licensed under a Creative Commons Attribution 4.0 International License, which permits use, sharing, adaptation, distribution and reproduction in any medium or format, as long as you give appropriate credit to the original author(s) and the source, provide a link to the Creative Commons licence, and indicate if changes were made. The images or other third party material in this article are included in the article's Creative Commons licence, unless indicated otherwise in a credit line to the material. If material is not included in the article's Creative Commons licence and your intended use is not permitted by statutory regulation or exceeds the permitted use, you will need to obtain permission directly from the copyright holder. To view a copy of this licence, visit <https://creativecommons.org/licenses/by/4.0/>.

© The Author(s) 2023