



# Ultrasonography Examination of the Kidney in Bali Cattle

I Wayan Nico Fajar Gunawan<sup>1\*</sup> , Putu Devi Jayanti<sup>1</sup> , Anak Agung Gde Oka Dharmayudha<sup>1</sup> ,  
Wayan Sukernayasa<sup>2</sup> , and I Ketut Puja<sup>3</sup> 

<sup>1</sup>Laboratory of Veterinary Clinical Diagnostic, Clinical Pathology and Radiology, Faculty of Veterinary Medicine, Udayana University, Bali, 80361, Indonesia

<sup>2</sup>Laboratory of Veterinary Reproduction, Faculty of Veterinary Medicine, Udayana University, Bali, 80361, Indonesia

<sup>3</sup>Laboratory of Veterinary Genetics and Reproduction Technology, Faculty of Veterinary Medicine, Udayana University, Bali, 80361, Indonesia

\*Corresponding author's Email: nico\_fajar\_g@unud.ac.id

## ABSTRACT

Ultrasonography is an important technology for examining renal measurements, including length and width. The kidneys can be easily examined, and various structures in the kidneys are distinguishable with ultrasound. This research aimed to determine the normal ultrasonographic appearance of the kidneys in healthy adult Bali cattle, providing a reference for future descriptions of Bali cattle kidneys. In this research, 8 Bali cattle, aged 2-3 years with the healthy status of the urinary system were examined. The tool used was an animal ultrasound device, named Mindray DP10 Veterinary Ultrasound, with a 3-7.5 MHz convex transducer, utilizing a B-mode image mode. The transducer was placed in the right paralumbar fossae. The results indicated that the average horizontal length of the kidneys was 17.36 cm and the average vertical diameter of the kidney was 4.6 cm. The echogenicity of the renal cortex showed an echoic image, while the pyramidal part of the renal medulla indicated a relatively hypoechoic image. The results of measuring the diameter of the left kidney in clinically healthy Bali cattle could be used as a basis for decision-making in determining the clinical status of kidney health in this breed of cattle.

**Keywords:** Bali cattle, Echogenicity, Kidney, Morphology, Morphometric data, Ultrasound examination

## INTRODUCTION

Ultrasonography is one of the most widely used diagnostic imaging methods in clinical practice. It is a non-invasive examination tool used in both human and veterinary practices (Barreiro-Vázquez et al., 2021). Ultrasonography is cost-effective and can be carried out in the veterinary field on both small animals (Utomo et al., 2023) and large animals (Eibl and Franz, 2021). Ultrasonography has been increasingly used in large animal clinical practice and surgery. Its use has been increasing in large animal clinical practice and surgery. While most ultrasound examinations in livestock focus on pregnancy (Szenci, 2021), digestion (Khalphallah et al., 2021), and respiration (Berman et al., 2019; Cuevas-Gómez., 2021), there is a growing trend toward using ultrasonography for kidney examination (Barreiro-Vázquez et al., 2021; Tharwat, 2021).

Knowledge of the bovine kidneys' anatomy and topography relative to the body cavity is very important for veterinarians, particularly for clinical examination of the kidney, including laparotomy examination and laparoscopy/ultrasound-guided biopsy (Imran and Sharma, 2014). The use of ultrasound for assessing renal anatomy is straightforward (Hansen et al., 2016). Ultrasonography aids veterinarians in diagnosing morphologic changes in the kidney (Seif and Bark, 2007), detecting kidney disorders (Debruyne et al., 2012), diagnosing infections in the upper or lower urinary tract (Floek, 2009) and urinary system diseases in cows (Öztürk et al., 2005), measuring kidney volume, and assessing the kidney architectural appearance (Bappah et al., 2019). Additionally, ultrasound imaging is now used for the physiological examination of kidney blood flow (Barreiro-Vázquez et al., 2021).

The bovine kidneys, especially the left kidney can be mobile. This mobility is likely due to pressure exerted by the full rumen. Kidney morphology in cattle can change with the seasons, such as in summer, when heat stress affects glomerular and tubular function, as well as urine concentration (Akosman et al., 2018). Cow kidneys have a lobed shape and can be microscopically divided into three layers: the capsule, parenchyma, and renal pelvis. The kidneys are covered by a thin, light brown capsule. The parenchyma layer is divided into two parts, including the outer part, called the cortex, and the inner part called the medulla (Ishaya et al., 2021). In terms of anatomical location, cows have a right and a left kidney. The right kidney in cows is located in the abdominal cavity between the last rib and the transverse process of the 2nd to 3rd lumbar vertebrae, appearing more cranial compared to the left kidney (Braun, 1991; Barreiro-Vázquez et al.,

ORIGINAL ARTICLE  
Received: March 19, 2024  
Revised: April 24, 2024  
Accepted: May 20, 2024  
Published: June 25, 2024

2021). The left kidney, positioned slightly lower than the right kidney, can move medially depending on the ruminal filling (Braun, 1993).

Some imaging techniques for assessing kidney size and shape in humans and animals include magnetic resonance imaging, ultrasonography, contrast studies, radiography, computed tomography, and renal scintigraphy (Caroli et al., 2021). The introduction of routine abdominal ultrasound examination in large animals has resulted in various methods for estimating kidney size and volume with this modality, including using volumetric formulas based on maximum kidney length (Hussein et al., 2018).

Ultrasonography is used to assess the anatomy of the kidney, including shape and size (length, width, and thickness). Ultrasonography identifies the echogenicity of the renal parenchyma as well as details changes in the collecting system. These details help in identifying the extent of renal parenchymal damage and its possible reversibility (Ahmed et al., 2019). Additionally, ultrasonography examines the renal cortex and parenchyma (Stankiewicz et al., 2023) and complements the physical examination and clinical pathology evaluation by providing additional information about the disease.

Kidney ultrasound examination can identify primary abnormalities and differentiate between normal and abnormal conditions that often cause abdominal pain. Common urological diseases in cattle, such as urolithiasis, which result in significant economic losses for the livestock industry because they are considered the fifth most common cause of death, require ultrasonography of the kidneys for diagnostic purposes (Dangi et al., 2022). Ultrasonography can provide information on urinary system diseases, such as the size, structure, and position of the kidney and bladder parenchyma (Tharwat, 2021).

Routine ultrasound use in cattle is currently very limited, especially in Bali cattle. Bali cattle are the indigenous to Indonesia and play an important role in livestock development in Indonesia (Puja et al., 2018). They are directly domesticated from wild bulls that still live in the Baluran National Park area in East Java (Martoyo, 2012). Bali cattle are known for their strong energy and the presence of horns on cows, coupled with their wild temperament, which necessitates special techniques or skills in handling. There is currently no reference available regarding the morphology of Bali cattle kidneys through ultrasound examination, using the transcutaneous method. This study aimed to describe the kidney morphology of Bali cattle through ultrasound examination. The data obtained from this study can help veterinary practitioners in the diagnosis of healthy Bali cattle kidneys.

## MATERIALS AND METHODS

### Ethical approval

This research has been approved by the Animal Ethic Committee Faculty of Veterinary Medicine Udayana University, Bali, Indonesia with approval number: B/98/UN14.2.9/PT.01.04/2024.

### Animal samples

Eight Bali cattle, aged 2-3 years, weighed approximately 250 to 300 kg, raised at the Bali cattle breeding center, Sobangan Badung, Bali Indonesia, were selected for the study. The animals were kept under standard conditions of feeding and management. The animal is clinically healthy and has no history of pathological disorders, especially in the urinary tract based on the result of clinical examination from a veterinarian. The cows were female and not pregnant. The average body condition score was three on a five-point scale. The morphometric data was taken from post-mortem kidneys at the Pesanggaran Denpasar, Bali, Indonesia slaughterhouse in the dry season.

### Ultrasound examination

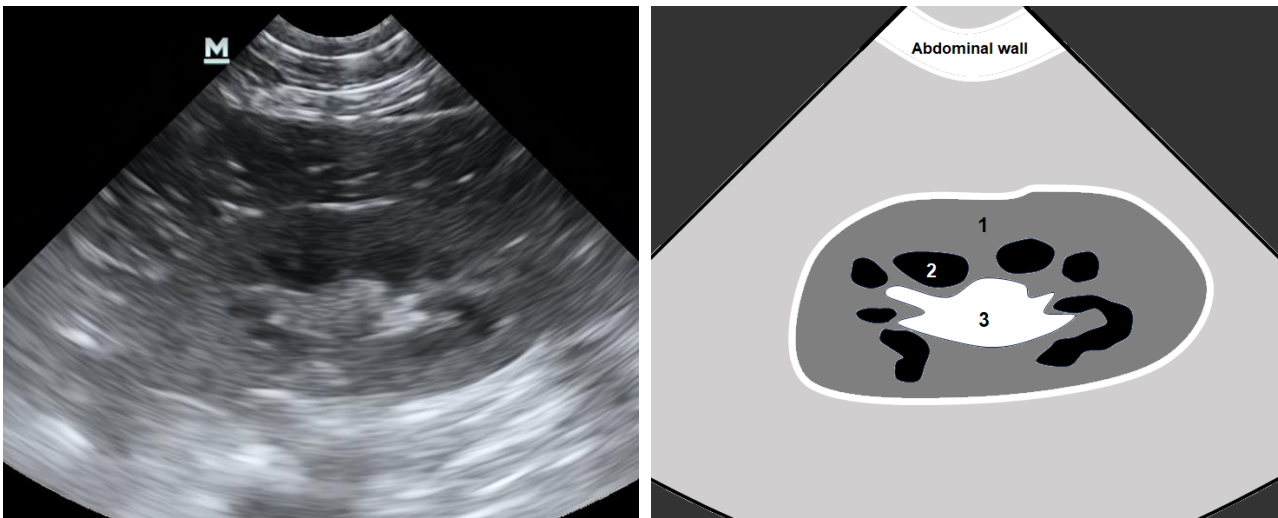
The equipment utilized for this study was the Mindray DP 10 Veterinary Ultrasound (Germany), specifically designed for animal, equipped with a 3-7.5 MHz convex transducer. The image mode employed was B-mode, displayed on a 10-inch LCD. Ultrasound observations of the kidneys were carried out on the right paralumbar fossa where the hair was shaved first. Animals were positioned in a standing position without sedation. The cow is not given food or water for at least 12 hours before the examination. After adding the gel, the transducer is placed longitudinal plane on the dorsal part of the abdomen. The right and left kidneys were measured, and their internal structures, such as renal parenchyma, and echotexture of the kidney were examined (Floeck, 2009).

### Data analysis

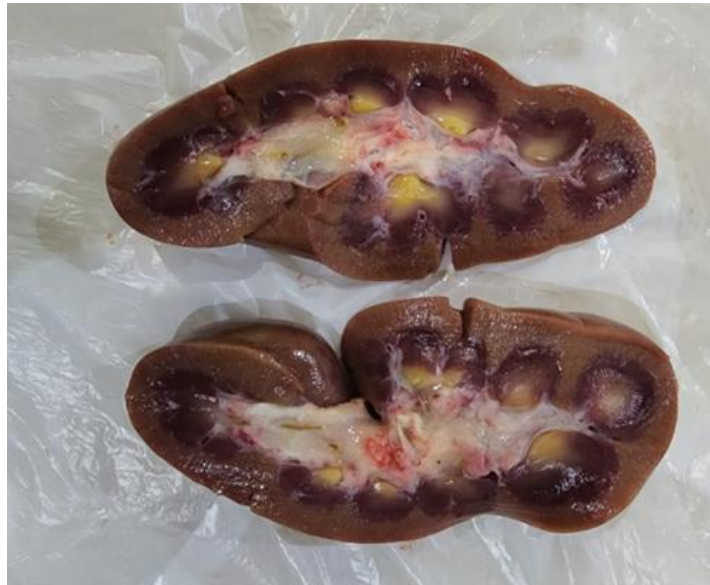Data from ultrasound examination results were tabulated and analyzed descriptively. The results of the vertical and horizontal diameter of the kidney are presented as means and standard deviations. All statistical tests were conducted using IBM SPSS for Windows v.26.

## RESULTS

Ultrasonography was performed on eight cows that were clinically healthy and not anesthetized, with imaging focused on the kidneys from the paralumbar area. While the left kidney exhibited a clear, oval appearance (Figure 1), the right kidney appeared less distinctly visible. Adjacent organs, including the large intestine and medial rumen wall, were visible alongside the left kidney. The left kidney structure image showed distinct echotexture in the ultrasound images. The renal cortex indicated an echoic image, while the pyramidal part of the renal medulla revealed a relatively hypoechoic image. In the kidney, the renal sinus section showed a hyperechoic image. A total of 15 pairs of right and left kidneys were measured to obtain kidney morphometric data for Bali cattle (Figure 2). Measurement results of the horizontal diameter of the kidneys of Bali cattle yielded an average of  $17.36 \pm 0.71$  cm. The average diameter of Bali cattle kidney vertices was  $4.6 \pm 0.33$  cm (Table 1). The vertical diameter of the kidney was much smaller than the horizontal diameter.



**Figure 1.** Longitudinal ultrasound image of left kidney in a 2-year-old female Bali cattle. **1:** Renal cortex; **2:** Medullary pyramid; **3:** Renal sinus



**Figure 2.** Morphology of three years old female Bali cattle (left kidney)

**Table 1.** The average size of Bali cattle kidney

Variable	N	Max	Min	Mean $\pm$ SD
Length (cm)	15	18.2	16.3	$17.36 \pm 0.71$
Vertical diameter (cm)	15	5.1	4.2	$4.6 \pm 0.33$

N: Number. SD: standard deviation.

## DISCUSSION

This study represented the first report to describe the kidney morphology of healthy, non-pregnant Bali cattle using the transcutaneous ultrasonography method. These findings can be useful as a basis for further research comparing normal Bali cattle and sick Bali cattle. Transcutaneous ultrasonography images at the dorsal abdominal location succeeded in depicting the size and appearance of the kidney structure of Bali cattle. However, the ultrasound image of the right kidney cannot be clearly imaged.

The obtained results of the current study differed from the study conducted by [Katsoulos et al. \(2020\)](#), indicating that the image of the right kidney in Holstein cows can be recognized, compared to the left kidney. The right kidney lobes of the Holstein cow can be examined using ultrasonography, but the cortex and medulla cannot be clearly distinguished ([Braun, 1991](#)).

In this study, the echo patterns of the kidney structures, including the renal pyramids, and renal parenchyma were identified through different echogenic images. This research aligns with the report of [Seif and Bakr \(2007\)](#), who indicated the parenchyma and renal pyramids, could be observed with different echotexture. The results of imaging of the left kidney in Bali cattle were similar to the results of imaging carried out by [Braun \(1993\)](#) on Swiss Braunvieh cattle evaluated from the echogenicity of renal parenchyma and medullary pyramids. The left kidney in cattle can be imaged well using ultrasonography. Changes in the echo pattern of the structure of the left kidney may occur due to the presence of the rumen ([Akosman et al., 2018](#)). The left kidney position often varies depending on rumen distension. It can be located from the midline to the right stomach and rotated to varying positions, sometimes even in contact with the abdominal wall ([Barreiro-Vázquez et al., 2021](#)).

The results of this study showed that the average horizontal diameter of the kidney in Bali cattle ranged from 16.31 to 18.2 cm, while the width of the kidney in Bali cattle ranged from 4.2 to 5.1 cm with an average of 4.2 cm. The measurement results between individuals were similar, due to the similar age and Body Condition Score (BCS) of the examined cows. Comparatively, the average kidney size of Bali cattle fell below that of other breeds. For instance, Limousin-Cross cattle exhibited an average length of 19.63 cm in length and 10.11 cm in width ([Katsoulos et al., 2020](#)), while Holstein Friesian cattle typically ranged from 19-26 cm in length and 6.90 cm in width ([Barreiro-Vázquez et al., 2020](#)). This result indicated that differences in kidney size in other studies may be due to differences in the cattle breeds used. Breed and age are significant factors influencing cattle kidney size ([Seif and Bakr, 2007](#); [Katsoulos et al., 2020](#)). The kidney shape of Bali cattle tended to be smoother at the margins, compared to Holstein cattle. Moreover, the lobes were less visible, compared to other cattle breeds, such as Holstein and Limousin-Cross ([Katsoulos et al., 2020](#)).

In this study, the renal cortex showed an echoic image, while the pyramidal part of the renal medulla showed a relatively hypoechoic image. The current study results are in accordance with echo patterns in healthy Jersey/Red Sindhi crossbred cows, were reported by [Imran and Sharma \(2014\)](#). Ultrasound regularly uses a subjective assessment of relative organ echogenicity, visual perception of echogenicity results from ultrasonic back reflection and attenuation ([Stankiewicz et al., 2023](#)).

In Bali cattle, ultrasonography images showed differences in echogenicity between the cortex and the medulla. The renal cortex showed a hypoechoic image, while the pyramidal part of the renal medulla indicated a relatively less echogenic image, compared to the cortex. These echogenicity patterns observed in the left kidney of Bali cattle mirror those documented in the left kidney of Swiss Braunvieh cattle, indicating consistent differences in the echogenicity of the kidney structure ([Braun, 1993](#)). The echogenicity pattern of renal lobulation can be visualized by ultrasonography. Various structures in the kidney, such as the renal cortex and renal medullary pyramids can show differences in echogenicity. The renal cortex is more echogenic, compared to renal medullary pyramids ([Seif and Bakr, 2007](#)). However, the thickness of the renal cortex of Bali cattle is smaller than Swiss Braunvieh. This can be the result of the difference in the size of the cows. Bali cattle is relatively smaller than most other cows, such as Holstein, Brown Swiss, and Jersey. The renal size is correlated with the body size of the cow ([Seif and Bakr, 2007](#)).

## CONCLUSION

From the present results, ultrasonography images of Bali cattle's dorsal abdomen can be used to image the left kidney. The vertical diameter of the kidney is much smaller than that of the horizontal diameter. The horizontal diameter of the kidneys of Bali cattle was an average of  $17.36 \pm 0.71$  cm and the average diameter of the kidney vertices was  $4.6 \pm 0.33$  cm. The results of measuring kidney diameter can be used as a reference for diagnosing changes in Bali cattle's kidney morphology. Further studies involving healthy Bali cattle and Bali cattle with urinary system disease are required to establish the difference between healthy and damaged kidney ultrasound imaging.



## DECLARATIONS

### Acknowledgments

The authors thank the Faculty of Veterinary Medicine at Udayana University and the Institute for Research and Community Service for funding. Also, the Sobangan Bali Cattle Breeding Center Badung Regency's staff supported this research.

### Funding

This research was funded by the Institute for Research and Community Service, Udayana University, Bali Indonesia with funding grant no: B/78.995/UN14.4. A/PT.01.03/2022.

### Authors' contributions

I Wayan Nico Fajar Gunawan designed the research and drafted and finalized the manuscript, Putu Devi Jayanti and I Wayan Sukernayasa collected the data, Anak Agung Gde Oka Dharmayudha analyzed the data, and I Ketut Puja reviewed and finalized the manuscript. All authors reviewed and confirmed the final manuscript.

### Competing interests

The authors declare there are no conflicts of interest.

### Availability of data and materials

The authors confirm that all data supporting the findings of this research are available upon reasonable request.

### Ethical considerations

This article is not submitted anywhere else, and the findings are analyzed and written under the supervision of all authors. All authors wrote the article and checked the last draft of the manuscript for the similarity index.

## REFERENCES

- Ahmed S, Bughio S, Hassan M, Lal S, and Ali M (2019). Role of ultrasound in the diagnosis of chronic kidney disease and its correlation with serum creatinine level. *Cureus*, 11(3): e4241. DOI: <https://www.doi.org/10.7759%2Fcurious.4241>
- Akosman MS, Türkmenoğlu I, Demirkan AC, Özdemir V, and Akalan MA (2018). Morphological effects of heat stress on cattle kidney. *Journal of Morphological Sciences*, 35(2): 122-124. DOI: <https://www.doi.org/10.1055/s-0038-1669431>
- Bappah MN, Awasum CA, Chom ND, Lawal M, Bello UM, Bada AA, Idris SY, and Ochube GE (2019). Correlation of ultrasonographic renal volume with modified body mass index in Nigerian indigenous dogs. *Sokoto Journal of Veterinary Sciences*, 17(3): 9-16. DOI: <https://www.doi.org/10.4314/sokjvs.v17i3.2>
- Barreiro-Vázquez JD, Miranda M, and Barreiro-Lois A (2021). Transabdominal renal doppler ultrasound in healthy adult Holstein-friesian cows: A pilot study. *Animals*, 11(1): 63. DOI: <https://www.doi.org/10.3390/ani11010063>
- Berman J, Francoz D, Dufour S, and Buczinski S (2019). Bayesian estimation of sensitivity and specificity of systematic thoracic ultrasound exam for diagnosis of bovine respiratory disease in pre-weaned calves. *Preventive Veterinary Medicine*, 162: 38-45. DOI: <https://www.doi.org/10.1016/j.prevetmed.2018.10.025>
- Braun U (1993). Ultrasonographic examination of the left kidney, the urinary bladder, and the urethra in cows. *Journal of Veterinary Medicine Series A*, 40(1-10): 1-9. DOI: <https://www.doi.org/10.1111/j.1439-0442.1993.tb00594.x>
- Braun U (1991). Ultrasonographic examination of the right kidney in cows. *American Journal of Veterinary Research*, 52(12): 1933-1939. DOI: <https://www.doi.org/10.2460/ajvr.1991.52.12.1933>
- Caroli A, Remuzzi A, and Lerman LO (2021). Basic principles and new advances in kidney imaging. *Kidney International*, 100(5): 1001-1011. DOI: <https://www.doi.org/10.1016/j.kint.2021.04.032>
- Cuevas-Gómez I, McGee M, Sánchez JM, O'Riordan E, Byrne N, McDanel T, and Earley B (2021). Association between clinical respiratory signs, lung lesions detected by thoracic ultrasonography and growth performance in pre-weaned dairy calves. *Irish Veterinary Journal*, 74(1): 7. DOI: <https://www.doi.org/10.1186/s13620-021-00187-1>
- Dangi A, Kumar S, Sharma M, Chaudhary RN, and Niwas R (2022). Study of urine analysis in ultrasound-guided and conventional tube cystostomy for surgical management of urine retention in male buffalo calves. *The Pharma Innovation*, SP11(5): 1700-1703. Available at: <https://www.thepharmajournal.com/archives/2022/vol11issue5S/PartW/S-11-3-176-910.pdf>
- Debruyne K, Haers H, Combes A, Paepe D, Peremans K, Vanderperren K, and Saunders JH (2012). Ultrasonography of the feline kidney: Technique, anatomy and changes associated with disease. *Journal of Feline Medicine and Surgery*, 14(11): 794-803. DOI: <https://www.doi.org/10.1177/1098612X12464461>
- Eibl C and Franz S (2021). Ultrasonography of kidney and spleen in clinically healthy llamas and alpacas. *Acta Veterinaria Scandinavica*, 63: 4. DOI: <https://www.doi.org/10.1186/s13028-021-00571-5>
- Floek M (2009). Ultrasonography of bovine urinary tract disorders. *Veterinary Clinics: Food Animal Practice*, 25(3): 651-667. DOI: <https://www.doi.org/10.1016/j.cvfa.2009.07.008>

- Hansen KL, Nielsen MB, and Ewertsen C (2016). Ultrasonography of the kidney: A pictorial review. *Diagnostics*, 6(1): 2. DOI: <https://www.doi.org/10.3390/diagnostics6010002>
- Hussein HA, Ibrahim A, and Ali MF (2018). Ultrasonographic Reference Values of Kidney dimensions and clinicopathological findings associating the transcutaneous ultrasound-guided renal biopsy in donkeys (*Equus asinus*). *Journal of Equine Veterinary Science*, 68: 1-11. DOI: <https://www.doi.org/10.1016/j.jevs.2018.04.001>
- Imran S and Sharma S (2014). Transcutaneous ultrasonographic examination of the left kidney in healthy cows. *Veterinami Medicina*, 59(1): 29-32. Available at: [https://vetmed.agriculturejournals.cz/artkey/vet-201401-0004\\_transcutaneous-ultrasonographic-examination-of-the-left-kidney-in-healthy-cows.php](https://vetmed.agriculturejournals.cz/artkey/vet-201401-0004_transcutaneous-ultrasonographic-examination-of-the-left-kidney-in-healthy-cows.php)
- Ishaya L, DibaL NI, Chiroma SM, and Attah MOO (2021). Comparative anatomical study of the kidneys in cattle (*Bos taurus*) and camel (*Camelus dromederus*). *Journal of Morphological Sciences*, 38: 386-391. Available at: [https://www.jms-sba.com/files/ugd/cb512e\\_167cc655280147c0b5752cd51e0a2b92.pdf](https://www.jms-sba.com/files/ugd/cb512e_167cc655280147c0b5752cd51e0a2b92.pdf)
- Katsoulos PD, Athanasiou LV, Dedousi A, Psalla D, Marouda C, Papchianou M, and Boscoc C (2020). Morphometrical study of bovine kidneys with and without mild histological lesions. *Morphologie*, 104(346): 169-173. DOI: <https://www.doi.org/10.1016/j.morpho.2020.01.001>
- Khalphallah A, Elsayed HK, Elmeligy E, Bayomi SA, Hamed MA, Salman D, and Mousa SA (2021). Differential diagnosis of bovine intestinal diseases and their sequelae regarding ultrasonography and other diagnostic tools. *Veterinary World*, 14(6): 1537. DOI: <https://www.doi.org/10.14202%2Fvetworld.2021.1537-1547>
- Martojo H (2012). Indigenous Bali cattle is most suitable for sustainable small farming in Indonesia. *Reproduction in Domestic Animals*, 47(s1): 10-14. DOI: <https://www.doi.org/10.1111/j.1439-0531.2011.01958.x>
- Öztürk S, Demirkan I, Kibar M, Bumin A, and Pekmaya S (2005). Transrectal ultrasonographic examination of the urinary system in Holstein cows. *Turkish Journal of Veterinary & Animal Sciences*, 29(2): 263-267. Available at: <https://journals.tubitak.gov.tr/veterinary/vol29/iss2/11/>
- Puja IK, Sulabda IN, and Wandia IN (2018). Microsatellite polymorphisms and its relationship with calving interval and gestation period in Bali cattle. *Advances in Animal and Veterinary Sciences*, 6(5): 197-200. DOI: <http://www.doi.org/10.17582/journal.aavs/2018/6.5.197.200>
- Seif MM and Bakr HA (2007). Ultrasonography of normal, cystic and dysplastic kidney in cattle. *Journal of Veterinary Medical Research*, 17(2): 42-49. DOI: <https://www.doi.org/10.21608/jvmr.2007.77911>
- Stankiewicz T, Błaszczuk B, and Chundekkad P (2023). Ultrasound evaluation of biometric and Doppler parameters of kidneys in sheep in the prenatal and postnatal periods. *Small Ruminant Research*, 219: 106891. DOI: <https://www.doi.org/10.1016/j.smallrumres.2022.106891>
- Szenci O (2021). Recent possibilities for the diagnosis of early pregnancy and embryonic mortality in dairy cows. *Animals*, 11(6): 1666. DOI: <https://www.doi.org/10.3390/ani11061666>
- Tharwat M (2021). Clinical, ultrasonographic, and postmortem findings in sheep and goats with urinary tract disorders. *Veterinary World*, 14(7): 1879-1887. DOI: <https://www.doi.org/10.14202%2Fvetworld.2021.1879-1887>
- Utomo BGR, Puja IK, and Gunawan IWNF (2023). Dynamic of vaginal pH and ovary ultrasound imaging of Kintamani Bali bitch during proestrus to estrus phase. *International Journal of Veterinary Science*, 12(3): 242-247. DOI: <https://www.doi.org/10.47278/journal.ijvs/2022.171>

**Publisher's note:** [Scienceline Publication](#) Ltd. remains neutral with regard to jurisdictional claims in published maps and institutional affiliations.



**Open Access:** This article is licensed under a Creative Commons Attribution 4.0 International License, which permits use, sharing, adaptation, distribution and reproduction in any medium or format, as long as you give appropriate credit to the original author(s) and the source, provide a link to the Creative Commons licence, and indicate if changes were made. The images or other third party material in this article are included in the article's Creative Commons licence, unless indicated otherwise in a credit line to the material. If material is not included in the article's Creative Commons licence and your intended use is not permitted by statutory regulation or exceeds the permitted use, you will need to obtain permission directly from the copyright holder. To view a copy of this licence, visit <https://creativecommons.org/licenses/by/4.0/>.