



Soft Tissue Sarcomas in Cats: A Comparative Review on Injection-Site and Non-Injection-Site Sarcomas

Carolina Wright¹, Claudio Gustavo Barbeito^{2,4}, Carolina Natalia Zanuzzi^{2,4}, Adriana Graciela Duchene³, Francisco Acuña^{2,4}, and Olga Andrea Santelices Iglesias¹

¹Laboratorio de Análisis de Imágenes, Facultad de Ciencias Veterinarias, Universidad Nacional de La Plata, 60 y 118, La Plata 1900, Argentina

²Laboratorio de Histología y Embriología Descriptiva, Experimental y Comparada, Facultad de Ciencias Veterinarias, Universidad Nacional de La Plata, 60 y 118, La Plata 1900, Argentina

³Laboratorio Veterinario de Diagnóstico Histopatológico, Ciudad Autónoma de Buenos Aires C1419DPB, Argentina
⁴CONICET (Consejo Nacional de Investigaciones Científicas y Técnicas), Argentina

*Corresponding author's Email: barbeito@fcv.unlp.edu.ar

ABSTRACT

Malignant tumors originating in connective tissue cells of mesenchymal origin are considered soft tissue sarcomas. Soft tissue sarcomas represent between 7%-9% of malignant tumors of the skin and subcutaneous tissue in cats. Among the sarcomas affecting cats, there is a specific group known as inoculation site-associated sarcomas. Sarcomas that do not occur at sites typically used for the injection of substances will be classified in this review as non-inoculation site-associated sarcomas. Fibrosarcoma is the most common histological type and accounts for 80–92% of soft tissue sarcomas in cats. The prevalence of non-inoculation site sarcomas in cats is 17 in 100,000, while the prevalence of inoculation site sarcomas is estimated to be between 1 in 1,000 and 1 in 10,000 vaccinated cats. The present study aimed to compare the information present in the available literature in relation to the morphological characteristics, biological behavior, pathogenesis, diagnosis, and treatment of both inoculation site-associated and non-associated sarcomas in cats. A more complete understanding of these neoplasms and their differences is essential to deepen the understanding of their genesis and progression. A better understanding could lead to the development of more effective intervention strategies that improve the quality of life and survival of cats affected by these sarcomas.

Keywords: Feline sarcoma, Inoculation site, Oncology, Soft tissue sarcoma, Vaccination

INTRODUCTION

Soft tissue sarcomas are malignant neoplasms that originate from mesenchymal cells. These tumors can arise from various anatomical sites and have different cellular origins (Dernell et al., 1998; Dobromylskyj et al., 2021; Dobromylskyj, 2022). However, since their histological characteristics and biological behavior are similar, both groups of sarcomas are studied together (Soto et al., 2024).

Soft tissue sarcomas include the following tumors: Fibrosarcomas, myxosarcomas, peripheral nerve sheath tumors, perivascular wall tumors, undifferentiated sarcomas, pleomorphic sarcomas, and liposarcomas (Dobromylskyj et al., 2021; Zajc et al., 2022). Soft tissue sarcomas present an expansile or infiltrative growth pattern (Dobromylskyj et al., 2021; Ludwig et al., 2022). They are usually pseudoencapsulated with poorly defined histological margins, and their recurrence rate after surgical excision can vary from low to moderate, and even high in some cases (Zajc et al., 2022). Soft tissue sarcomas represent 7%–9% of malignant tumors of the skin and subcutaneous tissue in cats (Dobromylskyj et al., 2021).

Among the sarcomas that affect cats, there is a specific group of tumors known as injection site-associated sarcomas (ISS) (Kliczkowska et al., 2015). Sarcomas associated with inoculation sites were first described in the early 1990s in the United States, specifically in Pennsylvania. At that time, an increase in the incidence of sarcomas in cats at the sites used for vaccine-inoculation was noted, coinciding with the implementation of mandatory rabies vaccination protocols (Hendrick et al., 1992). Years later, the diagnosis of ISS has expanded worldwide, in countries such as Australia, the United Kingdom, and Italy (Carminato et al., 2011; Dean et al., 2012; Saba, 2017).

Sarcomas that are not located at anatomical sites routinely used for the inoculation of substances are considered in this review as non-injection site-associated sarcomas (NISS). Although it is difficult to differentiate these two groups of tumors, ISS has some distinctive characteristics. Sarcomas associated with inoculation sites in cats occur in younger animals (mean age 8 years) than NISSs (mean age 11 years). Unlike ISSs and NISSs, feline sarcoma virus (FeSV)-

REVIEW ARTICLE
Received: March 24, 2025
Revised: April 28, 2025
Accepted: May 19, 2025
Published: June 25, 2025

induced fibrosarcoma occurs in very young animals, with an average age of 3 years, or even a few months. These tumors are usually multicentric, can metastasize, and their clinical progression is rapid (Hendrick *et al.*, 1992; Dobromylskyj, 2022). ISSs are more aggressive and have a higher recurrence rate than NISSs (Deim *et al.*, 2008; Löhr *et al.*, 2021; Zajc *et al.*, 2022). None of these tumors shows sexual or racial predilection (Hendrick *et al.*, 1994; Dobromylskyj *et al.*, 2021).

Fibrosarcoma is the most common of both types of sarcomas in cats (ISS and NISS), accounting for 80-92% of cases. Fibrosarcoma is among the most commonly diagnosed tumors of the skin and soft tissues of domestic cats (Dobromylskyj, 2022). It is a highly aggressive tumor, with high recurrence and mortality rates (Hendrick *et al.*, 1992; Wilcock *et al.*, 2012; Dobromylskyj *et al.*, 2021). Other histological types, including undifferentiated pleomorphic sarcoma (formerly known as malignant fibrous histiocytoma), osteosarcoma, chondrosarcoma, and rhabdomyosarcoma, can be found less frequently in cats (Wilcock *et al.*, 2012; Avallone *et al.*, 2021).

The aim of the present study was to compare the information present in the available literature in relation to the morphological characteristics, biological behavior, pathogenesis, diagnosis, and treatment of both inoculation site-associated and non-associated sarcomas in cats. A more complete understanding of these neoplasms and their differences is essential to deepen the understanding of their genesis and progression. A better understanding could lead to the development of more effective intervention strategies that improve the quality of life and survival of cats affected by these sarcomas.

MATERIALS AND METHODS

This review was conducted on soft tissue sarcomas in felines through an exhaustive search of open-access bibliographic resources available in recognized scientific databases, such as PubMed, Scopus, Web of Science, Google Scholar, and SciELO. More than 100 academic articles were analyzed, and 67 were selected, considered the most relevant, for use in this review. The results of preliminary study conducted by the authors of this article were also incorporated. Article selection included keywords such as "feline soft tissue sarcomas," "feline sarcoma," "vaccination-associated feline sarcoma," and "feline oncology," among others. Articles written in English and Spanish and published within the last 10 years were prioritized; however, 28 articles older than 10 years, considered foundational and essential to understanding the topic, were also selected. Exclusion criteria included publications that were not peer-reviewed or whose content was irrelevant to the objectives of this review.

MORPHOLOGICAL ASPECTS

Macroscopically, ISS can be found as well-defined white and firm masses, usually centrally cavitated and containing liquid, which may be watery or mucinous (Hendrick *et al.*, 1992; Figure 1). Microscopically, their appearance varies depending on the degree of anaplasia and the type of sarcoma (Hendrick *et al.*, 1992). Regardless of the latter aspect, ISS are characterized by a perivascular lymphocytic infiltrate at the tumor's periphery (Figure 2), the presence of giant cells, and a prominent myofibroblastic component (Madewell *et al.*, 2001).

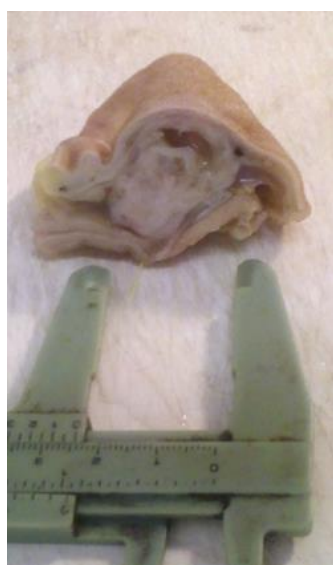

Figure 1. Macroscopic view of ISS sampled from a cat. Source: Santelices *et al.* (2014).

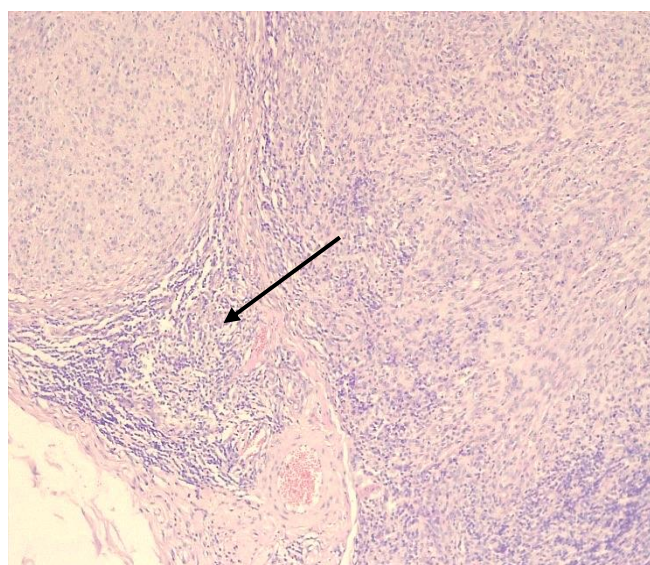


Figure 2. Microscopic view of ISS showing abundant peritumoral lymphocytic infiltrate (arrow). Hematoxylin and Eosin.

Sarcomas associated with inoculation sites present an increased presence of peripheral inflammatory cell infiltrate, composed primarily of lymphocytes and macrophages. This infiltration is present in 59% to 100% of ISSs, in contrast to 0% to 33% in NISSs. Furthermore, multinucleated giant cells are present in 30% to 50% of ISSs, while these cells were only found in 0% to 13% of NISSs (Zajc et al., 2022). Moreover, ISS exhibits more remarkable pleomorphism (60-64% compared to 17-36% in NISS), a higher degree of tumor necrosis, and an elevated mitotic index (Zajc et al., 2022). Particularly, ISSs share several characteristics with intraocular sarcomas that develop following chronic inflammation or intraocular trauma, including their aggressiveness and high rates of recurrence and metastasis (Perlmann et al., 2011; Bastos et al., 2020). Intraocular sarcomas have primarily myofibroblast origin (McPherson et al., 2009).

BIOLOGICAL AND CLINICAL BEHAVIOR

Soft tissue sarcomas, in general, show a growth pattern that varies between expansive and infiltrative (Dobromylyskij et al., 2021), and have recurrence rates that can range from low to high following surgical excision (Mauldin, 1997; Carneiro et al., 2019; Zajc et al., 2022). These tumors can manifest as either superficial, mobile masses or as infiltrative tumors that invade deeper tissues. Initially, they may remain stable for weeks or months before entering a phase of rapid growth (Dobromylyskij et al., 2021). Particularly, the anatomical location ISS in cats is commonly found in areas frequently used for vaccine or other inoculations, such as the interscapular region, lateral thoracic wall, lumbar region, and the hind limbs (Zajc et al., 2022; Hartmann et al., 2023).

On the other hand, NISS is considered less aggressive than ISS (Zajc et al., 2022). The annual prevalence of NISS in cats is estimated to be around 17/35 per 100.000 (Mauldin, 1997; Dernell, 1998). For ISS, the prevalence is estimated to be between 1:1.000 and 1:10.000 in vaccinated cats (Wilcock et al., 2012; Wei and Ramsey et al., 2019). However, the estimated prevalence is based only on cases referred for histopathological diagnosis, so it could be higher (Wilcock et al., 2012; Cecco et al., 2019). The true prevalence could be 1:10,000 to 13:10,000 cats vaccinated against rabies (Banerji et al., 2007). Furthermore, ISS is a highly invasive tumor with a high risk of recurrence (Hendrick et al., 1994).

Cats with ISS after multiple surgeries, with or without adjuvant therapy, are generally euthanized because the longer the animal's survival, the higher the frequency of metastases (Wilcock et al., 2012). Metastases can occur in different anatomical sites such as regional lymph nodes, mediastinum, lungs, among others (Hendrick et al., 1994; Rudmann et al., 1996; Briscoe et al., 1998). The percentage of metastases in ISS in cats varies between 10% and 28%. In contrast, NISS rarely develops metastases (Hartmann et al., 2023).

DIAGNOSIS

The preferred method for diagnosing soft tissue sarcomas is excisional biopsy. However, this diagnosis is difficult due to the inflammation and fibroplasia associated with these tumors (Wilcock et al., 2012). Considering that ISS and NISS exhibit similar histological features, which makes their differentiation difficult, key differentiating factors include the anatomical location of the tumor and the presence of peritumoral inflammation (Wilcock et al., 2012).

The diagnosis of ISS relies on the identification of histological characteristics that are most frequently associated with these sarcomas, such as the presence of the characteristic inflammatory infiltrate, as well as on the tumor's anatomical location in areas traditionally used for vaccine and other inocula administration. It is important to note that the histological diagnosis is not specific for ISS, a fact that complicates the ability to differentiate them with certainty from NISS (Wilcock et al., 2012). Immunohistochemical techniques can be useful in differentiating between different subtypes of sarcomas (Dobromylyskij, 2022). However, there are currently no specific markers that can differentiate between ISS and NISS.

PATHOGENESIS

Persistent inflammatory responses at inoculation sites in cats promote tissue repair, which, in certain cases, may lead to the development of neoplasia (Hendrick et al., 1992; Santelices, 2019). It has been proposed that these tumors arise from the malignant transformation of reactive fibroblasts located at the periphery of post-vaccination responses. Malignant transformation of fibroblasts thought to be influenced by the genetic predisposition of the animal (Wilcock et al., 2012; Hartmann et al., 2023). In ISS, alterations in p53 (Banerji, 2007) were found. Some authors suggest that not only vaccines contribute to the development of these tumors (MacEwen et al., 2001; Martano et al., 2011; Zabielska-Koczywas et al., 2017), but that any stimulus capable of generating a persistent local inflammatory response may be sufficient to induce sarcoma formation in susceptible cats. However, vaccines are considered the inoculations most frequently associated with their development (MacEwen et al., 2001). Given that ocular sarcomas in cats share histological characteristics with ISS and occur in cats with a history of previous or persistent trauma (Hendrick et al., 1994), it could be hypothesized that certain cats have a genetic predisposition to develop neoplasms following inflammatory or reparative processes (Perlmann et al., 2011). It is possible that genetic factors, in conjunction with the

inflammatory process, may help to promote the development of these sarcomas (Banerji *et al.*, 2007). In contrast, the etiopathogenesis of NISS remains unknown (Withrow, 1998; Dillon, 2005).

Malignant transformation of fibroblasts can occur through the activation of certain oncogenes, the inactivation of tumor suppressor genes, and the action of growth factors that not only promote fibroblast proliferation but also induce malignant transformation and regulate angiogenesis. Overexpression of these factors has been found in various human neoplasias and has been linked to carcinogenesis (O'Byrne and Dalgleish, 2001; Hartmann *et al.*, 2023).

The enzyme cyclooxygenase 2 (COX-2) is involved in the production of prostaglandins (PGs) and thromboxanes (TXs). Overexpression of COX-2 promotes the production of cytokines and PGs, creating an inflammatory environment that promotes cellular malignancy. Among PGs, PG E2 plays an important role in the pathogenesis of cancerous processes (Santelices Iglesias, 2019; Hartmann *et al.*, 2023). Furthermore, chronic inflammatory responses can lead to the generation of free radicals and certain metabolites that induce DNA mutations, thus acting as carcinogens (O'Byrne and Dalgleish, 2001; Nieto *et al.*, 2003). Recently, a positive correlation has been shown between COX-2 expression and tumor cell proliferation (Santelices Iglesias, 2019; Santelices Iglesias *et al.*, 2023). Santelices Iglesias (2019) demonstrated that COX-2 expression is directly proportional to the level of inflammation present in feline ISS. The most undifferentiated ISS present lower levels of COX-2 expression (Santelices Iglesias, 2019). Furthermore, COX-2 expression shows a positive correlation with cell proliferation in these feline sarcomas and is associated with increased vascularization. Interestingly, ISS diagnosed in younger animals tends to express higher levels of COX-2.

Malignant tumor cells secrete a variety of growth factors in large quantities, such as fibroblast growth factor (FGF) and platelet-derived growth factor (PDGF), which are involved in cell proliferation, migration, and differentiation. Another factor secreted by malignant tumor cells is vascular endothelial growth factor (VEGF), which promotes angiogenesis and, consequently, tumor progression. VEGF is also essential for the development of metastasis, as it provides a route of entry into the bloodstream (Martínez-Ezquerro and Herrera, 2006). Furthermore, the inflammatory cells that infiltrate these neoplasms secrete different cytokines and proteases, such as metalloproteinases, which also participate in both invasiveness and angiogenesis and, therefore, in tumor growth and the development of metastasis in humans (Cao *et al.*, 2008).

Fibroblast growth factors type 1 and type 2 (FGF-1 and FGF-2) promote the expression of oncogenes and subsequent tumor development (Santelices *et al.*, 2023). Fibroblast growth factor type 2 is closely related to inflammation, angiogenesis, and the origin of mesenchymal tumors, and its presence has been demonstrated in soft tissue of ISS using immunohistochemical techniques. Cytokines and prostaglandins induce the release of FGF-2 by tumor cells, which enhances cell growth and survival, suppresses cell-mediated immune responses, and promotes angiogenesis (Nieto *et al.*, 2003; Santelices Iglesias *et al.*, 2023). Expression of FGF-2 has also been found in NISS (Santelices Iglesias, 2019; Santelices Iglesias *et al.*, 2023).

Autocrine stimulation of certain growth factor receptors, such as the platelet-derived growth factor receptor (PDGFR), may be involved in the pathogenesis of these neoplasms. Expression of both platelet growth factor (PDGF) and its receptor (PDGFR) has been confirmed in ISS and NISS (Santelices Iglesias, 2019). Platelet growth factor was also found in the lymphocytes found in ISSs, but not in those of NISSs or the lymphocytes of normal lymph nodes. Therefore, PDGF synthesis by lymphocytes stimulated by the inflammatory reaction in ISSs could play a significant role in the behavioral differences found between ISSs and NISSs (MacEwen *et al.*, 2001). Furthermore, the expression of PDGFR α and FGFR-2 has been shown to be directly proportional to cell proliferation in the ISS. In other words, higher PDGFR α expression means greater proliferation of neoplastic cells in the ISS; the same is true for FGFR-2; increasing its expression increases the proliferation of neoplastic cells in the ISS. In the case of FGFR-2, a positive correlation was demonstrated with the degree of anaplasia; therefore, this receptor is expressed to a lesser extent in ISS with a lower degree of anaplasia (Santelices Iglesias, 2019).

Angiogenesis is the formation of new blood vessels from pre-existing ones. Angiogenesis defines the tumor microenvironment and is a prerequisite for tumor growth (Hendrick *et al.*, 1992; Martínez-Ezquerro and Herrera, 2006). It is regulated by several factors, among which vascular endothelial growth factor A (VEGF-A) is considered the most important (Ghalehbandi *et al.*, 2023). VEGF exerts its effects through two receptors: vascular endothelial growth factor receptor 1 (FLT-1) or VEGFR-1 and kinase domain receptor (KDR) or VEGFR-2. Binding to KDR is responsible for the primary effects of VEGF, whereas binding to FLT-1 modulates VEGF signaling by sequestering the ligand (Chung and Ferrara, 2011). The study on angiogenesis in invasive neoplasms, such as fibrosarcomas, has demonstrated that significant increases in microvascular density and endothelial area are linked to enhanced angiogenesis, which correlates with greater malignancy (Patrino *et al.*, 2020). Expression of VEGF and its receptor VEGFR-2 was found in blood vessels and neoplastic cells in ISS and NISS in cats, suggesting that angiogenesis is stimulated by VEGF synthesized by tumor cells of both types of sarcomas. The expression of VEGFR-2 in neoplastic cells may suggest an autocrine or

paracrine mechanism of VEGF-A in these cells (Wright et al., 2024). To date, no previous reports have documented the expression of these molecules in feline sarcomas.

Sarcomas associated with inoculation sites express COX-2 is part of the inflammatory microenvironment, and the expression of this enzyme could also be associated with the synthesis and activation of metalloproteinases that promote invasion and angiogenesis (O'Byrne and Dalgleish, 2001; Martano et al., 2011). Preliminary studies found the expression of COX-2 in the NISS (Santelices Iglesias, 2019; Wojtkowska et al., 2024). Santelices Iglesias (2019) found the expression of COX-2 in 50% of the NISS studied, while Wojtkowska et al (2024) found the expression of COX-2 in 37.5% of the NISS.

Matrix metalloproteinases (MMPs) are a family of structurally and functionally related zinc- and calcium-dependent endopeptidases. They play a key role in the degradation of the extracellular matrix (ECM) and many other biological processes (Diessler et al., 2017; Frolova et al., 2020). MMPs degrade various protein components of the ECM, such as collagen, proteoglycans, and fibronectin. Their ability to degrade these protein components makes them essential for connective tissue remodeling in different developmental processes, including pregnancy, growth, and wound healing (Bode and Maskos, 2003; Pisamai et al., 2017; Gualdoni et al., 2021). Under normal conditions, their proteolytic activity is regulated by endogenous protein inhibitors known as tissue inhibitors of metalloproteinases (TIMPs). When the balance with its inhibitors is altered, changes in pathophysiological processes occur, resulting in various diseases, such as arthritis, cardiovascular disease, and emphysema. Furthermore, this imbalance promotes the invasiveness of certain neoplasms and metastasis (Jankowski et al., 2002; Bode and Maskos, 2003). Given the role that MMPs play in tumor invasiveness mechanisms, they are considered an important area of study in both human and veterinary medicine. This is due to their potential prognostic value and their possible application as therapeutic targets in various types of neoplasms, including sarcomas (Porcellato et al., 2017). Among the MMPs, the MMP-2 and MMP-9 are associated with tumor cell invasion and migration, and their proteolytic activity can be inhibited by TIMP-2 (Porcellato et al., 2017).

In domestic animals, the expression of metalloproteinases and their tissue inhibitors has been shown to contribute to invasion and metastasis in mammary tumors. Elevated levels of MMP-2 and MMP-9 have been recorded in mammary tumors, while TIMP-2 expression has yielded inconsistent results. MMP-2 expression in these neoplasms has been linked to tumor progression, thus acting as an indicator of tumor cell growth and invasion (Pisamai et al., 2017).

Sorensen et al. (2004) and their research group evaluated the expression of metalloproteinases using reverse transcriptase polymerase chain reaction (RT-PCR) on fresh biopsy samples from ISS, NISS, and carcinomas in cats. Their findings were inconclusive due to several factors, including the small and heterogeneous sample size, as well as technical limitations, such as the inability to clone MMP-9 using RT-PCR. However, Sorensen et al. (2004) did not find significant differences in the expression of MMPs and TIMPs—specifically MMP-1, MMP-2, MMP-3, MMP-10, MMP-13, MMP-16, TIMP-1, TIMP-2, and TIMP-3—between ISS and NISS. As a result, Sorensen et al (2004) emphasizes the importance of further studies on the expression of metalloproteinases in neoplasms of domestic cats.

Wojtkowska et al. (2024) evaluated the immunohistochemical expression of MMP-2 and MMP-9 in both ISS and NISS cats, without finding significant differences between the two groups for the expression of MMP-2. The evaluation of the immunohistochemical expression of MMP-9 was higher in ISS than in NISS. On the other hand, Wright et al. (2023) evaluated the immunohistochemical expression of MMP-2, MMP-9, and their inhibitors, TIMP-1 and TIMP-2, in ISS as in NISS. Despite being preliminary results, the data showed significant differences between both groups of sarcomas in the expression of MMP-9, which was higher in NISS. Furthermore, in both ISS and NISS, the expression of MMP-9 and TIMP-1 was higher than that of MMP-2 and TIMP-2. Additional studies with larger sample sizes are needed to confirm these findings. Furthermore, it is important to further study the association between the expression of MMPs and their TIMPs with the invasiveness and progression of ISS and NISS in cats. This would improve the understanding of the role that these molecules play in the biological behavior of these tumors (Wright et al., 2023).

TREATMENT

The treatment of soft tissue ISS in cats typically involves aggressive surgery with wide margins, often accompanied by adjunct therapies such as radiotherapy, chemotherapy, or immunotherapy, depending on the patient's clinical status. Radical surgery, with wide margins, can improve both the tumor-free interval and the patient's survival. For aggressive radical surgery, it is recommended to include peripheral margins of 3 to 5 cm around the tumor, along with two deep fascial planes, which increases the likelihood of complete tumor removal and reduces the risk of recurrence (Zabielska-Koczywaś et al., 2017; Hsueh et al., 2019). In addition, some preliminary studies suggest that combining immunostimulants with radiotherapy may help extend the tumor-free interval, thus improving the long-term prognosis of cats affected by these tumors; however, radiotherapy has certain undesirable effects, such as bone necrosis and radiation-induced tumors (Rossi et al., 2019). The recurrence rate after surgery without adjuvant therapies is around 62% (Hendrick, 1999).

Management guidelines and treatment recommendations for soft tissue ISS are well established in cats (Zajc *et al.*, 2022). However, for NISS in cats, there is currently no standardized therapeutic protocol. For this reason, those used in dogs are adopted as a model. In dogs, treatment depends on the animal's condition, as well as the size and location of the tumor, histological characteristics, histological grade, and the condition of the surgical margins. The treatment of choice is wide surgical resection combined with radiotherapy, especially when complete tumor resection is not possible (Zajc *et al.*, 2022).

The authors' results of this study suggest that the degree of inflammation present in the ISS would predict COX-2 expression. The higher the degree of inflammation, the higher the COX-2 expression and, therefore, the greater the susceptibility to COX-2 inhibitor therapies. This characteristic of the ISS would provide veterinary oncologists with a simple and inexpensive tool to estimate susceptibility to COX-2 inhibitor treatments in each particular case, since the degree of inflammation is established by routine processing of biopsies sent for diagnosis. On the other hand, highly undifferentiated tumors show reduced expression of the enzyme, which could make them less susceptible to COX-2 inhibitor therapies. These findings could be valuable for the design of treatment protocols that incorporate COX-2 inhibitors for ISS (Santelices *et al.*, 2018). Therapies that use these inhibitors yielded favorable results in human and veterinary oncology (Wen *et al.*, 2020; Wang *et al.*, 2021; Kolawole and Kashfi, 2022; Maekawa *et al.*, 2022; Musa *et al.*, 2022). In various canine tumors, such as inflammatory mammary carcinomas and nasal carcinomas, treatment with COX-2 inhibitors has been beneficial (Alonso-Miguel *et al.*, 2021; Pauly *et al.*, 2024). The effectiveness of robenacoxib, a highly selective COX-2 inhibitor, was evaluated *in vitro* using cell lines derived from ISS, and it successfully reduced cell viability in these lines. Although susceptibility to this drug varied among different cell lines, the results indicate that COX-2 inhibitors could serve as a valuable adjuvant therapy against ISS (Lu *et al.*, 2023).

Given the association between COX-2 expression, vascularization, and cellular proliferation in ISS, therapies with their inhibitors could provide antiangiogenic and antiproliferative effects when used with low toxicity drugs, such as robenacoxib, which has been tested *in vitro*. Robenacoxib has been shown to inhibit viability, migration, and colony formation in ISS-derived cell cultures (Lu *et al.*, 2023). Furthermore, the expression of PDGF and FGF receptors, both in ISS and NISS, makes them an interesting therapeutic target. The use of tyrosine kinase inhibitors could inhibit the proliferative capacity of these neoplasms (Santelices, 2019). In this sense, tyrosine kinase inhibitors play a fundamental role in the treatment of human and canine neoplasms. However, its role in feline oncology is still under discussion. In cats, the most effective tyrosine kinase inhibitor as an antineoplastic agent appears to be toceranib phosphate (Žagar and Schmidt, 2023).

As a future perspective, it is essential to evaluate the therapeutic value of protocols that include COX-2, PDGFR α , and FGFR-2 inhibitors for both ISS and NISS. The degree of anaplasia and inflammation could be useful as indicators of the susceptibility of ISS to treatment with COX-2 inhibitors. The degree of anaplasia could also predict susceptibility to treatment with PDGFR α and FGFR-2 inhibitors. Currently, there are no studies that have evaluated the existence of a statistical association between the degree of anaplasia and inflammation and the expression of COX-2, PDGFR α , and FGFR-2 in NISS (Santelices *et al.*, 2018; 2023).

Although the treatment choice in these cases, as previously mentioned, is surgery with wide margins, protocols that incorporate COX-2 inhibitors and tyrosine kinase inhibitors may help to reduce tumor size before surgery, extend survival in unresectable tumors, and prolong the interval between recurrences when radical surgery is not feasible (Santelices Iglesias, 2019).

CONCLUSION

Improving the understanding of ISS and NISS, particularly their differences, is critical to better understanding their genesis and progression. This would increase the potential for new interventions that improve the quality of life and survival of animal patients suffering from these conditions. However, an analysis of the existing references on the SSI shows that there are still major gaps in knowledge about the genetic and epigenetic bases that determine why this neoplasia develops in cats and not in other species. Further studies are needed to gain a deeper understanding of the molecular basis of SSI pathogenesis.

DECLARATIONS

Authors' contributions

Carolina Wright, Olga Andrea Santelices Iglesias, Francisco Acuña, and Claudio Gustavo Barbeito were responsible for conceptualizing the article. Carolina Wright collected the data and provided the original draft of the manuscript, while Olga Andrea Santelices Iglesias, Francisco Acuña, Claudio Gustavo Barbeito, Natalia Zannuzzi Carolina, and

Adriana Graciela Duchene reviewed it. All authors considered and agreed on the final version of the manuscript for publication in the present journal

Funding

This study was supported by the following projects evaluated and accredited by the Secretariat of Science and Technology of the School of Veterinary Sciences UNLP: Morphology applied to the study of animal pathology and diversity. Code: V273 Director: Barbeito Claudio Gustavo. Year 2019-2023 (ended in December 2023) and Macro and microscopic morphometry in animals. Code: V309 Director: Portiansky Enrique Leo Start: from 01/01/2024.

Availability of data and materials

The information used and analyzed in this review comes from different publicly available articles that have been cited in this manuscript.

Competing interests

The authors did not indicate any conflicts of interest.

Ethical considerations

Ethical issues, including plagiarism, consent to publish, misconduct, data fabrication and/or falsification, double publication and/or submission, and redundancy have been checked by all the authors.

REFERENCES

- Avallone G, Rasotto R, Chambers JK, Miller AD, Behling-Kelly E, Monti P, Berlato D, Valenti P, and Roccabianca P (2021). Review of histological grading systems in veterinary medicine. *Veterinary Pathology*, 58(5): 809-828. DOI: <https://www.doi.org/10.1177/0300985821999831>
- Alonso-Miguel D, Valdivia G, Garcia-San José P, Alonso-Diez A, Clares I, Portero M, Peña L, and Pérez-Alenza MD (2022). Clinical outcome of dogs diagnosed with canine inflammatory mammary cancer treated with metronomic cyclophosphamide, a cyclooxygenase-2 inhibitor and toceranib phosphate. *Veterinary and Comparative Oncology*, 20(1): 179-188. DOI: <https://www.doi.org/10.1111/vco.12760>
- Banerji N, Kapur V, and Kanjilal S (2007). Association of germ-line polymorphisms in the feline p53 gene with genetic predisposition to vaccine-associated feline sarcoma. *Journal of Heredity*, 98(5): 421-427. DOI: <https://www.doi.org/10.1093/jhered/esm057>
- Bastos IPB, Baruel CV, Braga TF, Faleiro RD, Medeiros RS, and de Lima LR (2020). Feline intraocular sarcoma: Case report. *BMC Veterinary Research*, 42(1): e106920. DOI: <https://www.doi.org/10.29374/2527-2179.bjvm106920>
- Briscoe CM, Lipscomb TP, and McKinney L (1998). Pulmonary metastasis of a feline vaccination-site fibrosarcoma. *Journal of Veterinary Diagnostic Investigation*, 10(1): 79-82. DOI: <https://www.doi.org/10.1177/104063879801000114>
- Bode W and Maskos K (2003). Structural basis of the matrix metalloproteinases and their physiological inhibitors, the tissue inhibitors of metalloproteinases. *Biological Chemistry*, 384(6): 863-872. DOI: <https://www.doi.org/10.1515/BC.2003.097>
- Cao Y, Cao R, and Hedlund EM (2008). Regulation of tumor angiogenesis and metastasis by FGF and PDGF signaling pathways. *Journal of molecular medicine*, 86: 785-789. DOI: <https://www.doi.org/10.1007/s00109-008-0337-z>
- Carminato A, Vascellari M, Marchioro W, Melchioti E, and Mutinelli F (2011). Microchip-associated fibrosarcoma in a cat. *Veterinary Dermatology*, 22(6): 565-569. DOI: <https://www.doi.org/10.1111/j.1365-3164.2011.00975.x>
- Carneiro CS, de Queiroz GF, Pinto AC, Dagli ML, and Matera JM (2019). Feline injection site sarcoma: immunohistochemical characteristics. *Journal of Feline Medicine and Surgery*, 21(4): 314-321. DOI: <https://www.doi.org/10.1177/1098612X18774709>
- Cecco BS, Henker LC, De Lorenzo C, Schwertz CI, Bianchi RM, da Costa FVA, Driemeier D, Pavarini SP, and Sonne L (2019). Epidemiological and pathological characterization of feline injection site sarcomas in southern Brazil. *Journal of Comparative Pathology*, 172: 31-36. DOI: <https://www.doi.org/10.1016/j.jcpa.2019.08.009>
- Chung AS and Ferrara N (2011). Developmental and pathological angiogenesis. *Annual Review of Cell and Developmental Biology*, 27(1): 563-584. DOI: <https://www.doi.org/10.1146/annurev-cellbio-092910-154002>
- De Nardi AB, Raposo TMM, Huppés RR, Daleck CR, and Amorim RL (2011). COX-2 inhibitors for cancer treatment in dogs. *Pakistan Veterinary Journal*, 31(4): 275-279. Available at: http://www.pvj.com.pk/pdf-files/31_4/275-279.pdf
- Dean RS, Pfeiffer DU, and Adams V J (2012). Feline vaccination practices and protocols used by veterinarians in the United Kingdom. *The Veterinary Journal*, 194(1): 113-117. DOI: <https://www.doi.org/10.1016/j.tvjl.2012.02.024>
- Deim Z, Pálmai N, and Cserni G (2008). Feline vaccine-associated fibrosarcoma induced by aluminium compound in two cats: Short communication. *Acta Veterinaria Hungarica*, 56(1): 111-116. DOI: <https://www.doi.org/10.1556/avet.56.2008.1.11>
- Dernell WS, Withrow SJ, Kuntz CA, and Powers BE (1998). Principles of treatment for soft tissue sarcoma. *Clinical Techniques in Small Animal Practice*, 13(1): 59-64. DOI: [https://www.doi.org/10.1016/S1096-2867\(98\)80029-7](https://www.doi.org/10.1016/S1096-2867(98)80029-7)
- Diessler M, Ventureira M, Hernandez R, Sobarzo C, Casas L, Barbeito C, and Cebral E (2017). Differential expression and activity of matrix metalloproteinases 2 and 9 in canine early placenta. *Reproduction in Domestic Animals*, 52(1): 35-43. DOI: <https://www.doi.org/10.1111/rda.12791>
- Dillon CJ, Mauldin GN, and Baer KE (2005). Outcome following surgical removal of nonvisceral soft tissue sarcomas in cats: 42 cases (1992-2000). *Journal of the American Veterinary Medical Association*, 227(12): 1955-1957. DOI: <https://www.doi.org/10.2460/javma.2005.227.1955>
- Dobromylskyj MJ, Richards V, and Smith KC (2021). Prognostic factors and proposed grading system for cutaneous and subcutaneous soft tissue sarcomas in cats, based on a retrospective study. *Journal of Feline Medicine and Surgery*, 23(2): 168-174. DOI: <https://www.doi.org/10.1177/1098612X20942393>
- Dobromylskyj M (2022). Feline soft tissue sarcomas: A review of the classification and histological grading, with comparison to human and canine. *Animals*, 12(20): 2736. DOI: <https://www.doi.org/10.3390/ani12202736>
- Frolova AS, Petushkova AI, Makarov VA, Soond SM, and Zamyatin Jr AA (2020). Unravelling the network of nuclear matrix metalloproteinases for targeted drug design. *Biology*, 9(12): 480. DOI: <https://www.doi.org/10.3390/biology9120480>
- Ghalehbandi S, Yuzugulen J, Pranjol MZI, and Pourgholami MH (2023). The role of VEGF in cancer-induced angiogenesis and research progress of drugs targeting VEGF. *European Journal of Pharmacology*, 949: 175586 DOI: <https://www.doi.org/10.1016/j.ejphar.2023.175586>

- Gualdoni G, Gomez Castro G, Hernández R, Barbeito C, and Cebra E (2022). Comparative matrix metalloproteinase-2 and -9 expression and activity during endotheliochorial and hemochorial trophoblastic invasiveness. *Tissue Cell*, 74: 101698. DOI: <https://www.doi.org/10.1016/j.tice.2021.101698>
- Hartmann K, Egberink H, Möstl K, Addie DD, Belák S, Boucraut-Baralon C, Frymus T, Lloret A, Hofmann-Lehmann R, Marsilio F *et al.* (2023). Feline injection-site sarcoma and other adverse reactions to vaccination in cats. *Viruses*, 15(8): 1708. DOI: <https://www.doi.org/10.3390/v15081708>
- Hendrick MJ, Goldschmidt MH, Shofer FS, Wang YY, and Somlyo AP (1992). Postvaccinal sarcomas in the cat: Epidemiology and electron probe microanalytical identification of aluminum. *Cancer Research*, 52(19): 5391-5394. Available at: <https://aacrjournals.org/cancerres/article/52/19/5391/498023/Postvaccinal-Sarcomas-in-the-Cat-Epidemiology-and>
- Hendrick MJ, Shofer FS, Goldschmidt MH, Haviland JC, Schelling SH, Engler SJ, and Gliatto JM (1994). Comparison of fibrosarcomas that developed at vaccination sites and at nonvaccination sites in cats: 239 cases (1991-1992). *Journal of the American Veterinary Medical Association*, 205(10): 1425-1429. DOI: <https://www.doi.org/10.2460/javma.1994.205.10.1425>
- Hendrick MJ (1999). Feline vaccine-associated sarcomas. *Cancer Investigation*, 17(4): 273-277. DOI: <https://www.doi.org/10.3109/07357909909040597>
- Hsueh CS, Wu CH, Shih CH, Yeh JL, Jeng CR, Pang VF, Chiou HY, and Chang HW (2019). Role of nuclear factor-kappa B in feline injection site sarcoma. *BMC Veterinary Research*, 15(1): 365. DOI: <https://www.doi.org/10.1186/s12917-019-2100-9>
- Jankowski MK, Ogilvie GK, Lana SE, Fettman MJ, Hansen RA, Powers BE, Mitchener KM, Lovett SD, Richardson KL, Parsley L *et al.* (2002). Matrix metalloproteinase activity in tumor, stromal tissue, and serum from cats with malignancies. *Journal of Veterinary Internal Medicine*, 16(1): 105-108. DOI: <https://www.doi.org/10.1111/j.1939-1676.2002.tb01614.x>
- Kliczkowska K, Jankowska U, Jagielski D, Czapowicz M, and Sapierzynski R (2015). Epidemiological and morphological analysis of feline injection site sarcomas. *Polish Journal of Veterinary Sciences*, 18(2): 313-322. DOI: <https://www.doi.org/10.1515/pjvs-2015-0041>
- Kolawole OR and Kashfi K (2022). NSAIDs and cancer resolution: New paradigms beyond cyclooxygenase. *International Journal of Molecular Sciences*, 23(3): 1432. DOI: <https://www.doi.org/10.3390/ijms23031432>
- Löhr CV, Stieger-Vanegas SM, Terry JL, Milovancev M, and Medlock J (2021). Targeting peritumoral lesions identified by computed tomography and magnetic resonance imaging in feline injection-site sarcomas for microscopic examination. *Veterinary Pathology*, 58(5): 923-934. DOI: <https://www.doi.org/10.1177/03009858211012949>
- Lu CH, Yu SH, Wu CH, Yeh JLS, Chang HW, Jeng CR, and Chang YC (2023). Effects of selective cyclooxygenase-2 inhibitor robenacoxib on primary cells derived from feline injection-site sarcoma. *Journal of Cellular and Molecular Medicine*, 27(15): 2183-2193. DOI: <https://www.doi.org/10.1111/jcmm.17717>
- Ludwig L, Dobromylskij M, Wood GA, and van der Weyden L (2022). Feline oncogenomics: What do we know about the genetics of cancer in domestic cats?. *Veterinary Sciences*, 9(10): 547. DOI: <https://www.doi.org/10.3390/vetsci9100547>
- MacEwen EG, Powers BE, Macy D, and Withrow SJ (2001). Soft Tissue sarcomas. In: S. J. Withrow and E. G. MacEwen (Editors). *Small animal clinical oncology*, 3rd Edition. W. B. Saunders Company, Philadelphia., pp. 283-304. Available at: https://archive.org/details/smallanimalclini0000unse_e5a4
- Madewell BR, Griffey SM, McEntee MC, Leppert VJ, and Munn RJ (2001). Feline vaccine-associated fibrosarcoma: An ultrastructural study of 20 tumors (1996-1999). *Veterinary Pathology*, 38(2): 196-202. DOI: <https://www.doi.org/10.1354/vp.38-2-196>
- Maekawa N, Konnai S, Asano Y, Sajiki Y, Deguchi T, Okagawa T, Watari K, Takeuchi H, Takagi S, Hosoya K *et al.* (2022). Exploration of serum biomarkers in dogs with malignant melanoma receiving anti-PD-L1 therapy and potential of COX-2 inhibition for combination therapy. *Scientific Reports*, 12(1): 9265. DOI: <https://www.doi.org/10.1038/s41598-022-13484-8>
- Martínez-Ezquerro JD and Herrera LA (2006). Angiogenesis: VEGF/VEGFRs como blancos terapéuticos en el tratamiento contra el cáncer [Angiogenesis: VEGF/VEGFRs as therapeutic targets in cancer treatment]. *Cancerología*, 1(1): 83-96. Available at:
- Martano M, Morello E, and Buracco P (2011). Feline injection-site sarcoma: Past, present, and future perspectives. *The Veterinary Journal*, 188(2): 136-141. DOI: <https://www.doi.org/10.1016/j.tvjl.2010.04.025>
- Mauldin GN (1997). Soft tissue sarcomas. The veterinary clinics of North America. *Small Animal Practice*, 27(1): 139-148. DOI: [https://www.doi.org/10.1016/s0195-5616\(97\)50012x](https://www.doi.org/10.1016/s0195-5616(97)50012x)
- McPherson L, Newman SJ, McLean N, McCain S, Vemulapalli R, Kania S, and Dubielzig RR (2009). Intraocular sarcomas in two rabbits. *Journal of Veterinary Diagnostic Investigation*, 21(4): 547-551. DOI: <https://www.doi.org/10.1177/104063870902100422>
- Musa A, Mostafa EM, Bukhari SNA, Alotaibi NH, El-Ghorab AH, Farouk A, Nayl AA, Ghoneim MM, and Abdelgawad MA (2022). EGFR and COX-2 Dual Inhibitor: The design, synthesis, and biological evaluation of novel chalcones. *Molecules*, 27(4): 1158. DOI: <https://www.doi.org/10.3390/molecules27041158>
- Nieto A, Sanchez MA, Martínez E, and Rollan E (2003). Immunohistochemical expression of p53, fibroblast growth factor-b, and transforming growth factor- α in feline vaccine-associated sarcomas. *Veterinary Pathology*, 40(6): 651-658. DOI: <https://www.doi.org/10.1354/vp.40-6-651>
- O'Byrne KJ and Dagleish AG (2001). Chronic immune activation and inflammation as the cause of malignancy. *British Journal of Cancer*, 85(4): 473-483. DOI: <https://www.doi.org/10.1054/bjoc.2001.1943>
- Patruño R, Passantino G, Laface C, Tinelli A, Zito A, Ruggieri R, Luposella F, Gadaleta P, Laforgia M, Lacitignola L *et al.* (2020). Microvascular density, Endothelial area, and Ki-67 proliferative index correlate each other in cat post-injection fibrosarcoma. *Cells*, 10(1): 31. DOI: <https://www.doi.org/10.3390/cells10010031>
- Pauly LA, M, Junginger J, Oechtering GU, Hewicker-Trautwein M, and Rösch S (2024). Expression of vascular endothelial growth factor receptor-2, epidermal growth factor receptor, cyclooxygenase-2, survivin, E-cadherin and Ki-67 in canine nasal carcinomas and sarcomas—A pilot study. *Frontiers in Veterinary Science*, 11: 1388493. DOI: <https://www.doi.org/10.3389/fvets.2024.1388493>
- Perlmann E, Rodarte-Almeida ACV, Albuquerque L, Safatle ADMV, Pigatto, JAT, and Barros PSDM (2011). Feline intraocular sarcoma associated with phthisis bulbi. *Arquivo Brasileiro de Medicina Veterinária e Zootecnia*, 63: 591-594. DOI: <https://www.doi.org/10.1590/S0102-09352011000300009>
- Pisamai S, Rungsipipat A, Kunasut N, and Suriyaphol G (2017). Immunohistochemical expression profiles of cell adhesion molecules, matrix metalloproteinases and their tissue inhibitors in central and peripheral neoplastic foci of feline mammary carcinoma. *Journal of Comparative Pathology*, 157(2-3): 150-162. DOI: <https://www.doi.org/10.1016/j.jcpa.2017.07.004>
- Porcellato I, Menchetti L, Brachelente C, Sforna M, Reginato A, Lepri E, and Mechelli L (2017). Feline injection-site sarcoma: Matrix remodeling and prognosis. *Veterinary Pathology*, 54(2): 204-211. DOI: <https://www.doi.org/10.1177/0300985816677148>
- Rossi F, Marconato L, Sabatini S, Cancedda S, Laganga P, Leone VF, and Rohrer Bley C (2019). Comparison of definitive-intent finely fractionated and palliative-intent coarsely fractionated radiotherapy as adjuvant treatment of feline microscopic injection-site sarcoma. *Journal of Feline Medicine and Surgery*, 21(2): 65-72 DOI: <https://www.doi.org/10.1177/1098612X18758883>
- Rudmann DG, Alstine WV, Doddy F, Sandusky GE, Barkdull T, and Janovitz EB (1996). Pulmonary and mediastinal metastases of a vaccination-site sarcoma in a cat. *Veterinary Pathology*, 33(4): 466-469. DOI: <https://www.doi.org/10.1177/030098589603300422>
- Saba CF (2017). Vaccine-associated feline sarcoma: Current perspectives. *Veterinary Medicine: Research and Reports*, 8: 13-20. DOI: <https://www.doi.org/10.2147/VMRR.S116556>
- Santelices Iglesias OA, Lavid A, Santana C, Díaz M, Confente F, Duchene AG, Gimeno EJ, and Barbeito CG (2014). Sarcomas felinos en sitios de inoculación [Feline sarcomas at inoculation sites]. *Veterinary Selections*, 2: 60-73. Available at: <https://www.seleccionesveterinarias.com/>

- Santelices Iglesias OA (2019). Caracterización de sarcomas felinos en sitios de inoculación vacunal en la República Argentina. [Characterization of feline sarcomas at vaccination sites in Argentina]. Doctoral thesis, Universidad Nacional de La Plata, Buenos Aires, Argentina. DOI: <https://www.doi.org/10.35537/10915/78101>
- Santelices Iglesias OA, Zanuzzi CN, Wright C, Duchene AG, Risso MA, Risso P, Nishida F, Lavid A, Ortega Hh, Berengeno AI et al. (2023). Correlación de la expresión del receptor 2 del factor de crecimiento de fibroblastos, del receptor α del factor de crecimiento derivado de plaquetas y de la ciclooxigenasa-2 con la proliferación de células neoplásicas y la vascularización en sarcomas felinos asociados a sitios de inoculación [Correlation of fibroblast growth factor receptor, platelet-derived growth factor receptor and cyclooxygenase-2 expression with neoplastic cell proliferation and vascularization in feline vaccine-associated sarcomas]. *Investigación Veterinaria*, 25(2): 1-8. DOI: <https://www.doi.org/10.62168/invet.v25i2.33>
- Santelices Iglesias OA, Wright C, Duchene AG, Risso MA, Risso P, Zanuzzi CN, Nishida F, Lavid A, Confente F, Díaz M et al. (2018) Association between degree of anaplasia and degree of inflammation with the expression of COX-2 in feline injection site sarcomas. *Journal of Comparative Pathology*, 165: 45-51. DOI: <https://www.doi.org/10.1016/j.jcpa.2018.09.002>
- Sorensen KC, Kitchell BE, Schaeffer DJ, and Mardis PE (2004). Expression of matrix metalloproteinases in feline vaccine site-associated sarcomas. *American Journal of Veterinary Research*, 65(3): 373-379. DOI: <https://www.doi.org/10.2460/ajvr.2004.65.373>
- Soto S, Blatter S, Hobi S, Steck M, Lechmann J, Rüfenacht S, Kühn N, Ruetten M, Ignatenko N, and Krudewig C (2024). Feline facial spindle cell tumors in 29 cats: Histomorphological and immunohistochemical characterization. *Animals*, 14: 1103. DOI: <https://www.doi.org/10.3390/ani14071103>
- Wang D, Cabalag CS, Clemons NJ, and DuBois RN (2021). Cyclooxygenases and prostaglandins in tumor immunology and microenvironment of gastrointestinal cancer. *Gastroenterology*, 161(6): 1813-1829. DOI: <https://www.doi.org/10.1053/j.gastro.2021.09.059>
- Wei Q, Ramsey SA, Larson MK, Berlow NE, Ochola D, Shiprack C, Kashyap A, Séguin B, Keller C, and Löhr CV (2019). Elucidating the transcriptional program of feline injection-site sarcoma using a cross-species mRNA-sequencing approach. *BMC Cancer*, 19: 311. DOI: <https://www.doi.org/10.1186/s12885-019-5501-z>
- Wen B, Wei YT, Mu LL, Wen GR, and Zhao K (2020). The molecular mechanisms of celecoxib in tumor development. *Medicine*, 99(40): e22544. DOI: <https://www.doi.org/10.1097/MD.00000000000022544>
- Wilcock B, Wilcock A, and Bottoms K (2012). Feline postvaccinal sarcoma: 20 years later. *The Canadian Veterinary Journal*, 53(4): 430-434. Available at: <https://pubmed.ncbi.nlm.nih.gov/articles/PMC3299519/>
- Withrow SJ (1998). Soft tissue sarcomas. *Veterinary Quarterly*, 20(1): S16-S17. DOI: <https://www.doi.org/10.1080/01652176.1998.10807387>
- Wojtkowska A, Małek A, Giziński, Sapierzyński R, Rodo A, Sokołowska J, Zabielska-Koczywās KA, Wojtalewicz A, Walewska M, Kautz E et al. (2024). Comparison of MMP-2, MMP-9, COX-2, and PGP expression in feline injection-site and feline noninjection-site sarcomas—Pilot study. *Animals*, 14(14): 2110. DOI: <https://www.doi.org/10.3390/ani14142110>
- Wright C, Zanuzzi CN, Badura E, Duchene AG, Portiansky EL, Barbeito CG, Acuña F, and Santelices Iglesias OA (2023). Expresión de metaloproteinasas y sus inhibidores en sarcomas felinos asociados y no asociados a sitios de inoculación [Expression of metalloproteinases and their inhibitors in feline sarcomas associated and not associated to inoculation sites]. XIII Reunión Argentina de Patología Veterinaria 2023, 17° Seminario de la Fundación C. L. Davis S. W. Thompson. Abstract, pp. 1-110. Available at: <http://hdl.handle.net/20.500.12123/22259>
- Wright C, Marzano G, Barbeito CG, Badura E, Duchene AG, Portiansky EL, Acuña F, and Santelices Iglesias OA (2024). Expresión de VEGF y su receptor en sarcomas felinos asociados y no asociados a sitios de inoculación [Expression of VEGF and its receptor in feline sarcomas associated and not associated with inoculation sites]. XIII Jornadas de Jóvenes Investigadores. Facultad de Ciencias veterinarias, Universidad de Buenos Aires, Argentina FI, pp. 1-209. Available at: <http://invet.fvet.uba.ar/ojs/index.php/revista1/article/view/58/23>
- Zabielska-Koczywās K, Wojtalewicz A, and Lechowski R (2017). Current knowledge on feline injection-site sarcoma treatment. *Acta Veterinaria Scandinavica*, 59(1): 47. DOI: <https://www.doi.org/10.1186/s13028-017-0315-y>
- Žagar Ž and Schmidt JM (2023). A scoping review on tyrosine kinase inhibitors in cats: Current evidence and future directions. *Animals*, 13(19): 3059. DOI: <https://www.doi.org/10.3390/ani13193059>
- Zajc AL, Harper A, Benoit J, and Mason S (2022). Non-injection-site soft tissue sarcoma in cats: Outcome following adjuvant radiotherapy. *Journal of Feline Medicine and Surgery*, 24(8): e183-e193. DOI: <https://www.doi.org/10.1177/1098612X221098961>

Publisher's note: Sciencline Publication Ltd. remains neutral with regard to jurisdictional claims in published maps and institutional affiliations.



Open Access: This article is licensed under a Creative Commons Attribution 4.0 International License, which permits use, sharing, adaptation, distribution and reproduction in any medium or format, as long as you give appropriate credit to the original author(s) and the source, provide a link to the Creative Commons licence, and indicate if changes were made. The images or other third party material in this article are included in the article's Creative Commons licence, unless indicated otherwise in a credit line to the material. If material is not included in the article's Creative Commons licence and your intended use is not permitted by statutory regulation or exceeds the permitted use, you will need to obtain permission directly from the copyright holder. To view a copy of this licence, visit <https://creativecommons.org/licenses/by/4.0/>.