



# Shape Variations of Furcula in Different Avian Species

Funda Aksünger Karaavcı<sup>1\*</sup>, Yasin Demiraslan<sup>2</sup>, and Betül Genç<sup>1</sup>

<sup>1</sup>Department of Anatomy, Faculty of Veterinary Medicine, Bingöl University, Bingöl, 12000, Turkey

<sup>2</sup>Department of Anatomy, Faculty of Veterinary Medicine, Dokuz Eylül University, İzmir, 35890, Turkey

\*Corresponding author's Email: fakaraavci@bingol.edu.tr



## ABSTRACT

The furcula is a distinctive bone in avian species formed by the fusion of the left and right clavicles into a single structure. By acting as a spring during flight, the furcula adjusts the distance between the wing and the shoulder joint, contributing significantly to avian flight. The present study aimed to analyze furcular shapes across several bird species and investigate how these differences influence avian taxonomy. A total of 58 furculae collected from wild adult birds found dead or that died during treatment between 2023 and 2024 were examined. Samples consisted of seven crows, eight Eurasian jays, two eagles, one falcon, 19 pigeons, two storks, 10 sparrowhawks, and nine geese. Furculae were dissected and morphologically examined for overall shape, hypocleideum morphology, and the presence of pneumatic foramina. Morphological examination revealed that the furcula was V-shaped in the crow, Eurasian jay, goose, and pigeon, U-shaped in the eagle, falcon, and sparrowhawk, and Y-shaped in the stork. Geometric morphometric analysis was performed with 38 landmarks. Geometric morphometric analysis revealed that shape variation was primarily concentrated at the scapular ends of the furcula and secondarily in the hypocleideum region. Crow and Eurasian jay samples exhibited relatively similar shape patterns, whereas significant differences were detected among species groups in the canonical variate analysis. The current findings demonstrated species-specific variation in furcular morphology and provided valuable information for avian taxonomy and the functional interpretation of flight-related skeletal adaptations.

**Keywords:** Avian, Furcula, Geometric morphometry, Morphology, Shape

## INTRODUCTION

The pectoral girdle (cingulum membri thoracici) exhibits morphological variation among bird species (Vickaryous and Hall, 2010). The furcula is a distinctive avian bone formed by the fusion of the left and right clavicles into a single structure (Vickaryous and Hall, 2010). The furcula is situated in a mid-ventral position within the avian pectoral apparatus and plays an important role in the structural integration of the shoulder girdle. The hypocleideum serves as an attachment site for pectoral musculature, while the furcula contributes to shoulder and wing movements through its associations with the pectoral girdle elements (Vickaryous and Hall, 2010; Pollard et al., 2017). During flight, the sternum transfers the force to the thorax, allowing the body to withstand the wing flapping (Beaufrère, 2009). The furcula adjusts the distance between the wing and the shoulder joint by acting as a spring, thereby playing an important role in flight (Maina, 1996). In birds, the furcula may exhibit morphological differences in shape depending on the ability to fly (König, 2016).

Several studies have described V-, Y-, and U-shaped furculae based on their morphological characteristics (Parvez et al., 2016; Keneisenuo Choudhary et al., 2020; Sridevi et al., 2020). A ventral projection known as the hypocleideum is located at the junction of the left and right clavicles (Sharma et al., 2022). Additionally, the presence of pneumatic foramina at the proximal ends of the furcula differs among bird species (Höfling and Alvarenga, 2001; John et al., 2014; Keneisenuo Choudhary et al., 2020). In some flightless birds, the clavicles may be absent, preventing the formation of a furcula (König, 2016). Traditional morphometry may be insufficient for accurately evaluating shape variations. As a result, geometric morphometric approaches have gained widespread use in studies investigating biological shape variation (Gündemir et al., 2023; Demiraslan et al., 2023; Gürbüz et al., 2024). Unlike traditional morphometric methods, geometric morphometric analyses evaluate shape independently of size and preserve the geometric relationships among anatomical landmarks, allowing more reliable comparisons of morphological variation among specimens (O'Higgins, 2000). This landmark-based technique enabled the quantitative assessment of morphological differences and provided detailed information on shape variation among structures (Viscosi and Cardini, 2012; Zelditch et al., 2012). By overlaying landmark coordinates in a Cartesian coordinate system, geometric morphometric analysis can detect shape similarities and differences both within and across groups. Landmarks are defined as anatomically corresponding points found in all samples and maintaining the same relative position (Slice, 2007).

Recent studies investigating morphological variation, particularly in zoological sciences, have demonstrated the value and broad applicability of geometric morphometric methods. These approaches have been successfully applied to a

ORIGINAL ARTICLE  
Received: April 08, 2026  
Revised: May 11, 2026  
Accepted: June 05, 2026  
Published: June 25, 2026

wide range of vertebrate taxa and anatomical structures, including os coxae morphology in horses (Gündemir *et al.*, 2020), otolith morphology in fish species (Dörtbudak *et al.*, 2022), cranial shape variation in sheep breeds (Demircioğlu *et al.*, 2024), and functional shape analyses of the avian furcula in relation to flight mechanics and locomotor adaptations (Close and Rayfield, 2012). Although the furcula has been morphologically described in numerous avian species (Parvez *et al.*, 2016; Keneisenuo Choudhary *et al.*, 2020; Sridevi *et al.*, 2020), most previous studies have focused on anatomical descriptions of individual species. In contrast, geometric morphometric analyses have been applied to investigate morphological variation in both avian and mammalian skeletal structures, including the carina sterni in birds (Gündemir *et al.*, 2023), the occipital region and foramen magnum in mammals (Demiraslan *et al.*, 2023), and the orbit in small ruminants (Gürbüz *et al.*, 2024). However, comparative studies evaluating variation in furcular shape among avian taxa using geometric morphometric methods remain limited. Therefore, evaluating furcular morphology alongside geometric morphometric shape variation across a broad range of bird species may contribute to a greater understanding of avian diversity and the potential taxonomic significance of the furcula. The present study aimed to compare furcular morphology and shape variation among bird species belonging to different orders and families using morphological examination and geometric morphometric analysis, and to evaluate whether these characteristics reflect taxonomic relationships and may contribute to avian taxonomy.

## MATERIALS AND METHODS

### Ethical approval

All applicable ethical standards were followed during the conduct of the present study. The samples used in the present study were obtained in accordance with the relevant ethical approvals and legal permissions. Ethical approval was granted by the Bingöl University Local Ethics Committee for Animal Experiments (HADYEK; Approval No. E-85680299-020-169619; 08.08.2024). No animals were euthanized specifically for this study.

### Samples

The samples used in the present study were obtained from the Bingöl Provincial Branch Directorate of Nature Conservation and National Parks, Bingöl, Türkiye, and transferred to the Department of Anatomy, Faculty of Veterinary Medicine, Bingöl University, Bingöl, Türkiye. The samples consisted of birds that had been found dead in the wild or had died during treatment; no animals were euthanized specifically for the present investigation. Therefore, sample sizes differed among species, and larger sample sizes were unavailable for some taxa. Species availability within the collection, representation of different taxonomic groups, and the presence of sufficiently preserved furculae suitable for morphological and geometric morphometric analyses were considered during sample selection. Bird species representing different avian orders and families were selected to enable a comparative assessment of furcular morphology and shape variation. Only samples with intact furculae and preserved anatomical integrity, showing no visible fractures, deformation, or postmortem damage that could influence morphological assessment or landmark digitization, were included in the present study. A total of 58 furculae obtained from 58 individual adult birds were examined, including seven crows (*Corvus corone*), eight Eurasian jays (*Garrulus glandarius*), two eagles (*Aquila chrysaetos*), one falcon (*Falco peregrinus*), nine geese (*Anser cygnoides domesticus*), nineteen pigeons (*Columba livia*), two storks (*Ciconia ciconia*), and ten sparrowhawks (*Accipiter nisus*). All samples were considered adults based on the degree of skeletal ossification and fusion observed in the examined bones. However, sex information was not available for the samples.

### Morphology, imaging, and digitization

Birds that were found dead in the wild or died during veterinary treatment prior to inclusion in the study were transferred to the Department of Anatomy, Faculty of Veterinary Medicine, Bingöl University (Bingöl, Türkiye) and subsequently subjected to maceration. The use of naturally deceased specimens has been widely accepted in osteological, zooarchaeological, and avian postmortem investigations (Reitz and Wing, 2008; Garcês *et al.*, 2018; 2020). Following morphological examination, each furcula was positioned in a standardized cranial view and photographed using a smartphone camera (Samsung Galaxy S22 Ultra, South Korea). A thin-plate spline (TPS) file was generated from the digital images using TPSUtil (Version 1.79; Rohlf, 2019), and a total of 38 landmarks, including six homologous landmarks, were digitized on the cranial-view digital images using TPSDig2 (Version 2.64; Rohlf, 2018). Homologous landmarks were determined as the lateral corner of the right facies articularis acrocoracoidea (LM1), the medial corner of the right facies articularis acrocoracoidea (LM38), the medial corner of the left facies articularis acrocoracoidea (LM19), the lateral corner of the left facies articularis acrocoracoidea (LM20), the caudal end of the junction of the clavicles (LM10), and the cranial end of the junction of the clavicles (LM29). The x and y Cartesian coordinates of the digitized landmarks on the cranial-view images were obtained for subsequent geometric morphometric analyses. The naming of

anatomical structures followed the guidelines provided by Nomina Anatomica Avium (Baumel et al., 1993).

### Statistical analysis

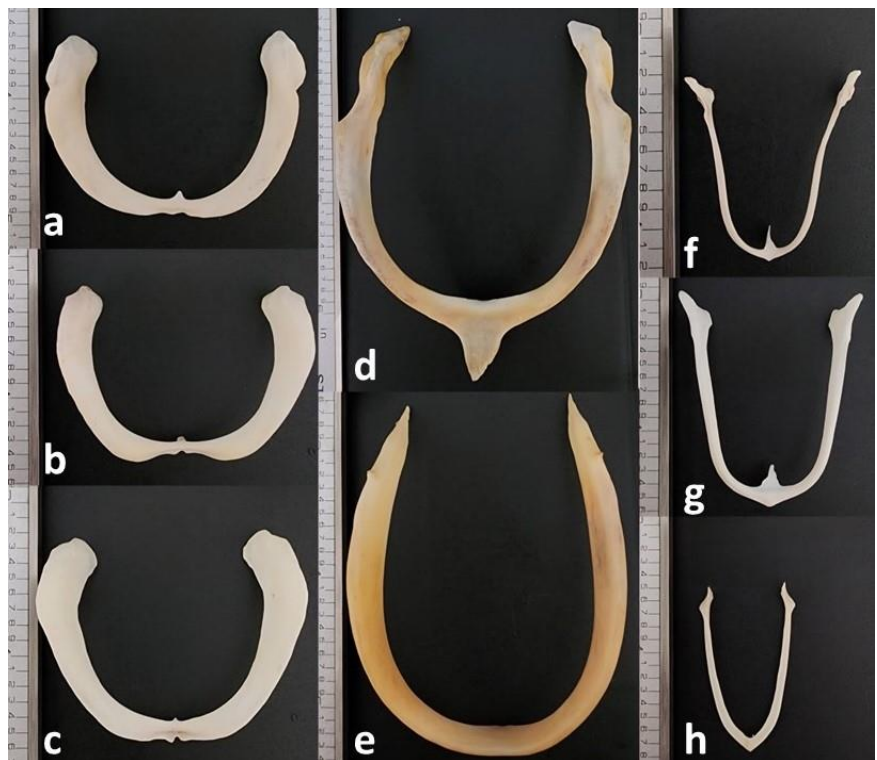
Differences in size, position, and orientation among samples were removed using general Procrustes analysis (Slice, 2007). The Procrustes-aligned coordinates were subsequently subjected to principal components analysis (PCA) to identify the principal axes of shape variation among the furculae. The first principal component (PC1) and second principal component (PC2) were used to assess the major patterns of morphological variation and visualize shape changes along these axes. The effect of size on shape variation (allometry) was evaluated using multivariate regression of shape variables on centroid size. The significance of the regression was assessed using permutation tests (10,000 permutations). Canonical variate analysis (CVA) was performed to assess shape differences among groups and to evaluate patterns of group separation. Statistical significance was assessed using permutation tests (10,000 permutations), and group differences were evaluated based on Mahalanobis distances, Procrustes distances, and Pillai's trace statistics. A significance level of p-value less than 5% ( $p < 0.05$ ) was adopted for all statistical analyses. All geometric morphometric analyses were conducted using MorphoJ software (Klingenberg, 2011). Because some species were represented by a limited number of samples, particularly the falcon ( $n = 1$ ), eagle ( $n = 2$ ), and stork ( $n = 2$ ), the results for these taxa were interpreted with caution. Nevertheless, these samples were retained in the analyses to broaden the comparative framework and represent the available taxonomic diversity within the study material.

## RESULTS

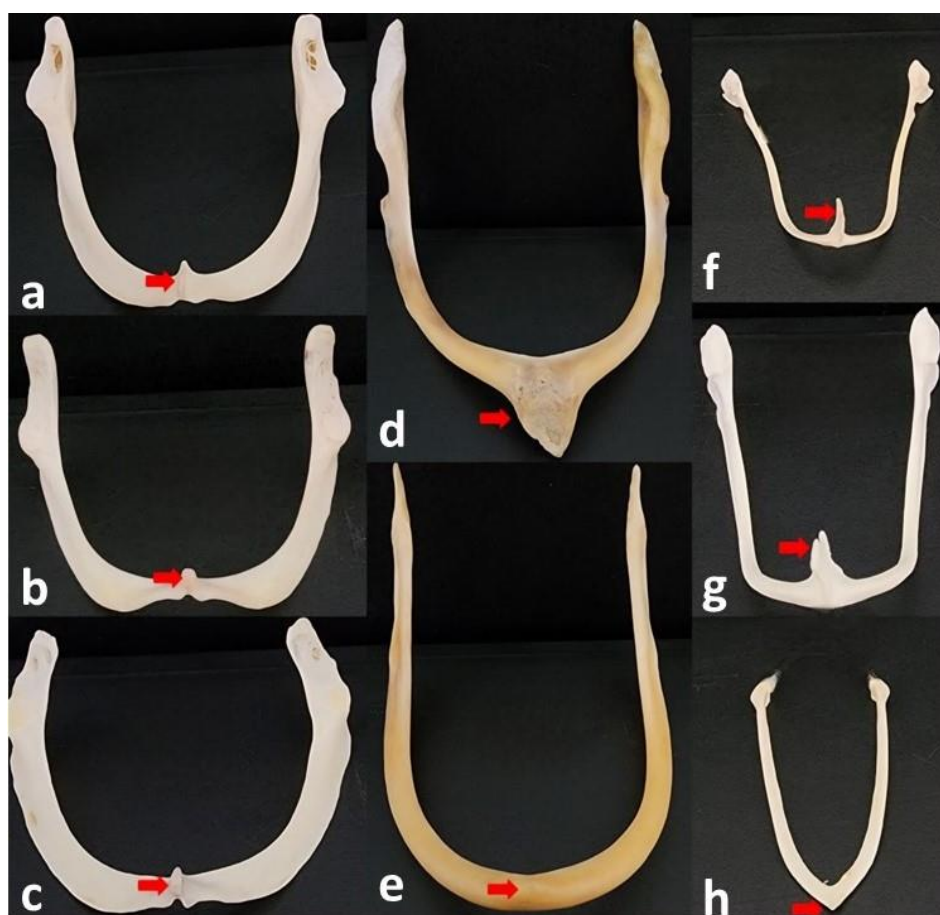
### Morphological findings

In all analyzed species, the right and left clavicles converged ventrally and formed the furcula. The furcula was V-shaped in pigeons, Y-shaped in storks, and U-shaped in crows, Eurasian jays, eagles, falcons, geese, and sparrowhawks (Figure 1). The hypocleideum, located at the fusion of the right and left clavicles, was not very prominent in geese. The hypocleideum was located caudally in eagles, sparrowhawks, and falcons, and ventrally as a simple protrusion in pigeons. Crows and Eurasian jays had a prominent caudally directed hypocleideum. In storks, the proximal half of the clavicles was medio-laterally flattened, whereas the distal half was cylindrical (Figure 2). In pigeons, the right and left clavicles were rod-shaped. The clavicles were medio-laterally flattened at all levels in all species except storks. In storks, the proximal half of the clavicles was medio-laterally flattened, whereas the distal half was cylindrical (Figure 1).

Pneumatic foramina were located on the proximal extremity of both clavicles of the furcula in different numbers and sizes, laterally in crows, Eurasian jays, falcons, eagles, geese, and sparrowhawks, and medially in storks. Pneumatic foramina were not found in pigeons. Pneumatic foramina were recorded during direct anatomical examination; however, because their visualization required high magnification, they were not clearly demonstrable in the figures without compromising the overall anatomical context of the furcula.



**Figure 1.** Cranial view of the furculae in different bird species. a: Sparrowhawk, b: Falcon, c: Eagle, d: Stork, e: Goose, f: Eurasian jay, g: Crow, h: Pigeon

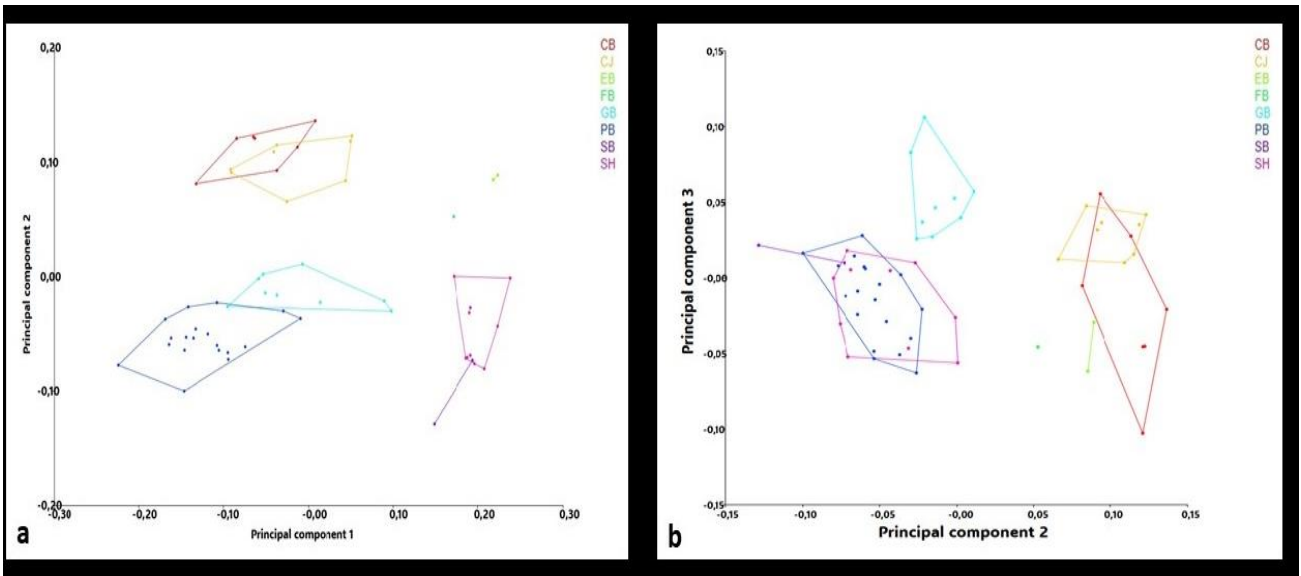


**Figure 2.** Caudal view of the furculae showing variation in the morphology of the hypocleideum among different bird species. **a:** Sparrowhawk, **b:** Falcon, **c:** Eagle, **d:** Stork, **e:** Goose, **f:** Eurasian jay, **g:** Crow, **h:** Pigeon. The tip of the red arrow indicates the hypocleideum.

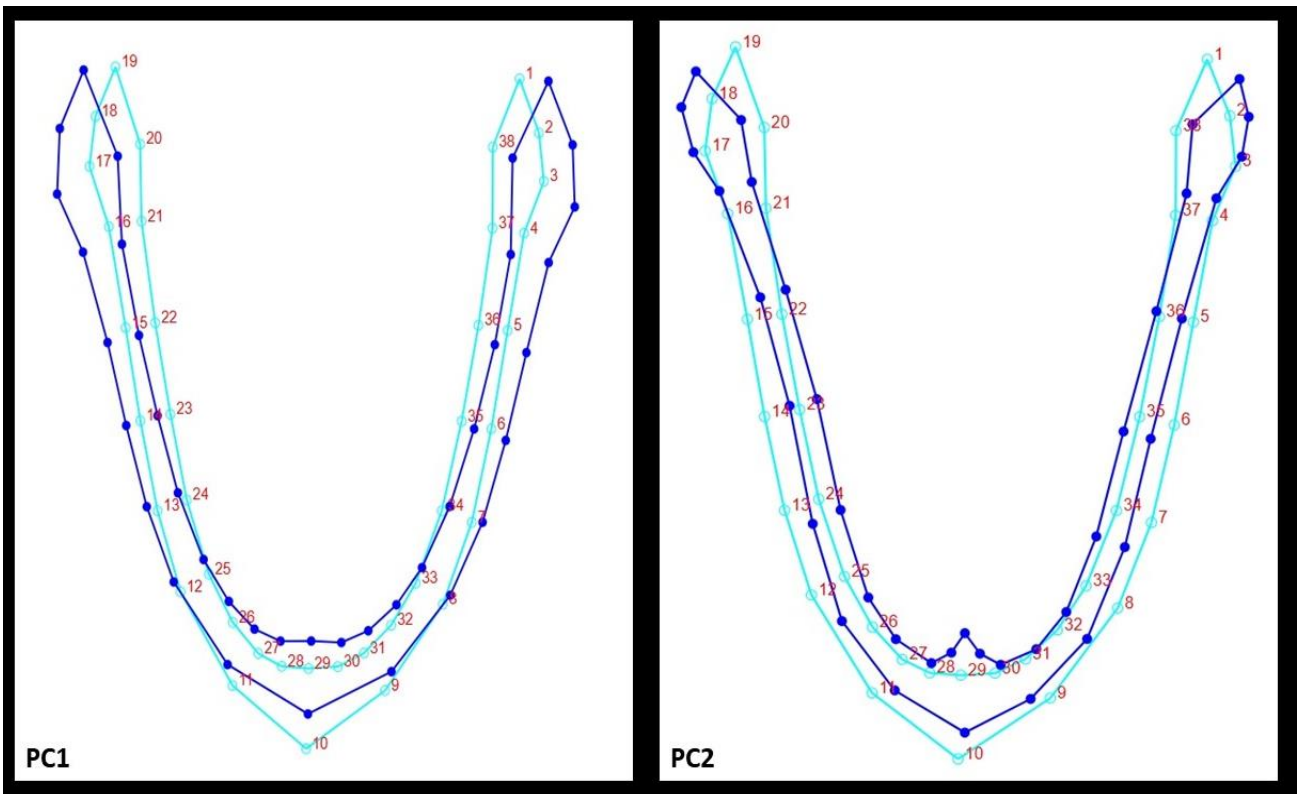
### Geometric morphometry analysis

Regression analysis demonstrated that the centroid size of the furcula accounted for 8.6525% of the variation in furcula shape ( $p = 0.0011$ ). Since the allometric effect was statistically significant, residuals obtained from regressing shape variables on centroid size were extracted from the Procrustes coordinates and used in all subsequent analyses. In the present study, 57 principal components were calculated for the furcula. The PC1 accounted for 62.885% of the total shape variation, whereas the first two principal components (PC1+PC2) accounted for 82.230% of the total shape variation. The PC1 primarily reflected shape variation at the scapular ends of the furcula, whereas PC2 was mainly associated with variation in the hypocleideum region. The distribution of samples along PC1 and PC2 was illustrated in Figure 3. Along PC1, crow and Eurasian jay samples demonstrated a closely overlapping distribution pattern, whereas pigeon and sparrowhawk samples occupied more distinct regions of the morphospace. Falcon samples were positioned intermediate between the overlapping crow-Eurasian jay cluster and the more distinct pigeon and sparrowhawk groups. The distribution of the remaining species indicated different degrees of separation and overlap among groups (Figure 3). Figure 4 illustrates the landmarks contributing most strongly to shape variation along PC1 and PC2. The greatest shape variation was observed at the scapular ends of the furcula, followed by pronounced variation in the hypocleideum among species.

The data obtained from canonical variate analysis are presented in Table 1. A total of seven canonical variables (CV1-CV2) were calculated. The first CV1 accounted for 56.286% of the morphological variation and primarily reflected interspecific differences in corpus curvature, scapular end orientation, and hypocleideum shape (Figure 5). Pairwise comparisons based on Procrustes distances indicated significant differences in furcula shape among most species pairs, particularly between crow and pigeon, crow and sparrowhawk, Eurasian jay and goose, and pigeon and sparrowhawk ( $p < 0.05$ ; Table 1). No significant differences were detected between crow and falcon, Eurasian jay and falcon, eagle and falcon, eagle and stork, falcon and goose, falcon and pigeon, falcon and stork, or falcon and sparrowhawk ( $p > 0.05$ ; Table 1). The average furcula shape for each species is shown in Figure 5. In the crow and Eurasian jay, the corpus exhibited a medial slope, while the scapular tips were directed laterally. The ventral prominence of the hypocleideum was less pronounced in eagles, falcons, and sparrowhawks, but more prominent in crows, Eurasian jays, geese, pigeons, and storks.



**Figure 3.** Principal component analysis (PCA) scatter plot showing the distribution of furcula shape variation among the examined bird species. **a:** Scatter plot of principal component 1 (PC1) compared to PC2, **b:** Scatter plot of PC2 compared to PC3. The principal components represent the major axes of shape variation in the dataset. Species located closer together exhibit more similar furcula morphologies, whereas those positioned farther apart display greater morphological differences. CB: Crow, CJ: Eurasian jay, EB: Eagle, FB: Falcon, GB: Goose, PB: Pigeon, SB: Stork, SH: Sparrowhawk.

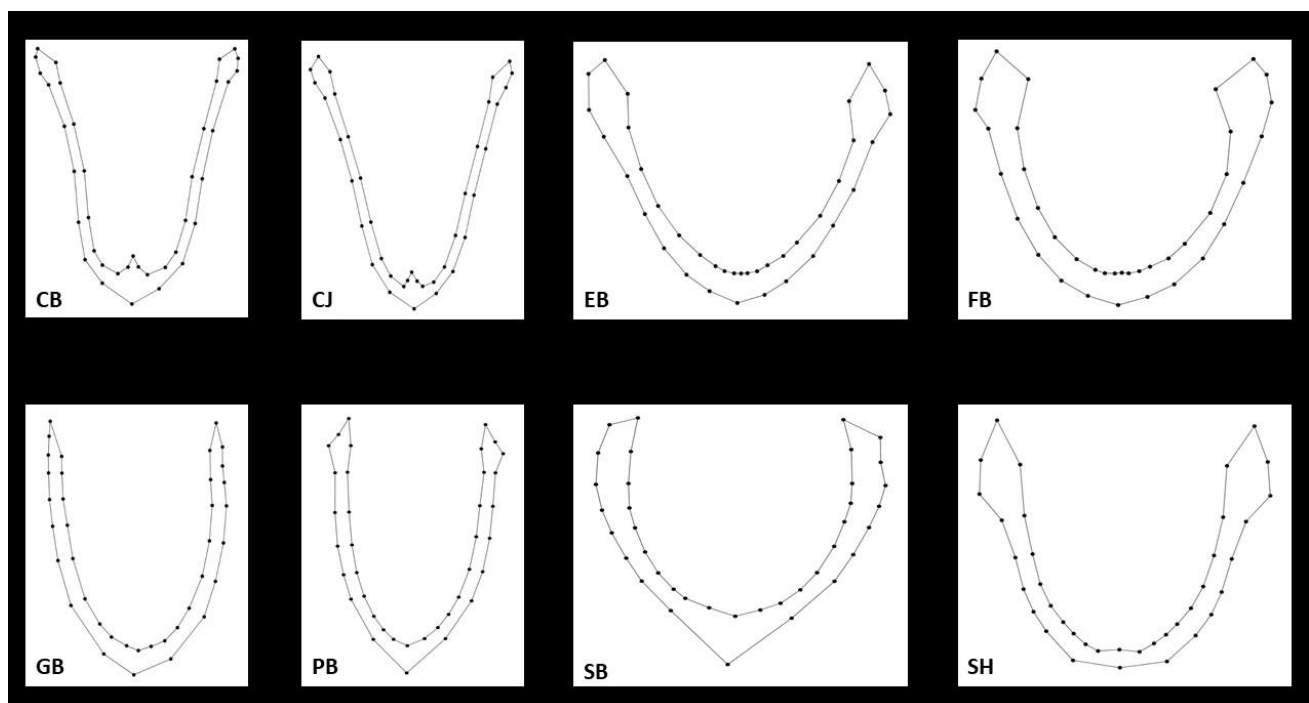


**Figure 4.** Wireframe graphical representation of furcula shape variation along principal component 1 (PC1) and principal component 2 (PC2). Dark blue represents the mean furcula shape, whereas light blue represents the shape configuration associated with variation along the respective principal component.

**Table 1.** Pairwise comparisons of furcula shape among the examined bird species based on Mahalanobis distances, Procrustes distances, and Pillai's trace statistics

Species	Statistic	CB	CJ	EB	FB	GB	PB	SB	SH
<b>CB</b>	MD	—	20.4583	50.0932	46.8808	38.6032	34.6839	47.2864	51.2434
	Pillai's P-value	—	0.4495	0.9512	0.9346	0.1919	0.9992	0.9919	0.0556
	PD	—	0.0658	0.2914	0.2493	0.1955	0.1756	0.3393	0.2779
	P-value	—	0.0461	0.0287	0.1230	0.0001	< 0.0001	0.0260	< 0.0001
<b>CJ</b>	MD	20.4583	—	53.3087	52.1876	39.2409	29.7080	46.8456	50.3137
	Pillai's P-value	0.4495	—	0.2999	0.8567	0.7799	0.8388	0.9612	0.7665
	PD	0.0658	—	0.2610	0.2275	0.1963	0.1994	0.3361	0.2620
	P-value	0.0461	—	0.0221	0.0705	< 0.0001	< 0.0001	0.0094	< 0.0001
<b>EB</b>	MD	50.0932	53.3087	—	22.2200	60.1618	61.7644	58.4511	37.2841
	Pillai's P-value	0.9512	0.2999	—	0.6607	0.4914	0.0591	0.3347	0.1219
	PD	0.2914	0.2610	—	0.0855	0.2982	0.3755	0.2491	0.1384
	P-value	0.0287	0.0221	—	0.3290	0.0193	0.0056	0.3347	0.0124
<b>FB</b>	MD	46.8808	52.1876	22.2200	—	59.9713	58.3066	56.2191	34.9491
	Pillai's P-value	0.9346	0.8567	0.6607	—	0.3229	0.0012	0.3280	0.7987
	PD	0.2493	0.2275	0.0855	—	0.2639	0.3245	0.2388	0.1224
	P-value	0.1230	0.0705	0.3290	—	0.0968	0.0509	0.3280	0.0625
<b>GB</b>	MD	38.6032	39.2409	60.1618	59.9713	—	26.9442	34.7629	56.9223
	Pillai's P-value	0.1919	0.7799	0.4914	0.3229	—	0.2324	0.6123	0.8617
	PD	0.1955	0.1963	0.2982	0.2639	—	0.1720	0.2232	0.2503
	P-value	0.0001	< 0.0001	0.0193	0.0968	—	< 0.0001	0.0085	< 0.0001
<b>PB</b>	MD	34.6839	29.7080	61.7644	58.3066	26.9442	—	32.3790	53.5977
	Pillai's P-value	0.9992	0.8388	0.0591	0.0012	0.2324	—	0.8519	0.9993
	PD	0.1756	0.1994	0.3755	0.3245	0.1720	—	0.3300	0.3180
	P-value	< 0.0001	< 0.0001	0.0056	0.0509	< 0.0001	—	0.0045	< 0.0001
<b>SB</b>	MD	47.2864	46.8456	58.4511	56.2191	34.7629	32.3790	—	46.3074
	Pillai's P-value	0.9919	0.9612	0.3347	0.3280	0.6123	0.8519	—	0.5037
	PD	0.3393	0.3361	0.2491	0.2388	0.2232	0.3300	—	0.1941
	P-value	0.0260	0.0094	0.3347	0.3280	0.0085	0.0045	—	0.0117
<b>SH</b>	MD	51.2434	50.3137	37.2841	34.9491	56.9223	53.5977	46.3074	—
	Pillai's P-value	0.0556	0.7665	0.1219	0.7987	0.8617	0.9993	0.5037	—
	PD	0.2779	0.2620	0.1384	0.1224	0.2503	0.3180	0.1941	—
	P-value	< 0.0001	< 0.0001	0.0124	0.0625	< 0.0001	< 0.0001	0.0117	—

CB: Crow, CJ: Eurasian jay, EB: Eagle, FB: Falcon, GB: Goose, PB: Pigeon, SB: Stork, and SH: Sparrowhawk, MD: Mahalanobis distance, Pillai's P-value: P-value calculated for Pillai's trace from permutation tests (10,000 rounds), PD: Procrustes distance, P-value: P-value calculated for Procrustes distance from permutation tests (10,000 rounds). The MD and PD values indicated significant pairwise differences between species in rows and columns at  $p < 0.05$ . Diagonal cells were not applicable because a species cannot be compared with itself.



**Figure 5.** Mean furcula shapes of the examined bird species. CB: Crow, CJ: Eurasian jay, EB: Eagle, FB: Falcon, GB: Goose, PB: Pigeon, SB: Stork, SH: Sparrowhawk.

## DISCUSSION

In the present study, the furcula exhibited notable shape variation among the bird species examined, with these differences especially evident at the scapular ends and the hypocleideum. Notably, the ventral prominence of the hypocleideum was limited in eagles, falcons, and sparrowhawks, which are prey birds. The observed variation in furcula shape may be associated with differences in hunting behavior, feeding ecology, and flight characteristics among species. Similar relationships between furcula morphology and functional or flight-related adaptations have previously been reported in birds (Bailey and DeMont, 1991; Hui, 2002). Likewise, the present study identified notable variation in the scapular ends and hypocleideum among species, supporting the view that furcula morphology may reflect functional and ecological differences among birds.

Previous studies have reported both V- and U-shaped furculae in pigeons. While Sridevi et al. (2020) described a V-shaped furcula, Parvez et al. (2016) reported a U-shaped configuration in pigeons. In the current study, all pigeon samples exhibited a V-shaped furcula, supporting the observations of Sridevi et al. (2020) and indicating potential variation in population, breed, or sampling across studies. A U-shaped furcula has been reported in geese (Getty, 1975), small Indian kites (Sharma et al., 2022), green-winged macaws (Indu et al., 2012), brown wood owls and crested serpent eagles (Keneisenuo Choudhary et al., 2020), crows (Sridevi et al., 2020), common hawk-cuckoo (Supriya et al., 2019), and pariah kites (Tomar et al., 2010). Similarly, the furcula was U-shaped in crows, Eurasian jays, eagles, sparrowhawks, geese, and falcons in the present study. The U-shaped furcula observed in geese was consistent with the report of Getty (1975), whereas the findings in crows were consistent with those of Sridevi et al. (2020). Comparable U-shaped furculae have been reported in green-winged macaws and peahens (Indu et al., 2012), crested serpent eagles and brown wood owls (Keneisenuo Choudhary et al., 2020), and small Indian kites and domestic fowl (Sharma et al., 2022). In the sparrowhawk, unlike the other bird species, the ventral margin of the furcula exhibited a distinct notch. The furculae of the eagle, sparrowhawk, and falcon were very similar to each other and exhibited a broad U-shaped configuration. In contrast, the furcula of the crow and Eurasian jay exhibited a narrower U-shaped configuration.

Höfling and Alvarenga (2001) reported the absence of the hypocleideum in birds belonging to the families Picidae, Indicatoridae, Galbulidae, and Coraciformes. Similarly, the hypocleideum was reported to be absent in the brown wood owl (Keneisenuo Choudhary et al., 2020) and Indian horned owl (Sridevi et al., 2020), absent or rudimentary in the small Indian kite (Sharma et al., 2022), and rudimentary in ducks (Rajani et al., 2018). In agreement with these findings, the hypocleideum was rudimentary in geese in the present study. In pigeons, Sridevi et al. (2020) reported the absence of the hypocleideum, whereas Jayachitra and Iniyah (2021) and Parvez et al. (2016) described an underdeveloped hypocleideum in domestic pigeons (*Columba livia*). In the present study, the hypocleideum was identified as a simple protrusion in pigeons, confirming the structure reported by Jayachitra and Iniyah (2021) and Parvez et al. (2016), though it differed from the findings of Sridevi et al. (2020). Keneisenuo Choudhary et al. (2020) reported the presence of a hypocleideum in the crested serpent eagle. Similarly, a simple hypocleideal protrusion was observed in eagles, sparrowhawks, and falcons in the present study. Sharma et al. (2022) reported a well-developed hypocleideum in domestic fowl (*Gallus domesticus*), whereas Jayachitra and Iniyah (2021) described a flattened plate-like hypocleideum. In the present study, a prominent caudally directed hypocleideum was observed in crows and Eurasian jays, whereas the hypocleideum in storks was flattened in the cranio-caudal direction and prominently elongated ventrally. Höfling and Alvarenga (2001) reported the presence of pneumatic foramina at the omal extremity of both clavicles in Ramphastidae (*Ramphastos tucanus*), Picidae (except the genus *Picumnus*, such as *Picoides major*), Indicatoridae (*Indicator indicator*), and Passeriformes (*Corvus brachyrhynchus*). Similarly, Keneisenuo Choudhary et al. (2020) reported lateral pneumatic foramina in the clavicle of the crested serpent eagle, whereas John et al. (2014) described them in crows. The absence of pneumatic foramina in pigeons, as observed in the current study, aligns with the findings of John et al. (2014), who reported that pneumatic foramina were absent from the clavicles of pigeons and owls, while such foramina were present on the lateral surface of the clavicles in crows. In the present study, pneumatic foramina with different numbers and sizes were observed on the lateral surface of the clavicle in crows, Eurasian jays, eagles, falcons, geese, and sparrowhawks. The occurrence of lateral pneumatic foramina in crows and eagles was consistent with the findings of John et al. (2014) and Keneisenuo Choudhary et al. (2020), respectively. In contrast, pneumatic foramina were observed on the medial surface of the clavicle in storks, a feature not reported in the cited studies.

## CONCLUSION

Geometric morphometric analysis revealed notable interspecific differences in furcula morphology among the bird species examined. The observed shape variation was mainly associated with the scapular extremities and the hypocleideum region, which contributed substantially to species differentiation. Similarities in furcula morphology were

observed among some closely related taxa, although clear separation among all taxonomic groups was not evident. The current findings indicated that furcula morphology can provide valuable information for comparative anatomy, avian taxonomy, and functional interpretations of flight biomechanics. One limitation of the present study was the relatively small sample size for some species, particularly eagle, falcon, and stork specimens. Future studies involving larger sample sizes and a broader range of avian taxa are needed to further validate and expand the present findings.

## DECLARATIONS

### Authors' contributions

Funda Aksünger Karaavcı and Yasin Demiraslan participated in the design of this study, Funda Aksünger Karaavcı and Betül Genç prepared the furcula samples and performed the morphological analyses. Yasin Demiraslan performed the geometric morphometric analyses. Funda Aksünger Karaavcı and Yasin Demiraslan wrote the manuscript. All authors have read and confirmed the final edition of the manuscript for publication.

### Availability of data and materials

The datasets generated and/or analyzed during the current study are available from the corresponding author upon reasonable request.

### Competing interests

The authors affirmed that there are no competing interests.

### Ethical considerations

The author declares that this manuscript is an original study, has not been published previously, and is not under consideration for publication elsewhere. The authors further confirmed that the manuscript is free from plagiarism and complies with accepted ethical and publication standards. Artificial intelligence (Grammarly) was used solely to assist with English language editing, and ChatGPT (OpenAI) was used for the initial preparation of the graphical abstract. The graphical abstract revised text of the manuscript was subsequently reviewed and manually modified by the authors. No artificial intelligence tools were used in the study design, data collection, data analysis, interpretation of results, or formulation of scientific conclusions. All scientific content, analyses, interpretations, and conclusions were developed and verified by the authors, who take full responsibility for the content of the manuscript and graphical abstract.

### Funding

This study did not receive any external funding. All expenses related to the study were covered by the authors.

## REFERENCES

- Bailey JP and Demont ME (1991). The function of the wishbone. *Canadian Journal of Zoology*, 69(11): 2751-2758. DOI: <https://www.doi.org/10.1139/z91-387>
- Baumel JJ, King SA, Breazile J, Evans HE, and Berge JCV (1993). *Handbook of avian anatomy: Nomina anatomica avium*, 2<sup>nd</sup> Edition. Nuttall Ornithological Club Cambridge, pp. 257-299. Available at: <https://www.biodiversitylibrary.org/bibliography/196965>
- Beaufrère H (2009). A review of biomechanic and aerodynamic considerations of the avian thoracic limb. *Journal of Avian Medicine and Surgery*, 23(3): 173-185. DOI: <https://www.doi.org/10.1647/2007-023.1>
- Close RA and Rayfield EJ (2012). Functional morphometric analysis of the furcula in Mesozoic birds. *PLoS One*, 7(5): e36664. DOI: <https://www.doi.org/10.1371/journal.pone.0036664>
- Demircioğlu İ, Demiraslan Y, Güzel BC, Koçyiğit A, and Demircioğlu A (2024). Comparison of cranium shape in Hamdani and Awassi sheep using dorsal and lateral landmarks. *Pakistan Journal of Zoology*, 56(1): 141-146. DOI: <https://www.doi.org/10.17582/journal.pjz/20220613180648>
- Demiraslan Y, Demircioğlu I, Gürbüz İ, Karaavcı FA, Ortadeveci A, and Özgel Ö (2023). Could there be a relationship between feeding characteristics and the shape of condylus occipitalis and foramen magnum in mammals?. *Turkish Journal of Veterinary & Animal Sciences*, 47(4): 386-396. DOI: <https://www.doi.org/10.55730/1300-0128.4307>
- Dörtbudak MY, Demiraslan Y, and Demircioğlu I (2022). Geometric analysis of otoliths in Cyprinion kais and Cyprinion macrostomus. *Anatomia Histologia Embryologia*, 51(6): 696-702. DOI: <https://www.doi.org/10.1111/ahc.12843>
- Garcês A, Soeiro V, Lóio S, Prada J Silva F, and Pires I (2018). Necropsy findings and causes of mortality in wild birds in a center for rehabilitation of wild animals in the North of Portugal. *Revista Electronica de Veterinaria*, 66(4): 484-493. Available at: <https://www.veterinaria.org/revista/redvet/n040418.html>

- Garcês A, Pires I, Pacheco F, Fernandes LS, Soeiro V, Lóio S, Prada J, Cortes R, and Queirog F (2020). Natural and anthropogenic causes of mortality in wild birds in a wildlife rehabilitation center in Northern Portugal: A ten-year study. *Bird Study*, 66(4): 484-493. DOI: <https://www.doi.org/10.1080/00063657.2020.1726874>
- Getty R (1975). Sisson and grossman's the anatomy of domestic animals, 5<sup>th</sup> Edition. W. B. Saunders Co., Philadelphia, pp. 1790-1801. Available at: <https://search.worldcat.org/title/1057726>
- Gündemir O, Özkan E, Ince NG, Pazvant G, Demircioğlu I, Aydoğdu S, Koçyiğit A, and Dayan MO (2020). Investigation of os coxae in horses using geometric morphometry method. *Harran Üniversitesi Veteriner Fakültesi Dergisi*, 9(2): 170-176. DOI: <https://www.doi.org/10.31196/huvfd.801569>
- Gündemir MG, Szara T, Spataru C, Demircioglu I, Turek B, Petrovas G, and Spataru MC (2023). Shape differences of the Carina sterni in birds of various locomotion types. *Anatomia Histologia Embryologia*, 52(2): 190-196. DOI: <https://www.doi.org/10.1111/ah.12870>
- Gürbüz İ, Demiraslan Y, Demircioğlu I, Karaavci FA, and Özgel Ö (2024). Orbital shape in goat and sheep: Symmetric analysis. *Anatomia, Histologia, Embryologia*, 53(3): e13033. DOI: <https://www.doi.org/10.1111/ah.13033>
- Höfling E and Alvarenga HMF (2001). Osteology of the shoulder girdle in Piciformes, Passeriformes and related groups of birds. *Zoologischer Anzeiger*, 240: 196-208. DOI: <https://www.doi.org/10.1078/0044-5231-00016>
- Hui CA (2002). Avian furcula morphology may indicate relationships of flight requirements among birds. *Journal of Morphology*, 251: 284-293. DOI: <https://www.doi.org/10.1002/jmor.1089>
- Indu VR, Lucy KM, Sreeranjini AR, Maya S, Ashok N, and Syam KV (2012). A comparative study on the pectoral girdle of green winged macaw and peahen. *Journal of Veterinary and Animal Sciences*, 43: 56-58. Available at: <https://agris.fao.org/search/en/providers/122436/records/67599585c7a957febd3e52>
- Jayachitra S and Iniyah K (2021). Comparative gross anatomy of pectoral girdle in domestic fowl (*Gallus domesticus*) and pigeon (*Columba livia*). *The Haryana Veterinarian*, 60(2): 289-290. Available at: <https://krishikosh.egranth.ac.in/items/e6d2407e-a0c2-43de-9959-a2a1a1e27c56>
- John MA, Sasan JS, Singh AD, and Choudhury AR (2014). Comparative morphometry of the shoulder girdle of pigeon (*Columba livia*), crow (*Corvus splendens*) and owl (*Otus bakomoena*). *The Indian Veterinary Journal*, 91(4): 43-45.
- Keneisenuo Choudhary OP, Debroy S, Arya RS, Kalita PC, Doley PJ, Rajkhowa TK, and Kalita A (2020). Comparative gross anatomical studies on the shoulder girdle of crested serpent eagle (*Spilornis cheela*) and brown wood owl (*Strix leptogrammica*). *Indian Journal of Animal Research*, 54(5): 570-572. DOI: <https://www.doi.org/10.18805/ijar.B-3819>
- Klingenberg CP (2011). MorphoJ: An integrated software package for geometric Morphometrics. *Molecular Ecology Resources*, 11: 353-357. DOI: <https://www.doi.org/10.1111/j.1755-0998.2010.02924.x>
- König HE (2016). Avian anatomy, 2<sup>nd</sup> Edition. Textbook and colour Atlas. 5m Books Ltd. Available at: <https://www.5mbooks.com/product/avian-anatomy/>
- Maina JN (1996). Perspectives on the structure and function in birds. In: W. J. Rosskopf and R. W. Woerpel (Editors). *Diseases of cage and aviary birds*, 3<sup>rd</sup> Edition. Williams & Wilkins., Baltimore, MD, pp. 163-217. Available at: [https://books.google.com/books/about/Diseases\\_of\\_Cage\\_and\\_Aviary\\_Birds.html?id=DCYuAAAAMAAJ](https://books.google.com/books/about/Diseases_of_Cage_and_Aviary_Birds.html?id=DCYuAAAAMAAJ)
- O'Higgins P (2000). The study of morphological variation in the hominid fossil record: Biology, landmarks and geometry. *Journal of Anatomy*, 197: 103-120. DOI: <https://www.doi.org/10.1046/j.1469-7580.2000.19710103.x>
- Parvez MNH, Akter M, Gofur M, and Sarder M (2016). Gross morphometry of pectoral girdle of domestic pigeon (*Columba livia*). *International Journal of Livestock Research*, 6(6): 32-38. DOI: <https://www.doi.org/10.5455/ijlr.20160412082409>
- Pollard AS, Boyd S, McGonnell IM, and Pitsillides AA (2017). The role of embryo movement in the development of the furcula. *Journal of Anatomy*, 230(3): 435-443. DOI: <https://www.doi.org/10.1111/joa.12564>
- Reitz EJ and Wing ES (2008). *Zooarchaeology*, 2<sup>nd</sup> Edition. Cambridge University Press., Cambridge, UK. pp. 1-10. DOI: <https://www.doi.org/10.1017/CBO9780511841354>
- Rajani C, Surjith K, Deepa P, and Patki H (2018). Morphological studies of pectoral limb bones in ostrich (*Struthio camelus*), duck (*Anas platyrhynchos domesticus*) and domestic fowl (*Gallus gallus domesticus*). *Indian Journal of Veterinary Anatomy*, 30(2): 88-91. Available at: <https://www.cabidigitallibrary.org/doi/full/10.5555/20193066630>
- Rohlf FJ (2018). TpsDig, version 2.31. Ecology & Evolution, SUNY at Stone Brook, USA. Available at: <http://life.bio.sunysb.edu/morph/index.html>
- Rohlf FJ (2019). TpsUtil program, Version 1.79. Ecology & Evolution, SUNY at Stone Brook, USA. Available at: <http://life.bio.sunysb.edu/morph/index.html>
- Sharma A, Kaushik PK, and Dubal SC (2022). A comparative study on the pectoral girdle of small Indian kite (*Milvus migrans govinda*) and domestic fowl (*Gallus gallus*). *Veterinary Practitioner*, 23(1): 82-84. Available at: <https://www.cabidigitallibrary.org/doi/pdf/10.5555/20230428542>
- Slice DE (2007). Geometric morphometrics. *Annual Review of Anthropology*, 36: 261-281. DOI: <https://www.doi.org/10.1146/annurev.anthro.34.081804.120613>
- Sridevi P, Rajalakshmi K, and SivaKumar M (2020). Comparative gross anatomical studies on the shoulder girdle of great Indian horned owl, pigeon and crow. *Journal of Entomology and Zoology Studies*, 8(2): 51-54. Available at: <https://www.entomoljournal.com/archives/?year=2020&vol=8&issue=2&ArticleId=6400>
- Supriya B, Manjunatha K, and Jamuna KV (2019). Comparative morphological study of pectoral limb bones of common hawk cuckoo (*Hierococcyx varius*) and yellow billed babbler (*Argya affinis*). *International Journal of Current Microbiology Applied Sciences*, 8(2): 1780-1784. DOI: <https://www.doi.org/10.20546/ijemas.2019.812.213>

- Tomar MPS, Vaish R, Rajput N, and Shrivastav AB (2010). Gross morphometrical studies on pectoral girdle of Pariah kite (*Milvus migrans*). Journal of Animal and Veterinary Advances, 9(19): 2482-2484. Available at: <https://medwelljournals.com/abstract/?doi=javaa.2010.2482.2484>
- Vickaryous MK and Hall BK (2010). Comparative development of the crocodylian interclavicle and avian furcula, with comments on the homology of dermal elements in the pectoral apparatus. Journal of Experimental Zoology Part B Molecular and Developmental Evolution, 314: 196-207. DOI: <https://www.doi.org/10.1002/jez.b.21326>
- Viscosi V and Cardini A (2012). Leaf morphology, taxonomy and geometric morphometrics: A simplified protocol for beginners. PloS one, 6(10): e25630. DOI: <https://www.doi.org/10.1371/annotation/bc347abe-8d03-4553-8754-83f41a9d51ae>
- Zelditch ML, Swiderski DL, Sheets HD, and Fink WL (2012). Geometric morphometrics for biologists: A primer, 2<sup>nd</sup> Edition. Elsevier Academic Press., San Diego, USA, pp. 1-14. DOI: <https://www.doi.org/10.1016/B978-0-12-386903-6.00001-0>

**Publisher's note:** Scienceline Publication Ltd. remains neutral with regard to jurisdictional claims in published maps and institutional affiliations.



**Open Access:** This article is licensed under a Creative Commons Attribution 4.0 International License, which permits use, sharing, adaptation, distribution and reproduction in any medium or format, as long as you give appropriate credit to the original author(s) and the source, provide a link to the Creative Commons licence, and indicate if changes were made. The images or other third party material in this article are included in the article's Creative Commons licence, unless indicated otherwise in a credit line to the material. If material is not included in the article's Creative Commons licence and your intended use is not permitted by statutory regulation or exceeds the permitted use, you will need to obtain permission directly from the copyright holder. To view a copy of this licence, visit <https://creativecommons.org/licenses/by/4.0/>.

© The Author(s) 2026